

A Diffuse White Matter Ischemic Lesion Appearing 7 Years after Stereotactic Radiosurgery for Cerebral Arteriovenous Malformations: Case Report

Masaaki Yamamoto, M.D., Sadahiko Ban, M.D.,
Mitsunobu Ide, M.D., Minoru Jimbo, M.D.

Departments of Neurosurgery, Tokyo Women's Medical College Dai-ni Hospital (MY, MI, MJ), Tokyo, Japan, and Kobe City Central Hospital (SB), Kobe, Japan

OBJECTIVE AND IMPORTANCE: Little information is available about radiation-induced complications occurring more than 5 years after radiosurgical treatment for arteriovenous malformations.

CLINICAL PRESENTATION: We present a patient with arteriovenous malformations who experienced hemimotor weakness caused by a diffuse white matter necrotic lesion developing 7 years after gamma knife radiosurgery. The original nidus had been too large (24.1 cm³) to be totally covered and irradiated with a peripheral dose of 20 to 25 Gy. Therefore, the lower half of the nidus, which was adjacent to the major feeding artery, had been partially covered with a 30% isodose volume using two target points with an 18-mm collimator. A central dose of 70 Gy was used to obtain 21 Gy at the periphery. Complete nidus obliteration was angiographically confirmed 38 months after radiosurgery. After a 6-year uncomplicated period, this patient experienced a convulsive seizure and then mild right hemiparesis.

INTERVENTION: Computed tomography demonstrated a diffuse hypodense area in the left white matter, which had not been revealed by the previous examination. With steroid treatment, this patient achieved clinical improvement, although there was no significant improvement in the computed tomography-demonstrated white matter lesion.

CONCLUSION: Although the evaluation of this patient may not be sufficient and further examinations may be necessary, we tentatively conclude that the computed tomography-demonstrated hypodense lesion in this patient is a radiation-related necrotic lesion. Long-term follow-up is crucial, even after the "treatment goal" has been achieved. (*Neurosurgery* 41:1405-1409, 1997)

Key words: Arteriovenous malformations, Delayed complication, Gamma knife, Radiation necrosis, Radiosurgery

In a previous report (24), we described, for the first time, postradiosurgical complications occurring more than 5 years after irradiation for cerebral arteriovenous malformations (AVMs). Herein,

we present another patient with AVMs who experienced hemimotor weakness caused by a diffuse white matter ischemic lesion developing 7 years after gamma knife radiosurgery.

CASE DESCRIPTION

After his previous refusal to undergo surgical resection, this 28-year-old man, in whom clipping of the feeding artery had been unsuccessful, underwent gamma knife radiosurgery for ruptured left parietal lobe AVMs at the Karolinska Hospital on December 14, 1988 (Fig. 1). At the time of treatment, he had no neurological deficits. The nidus was too large (24.1 cm³, as calculated by multiplying the three diameters, 4.3, 3.6, and 3.0, by 0.52, as reported by Pasqualin et al. [15]) to be totally covered and irradiated with a peripheral dose of 20 to 25 Gy, considered at that time to be the optimal dose. Therefore, the lower half of the nidus, which was adjacent to the major feeding artery, was partially covered with a 30% isodose volume using two target points with an 18-mm collimator (Fig. 2). A central dose of 70 Gy was used to obtain 21 Gy at the periphery; the real volume included within the 30% (21.0 Gy) isodose gradient was estimated to be 12.6 cm³ on the basis of the dose-volume histogram obtained using a KULA system (Elekta Instrument AB, Stockholm, Sweden) at the time of treatment. On the day after radiosurgery, two generalized convulsive seizures occurred. However, there were neither subsequent changes in seizure frequency, subsequent bleeding, nor radiation-related complications during the 6 years after gamma knife radiosurgery. Complete obliteration was angiographically confirmed 38 months after radiosurgery (Fig. 3).

This patient presented to our facility with mild right hemiparesis, which had developed after a convulsive seizure in mid-December of 1995. Computed tomography (CT) demonstrated a diffuse hypodense area in the left white matter, which had not been revealed by the previous examination (Fig. 4). With steroid treatment, the patient showed clinical improvement within 2 months, despite the lack of any significant improvement in the white matter lesion revealed by CT. The patient was in good condition until July 4, 1996, when he experienced another convulsive seizure. The findings of precontrast-enhanced CT were

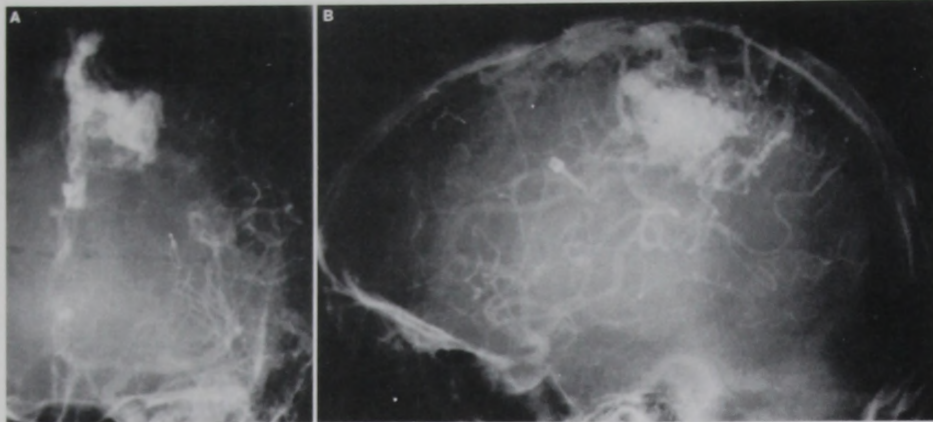


FIGURE 1. Anteroposterior (A) and lateral (B) views of angiograms obtained before radiosurgery.

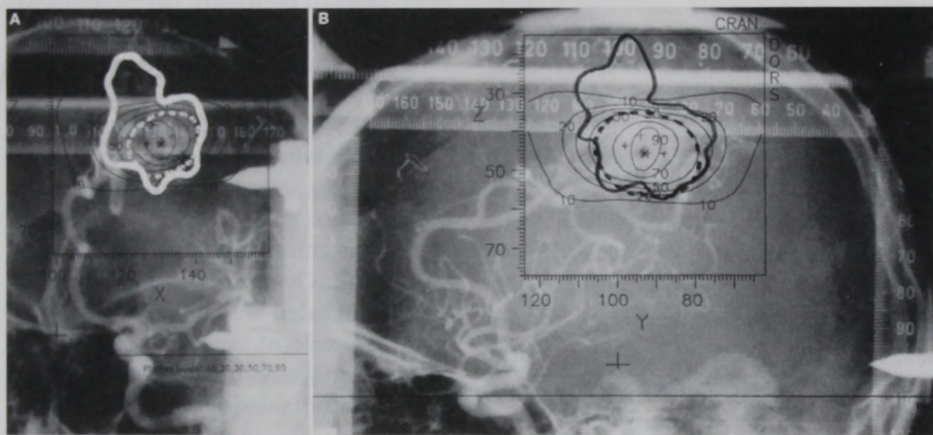


FIGURE 2. Anteroposterior (A) and lateral (B) views of stereotactic angiograms obtained at the time of radiosurgery. The *thick lines* (white in the anteroposterior view and black in the lateral view) show the nidus configuration. The *dotted lines* (white in the anteroposterior view and black in the lateral view) show the essential part of the nidus to be included within a target volume. The lines were drawn by a neuroradiologist. The isodose gradient is superimposed 90, 70, 50, 30, 20, and 10% from the center.

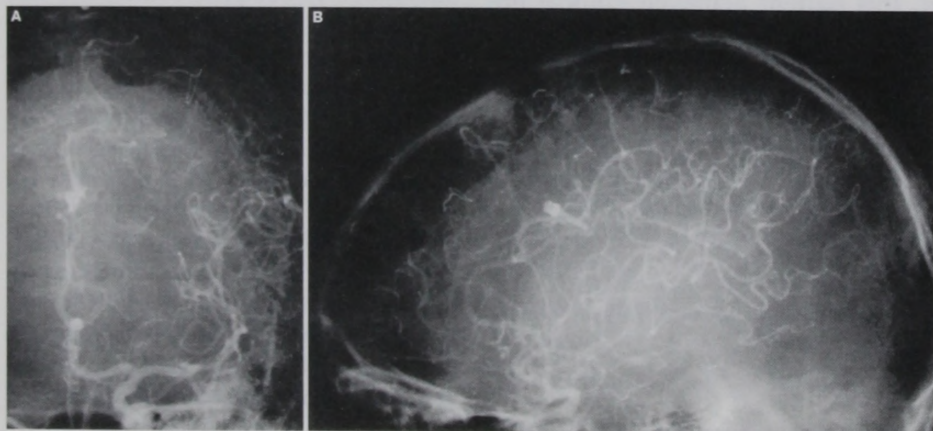


FIGURE 3. Anteroposterior (A) and lateral (B) views of angiograms obtained 38 months after radiosurgery. Complete nidus obliteration was angiographically confirmed, despite the upper part of the AVMs not having been included within the target volume.

unchanged, and postcontrast-enhanced CT demonstrated only a slightly enhanced area within a part of the treated nidus (Fig. 4C); this type of abnormal enhancement is usually observable for many years after angiographically confirmed obliteration of AVMs, as we reported previously (26). Single photon emission computed tomography using ^{99m}Tc -ethyl cysteinate dimer showed a hypoperfused area in the left parietal region, which was surrounded by a slightly hyperperfused area (Fig. 5). Postoperatively, mild right hemiparesis persisted and was still persisting as of the end of August, 1996.

DISCUSSION

Delayed radiation-induced complications after radiosurgical treatment for AVMs, rates of which reportedly range from 3.2 to 12.5%, have been described by all investigators using gamma knife systems (1-3, 6, 7, 13, 17), or linear accelerator systems (4, 5, 10, 18). The majority of such complications occurred by the third postradiosurgical year. Previously there were no reports of series of AVMs in which delayed radiation-induced complications occurring more than 5 years after irradiation were described. However, as we recently reported (24) in our series of 38 patients with AVMs who have been followed for more than 5 years after gamma knife radiosurgery, we experienced two patients (5.0%) with symptomatic complications that developed 5.5 and 7 years respectively, after irradiation. Herein another patient with a late complication, which developed 7 years after irradiation, is presented.

Based on the neuroimaging findings for this patient, the CT-demonstrated hypodense area, which although diffuse was limited to the white matter, was considered to be a radiation-induced necrotic lesion. The mechanism of this type of complication has yet to be fully clarified. We have elsewhere reported an autopsy case with AVMs treated by gamma knife radiosurgery, in which postmortem studies after death that was unrelated to the AVMs were conducted after angiography performed at 2 years

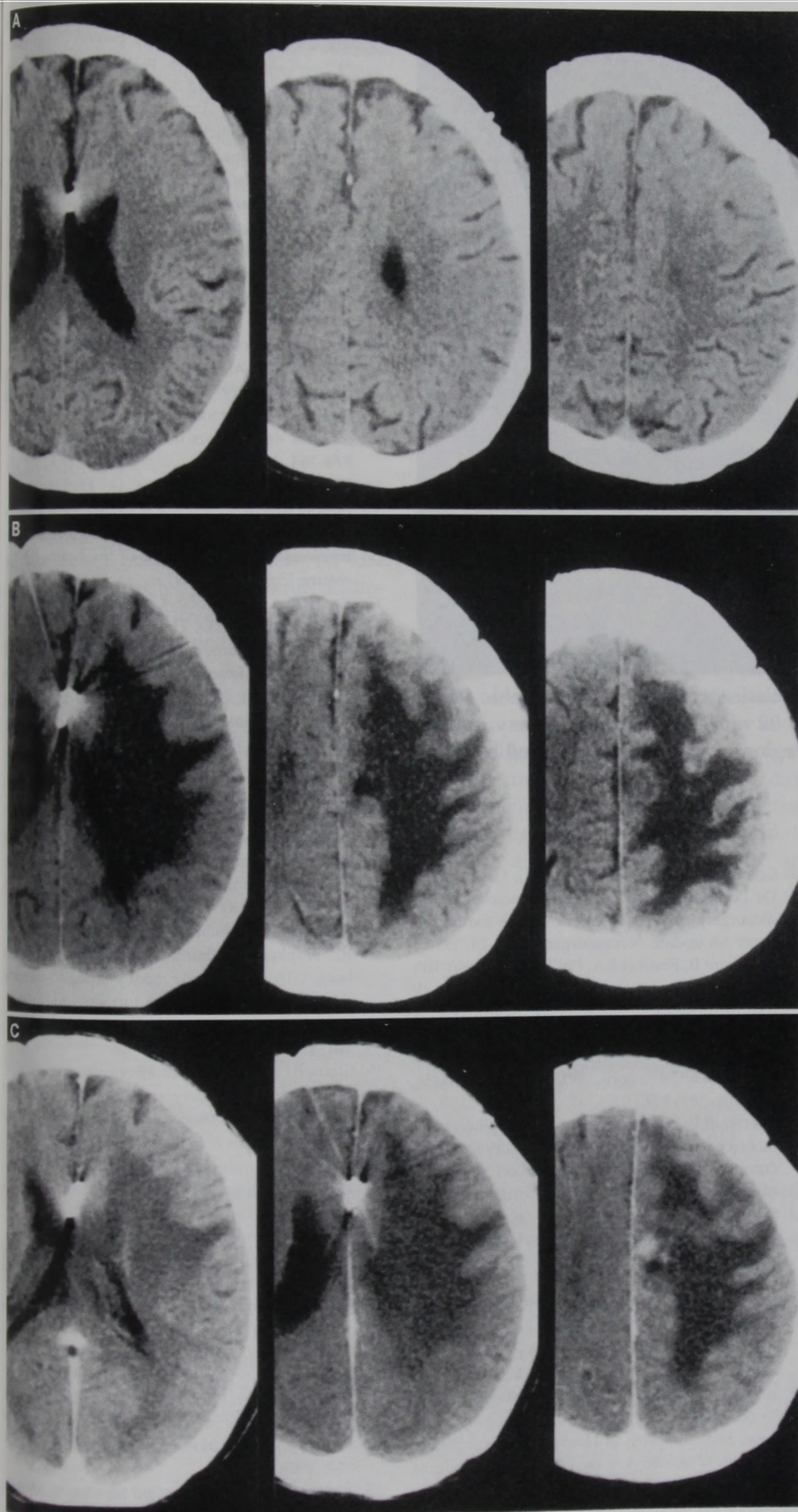


FIGURE 4. Sequential computed tomographic scans obtained 38 (A), 91 (B), and 92 (C) months after radiosurgery; with (C) and without (A and B) contrast enhancement.

demonstrated complete nidus obliteration (25). This study disclosed that intimal hypertrophy can occur in a normal pial artery that is unrelated to AVMs because of irradiation of 10 Gy or more and that more remarkable intimal hypertrophy with fragmentation of the elastic laminae, or even complete occlusion, can occur in these arteries with 25 Gy. In addition, we have elsewhere reported the case of a patient with AVMs in whom severe, although asymptomatic, stenosis of the middle cerebral artery trunk had been caused by relatively low-dose irradiation 3 years after gamma knife radiosurgery (23). For the present patient, the irradiation dose to the affected artery was retrospectively estimated to be 10 Gy or less. We think that the changes had progressed in small arteries of the white matter for many years after irradiation and that the diffuse white matter hypodensity eventually developed.

Although, because of the partial irradiation coverage in the present patient, the dose-volume analysis may be inadequate, the 21.0 Gy-12.6 cm³ point used exceeds the established 3% risk of permanent symptomatic brain injury reported by Kondziolka et al. (11). Similarly, the dose-diameter point (21.0 Gy-3.5 cm, which is the maximum diameter of a 30% isodose gradient) is far above the 1% risk level for radionecrosis reported by Friedman and Bova (6). The irradiation dose of 70 Gy selected at the target center is considered to be high; today, the central dose used for patients with AVMs does not exceed 50 to 55 Gy in the majority of centers using gamma knives or linear accelerator systems (3, 6, 7, 13, 14, 16, 17, 22). Furthermore, when this patient underwent gamma knife radiosurgery, only angiograms were used for dose planning. In recent years, however, three-dimensional imaging examinations have been widely used for radiosurgical treatment of AVMs. Therefore, it is now expected that radiosurgery, even for patients with relatively large AVMs, is relatively safe (22). Long-term follow-up, however, is crucial, even after the "treatment goal," as described by Lindquist and Steiner (12), has been achieved.

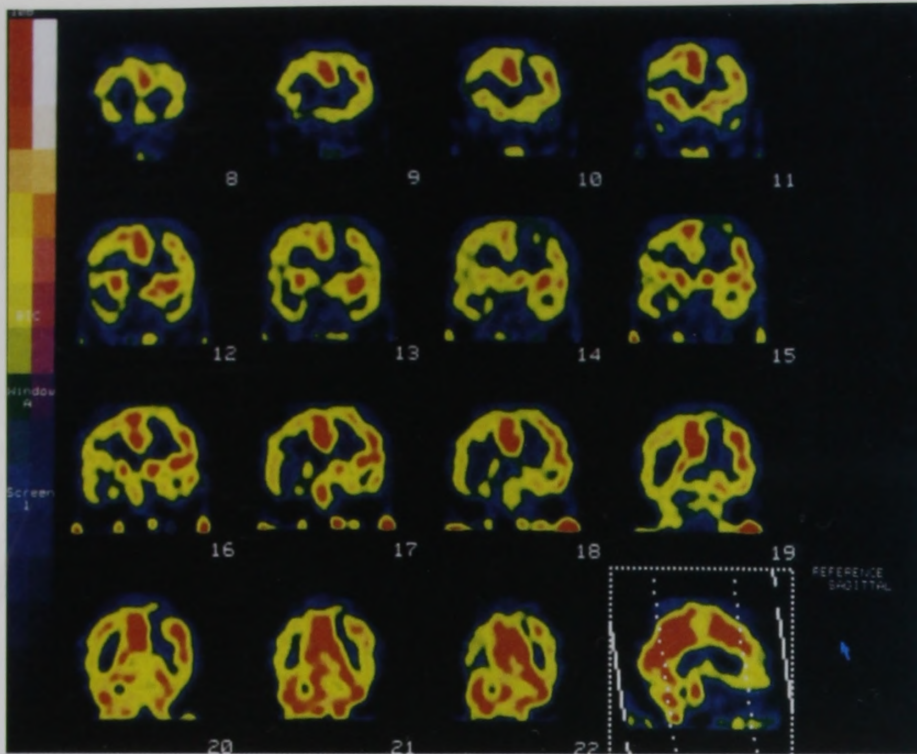


FIGURE 5. Coronal views of single photon emission computed tomographic scans using ^{99m}Tc -ethyl cysteinate dimer obtained 92 months after radiosurgery, showing a hypoperfused area in the left parietal region, which was surrounded by a slightly hyperperfused area.

ACKNOWLEDGMENTS

We thank Bengt Karlsson, M.D., Ph.D., Department of Neurosurgery, Karolinska Hospital, Stockholm, for gamma knife treatment and Bierta E. Barfod, M.D., University of Washington School of Medicine, for assistance in the preparation of the manuscript.

Received, September 17, 1996.

Accepted, July 16, 1997.

Reprint requests: Masaaki Yamamoto, M.D., Department of Neurosurgery, Tokyo Women's Medical College Dai-ni Hospital, 2-1-10 Nishiogu, Arakawa-ku, Tokyo, 116 Japan.

REFERENCES

- Betti OO, Munari C, Rosler R: Stereotactic radiosurgery with the linear accelerator: Treatment of arteriovenous malformations. *Neurosurgery* 24:311-321, 1989.
- Colombo F, Benedetti A, Pozza F, Marchetti C, Chiarego G: Linear accelerator radiosurgery of cerebral arteriovenous malformations. *Neurosurgery* 24:833-840, 1989.

- Colombo F, Pozza F, Chiarego G, Casentini L, De Luca G, Francescon P: Linear accelerator radiosurgery of cerebral arteriovenous malformations: An update. *Neurosurgery* 34:14-21, 1994.
- Fabrikant JI, Frankel KA, Phillips MH, Levy RP: Stereotactic heavy charged-particle Bragg peak radiosurgery for intracranial arteriovenous malformations, in Edwards MSB, Hoffman HJ (eds): *Cerebral Vascular Diseases in Children and Adolescents*. Baltimore, Williams & Wilkins, 1989, pp 389-409.
- Fabrikant JI, Lyman JT, Hosobuchi Y: Stereotactic heavy-ion Bragg peak radiosurgery for intracranial vascular disorders: Method for treatment of deep arteriovenous malformations. *Br J Radiol* 57:479-490, 1984.
- Friedman WA, Bova FJ: Linear accelerator radiosurgery for arteriovenous malformations. *J Neurosurg* 77:832-841, 1992.
- Friedman WA, Bova FJ, Mendenhall WM: Linear accelerator radiosurgery for arteriovenous malformations: The relationship of size to outcome. *J Neurosurg* 82:180-189, 1995.
- Jimbo M, Kitamura K, Steiner L: Radiotherapy to cerebral arteriovenous malformation [in Japanese, English abstr], in Hirakawa K (ed): *Neurosurgeons (Proceedings of the 7th Annual Meeting of the Japanese Congress of Neurological Surgeons)*. Tokyo, Scimed Publications, 1987, vol 6, pp 254-257.
- Kawamoto S: Radiosurgery of arteriovenous malformations [in Japanese]. *No Shinkei Geka* 22:403-420, 1994.
- Kjellberg RN, Hanamura T, Davis KR, Lyons SL, Adams RD: Bragg-peak proton-beam therapy for arteriovenous malformations of the brain. *N Engl J Med* 309:269-274, 1983.
- Kondziolka D, Lunsford LD, Coffey RJ, Bissonette DJ, Flickinger JC: Stereotactic radiosurgery of angiographically occult vascular malformations: Indications and preliminary experience. *Neurosurgery* 27:892-900, 1990.
- Lindquist C, Steiner L: Stereotactic radiosurgical treatment of arteriovenous malformations, in Lunsford LD (ed): *Modern Stereotactic Neurosurgery*. Boston, Martinus Nijhoff, 1987, pp 491-505.
- Loeffler JS, Rossitch E Jr, Siddon R, Moore Rockoff MA, Alexander E III: Role of stereotactic radiosurgery with a linear accelerator in the treatment of intracranial arteriovenous malformations and tumors in children. *Pediatrics* 5:774-784, 1990.
- Lunsford LD, Kondziolka D, Flickinger JC, Bissonette DJ, Jungreis CA, Maitz AH, Horn JA, Coffey RJ: Stereotactic radiosurgery for arteriovenous malformations of the brain. *J Neurosurg* 75:512-524, 1991.
- Pasqualin A, Barone G, Cioffi F, Rostaletti Sciencia R, Pian RD: The relevance of anatomic and hemodynamic factors to a classification of cerebral arteriovenous malformations. *Neurosurgery* 28:370-379, 1991.
- Pollock BE, Lunsford LD, Kondziolka D, Maitz AH, Flickinger JC: Patient outcomes after stereotactic radiosurgery for "operable" arteriovenous malformations. *Neurosurgery* 35:1-8, 1994.
- Souhami L, Olivier A, Podgorsak EB, Pike GB: Radiosurgery of cerebral arteriovenous malformations with the dynamic stereotactic irradiation. *Int J Radiat Oncol Biol Phys* 19:775-782, 1990.
- Steinberg GK, Fabrikant JI, Marks MP, Lunsford LD, Frankel KA, Phillips MH, Shuer LM, Silberberg GD: Stereotactic heavy-charged-particle Bragg-peak radiation for intracranial arteriovenous malformations. *N Engl J Med* 323:101, 1990.
- Steiner L: Treatment of arteriovenous malformation by radiosurgery, in Wilson CB, Stein L (eds): *Intracranial Arteriovenous Malformations*. Baltimore, Williams & Wilkins, 1984, pp 295-313.
- Steiner L, Lindquist C, Adler JR, Torner Alves W, Steiner M: Clinical outcome of radiosurgery for cerebral arteriovenous malformations. *J Neurosurg* 77:1-8, 1992.
- Steiner L, Lindquist C, Steiner M: Radiosurgery, in Symon L (ed): *Advances and Technical Standards in Neurosurgery*. Vienna, Springer-Verlag, 1992, vol 19, pp 19-102.
- Yamamoto Y, Coffey RJ, Nichols DA, Shewar EG: Interim report on the radiosurgical treatment of cerebral arteriovenous malformations: The influence of size, dose, time and technical factors on obliteration rate. *J Neurosurg* 83:832-837, 1995.
- Yamamoto M, Ide M, Jimbo M, Ono Y: Middle cerebral artery stenosis caused by relatively low dose irradiation with stereotactic radiosurgery for cerebral arteriovenous malformations: Case report. *Neurosurgery* 41:474-478, 1997.