

K. Ohno
E. Isotani
K. Hirakawa

MELAS presenting as migraine complicated by stroke: case report

Received: 23 September 1996
Accepted: 19 February 1997

K. Ohno (✉) · E. Isotani · K. Hirakawa
Department of Neurosurgery,
Tokyo Medical and Dental University,
Yushima 1-5-45, Bunkyo-ku, Tokyo 113,
Japan
Tel. + 0081 03-5803-5266;
fax + 0081 03-5803-0140

Abstract A case of MELAS (mitochondrial encephalomyopathy, lactic acidosis, and stroke-like episodes) which presented as migraine complicated by stroke is reported. Strokes associated with migraine have often been reported, but the mechanism remains unclear and may include a variety of pathologies. MELAS also presents with migrainous headache, vomiting, and stroke-like symptoms. Magnetic resonance

imaging demonstrates characteristic findings. MELAS should be considered in the differential diagnosis of infarct-like lesions with migrainous headaches in young adults, especially if the symptoms fluctuate and are accompanied by a homonymous hemianopia.

Key words MELAS · Migraine · Stroke · Magnetic resonance imaging

Introduction

Mitochondrial encephalomyopathy, lactic acidosis, and stroke-like episodes (MELAS) is a distinct syndrome characterised by recurrent attacks of prolonged migrainous headache and repeated vomiting, epileptic seizures with bouts of status epilepticus, and migrating stroke-like episodes with cortical blindness or deafness [1, 2]. This syndrome is now a clinical entity supported by laboratory examinations, muscle biopsy, and neuro-radiological findings. The recurrent attacks of severe pulsatile headaches with vomiting seen in patients with MELAS resemble those of migraine. On the other hand, some patients with migraine have been reported to suffer ischaemic stroke as a sequel, with motor or sensory deficits, speech disturbances, or much more commonly, visual field defects [3]; this clinical entity has recently been named “migrainous stroke” [4]. Despite much speculation, little is known about the pathophysiology of migraine-associated stroke [3].

We report a patient who was first suspected of manifesting a migraine-associated stroke but later was diagnosed as having MELAS, and discuss the differential diagnostic problem presented by these two syndromes.

Case report

A 21-year-old man suddenly developed severe pulsatile headache with frequent vomiting. Two days later, he presented with motor and sensory dysphasia, alexia, and mild right hemiparesis. No clinical improvement occurred, and he was referred to us 6 days later. Examination demonstrated motor and sensory dysphasia, mild right hemiparesis and bilateral deafness. The patient's past history was unremarkable. His mother had bilateral hypoacusis. Haematological examination demonstrated normal leukocyte and platelet counts, prothrombin time, APTT, antithrombin III and clotting time. Liver and renal function was normal. Echocardiography showed mitral valve prolapse with trivial mitral stenosis; the electrocardiogram was within normal limits.

CT revealed a low-density area in the left temporal lobe and bilateral basal ganglia calcification. Three days later, he again developed a severe pulsatile headache with vomiting, followed by a generalised convulsion. After he recovered consciousness, a right homonymous hemianopia was evident. Four-vessel cerebral angiography 3 days after the second attack revealed no abnormalities, but CT demonstrated a low-density area extending from the left temporal lobe to the occipital lobe (Fig. 1a). Xenon-enhanced CT 5 days after the attack showed no decrease in regional cerebral blood flow in the lesion. MRI revealed decreased signal intensity on T1-weighted images and increased gyral signal intensity on T2-weighted images in the left temporo-occipital region (Fig. 1b,c). The symptoms gradually abated, including the visual field defect.

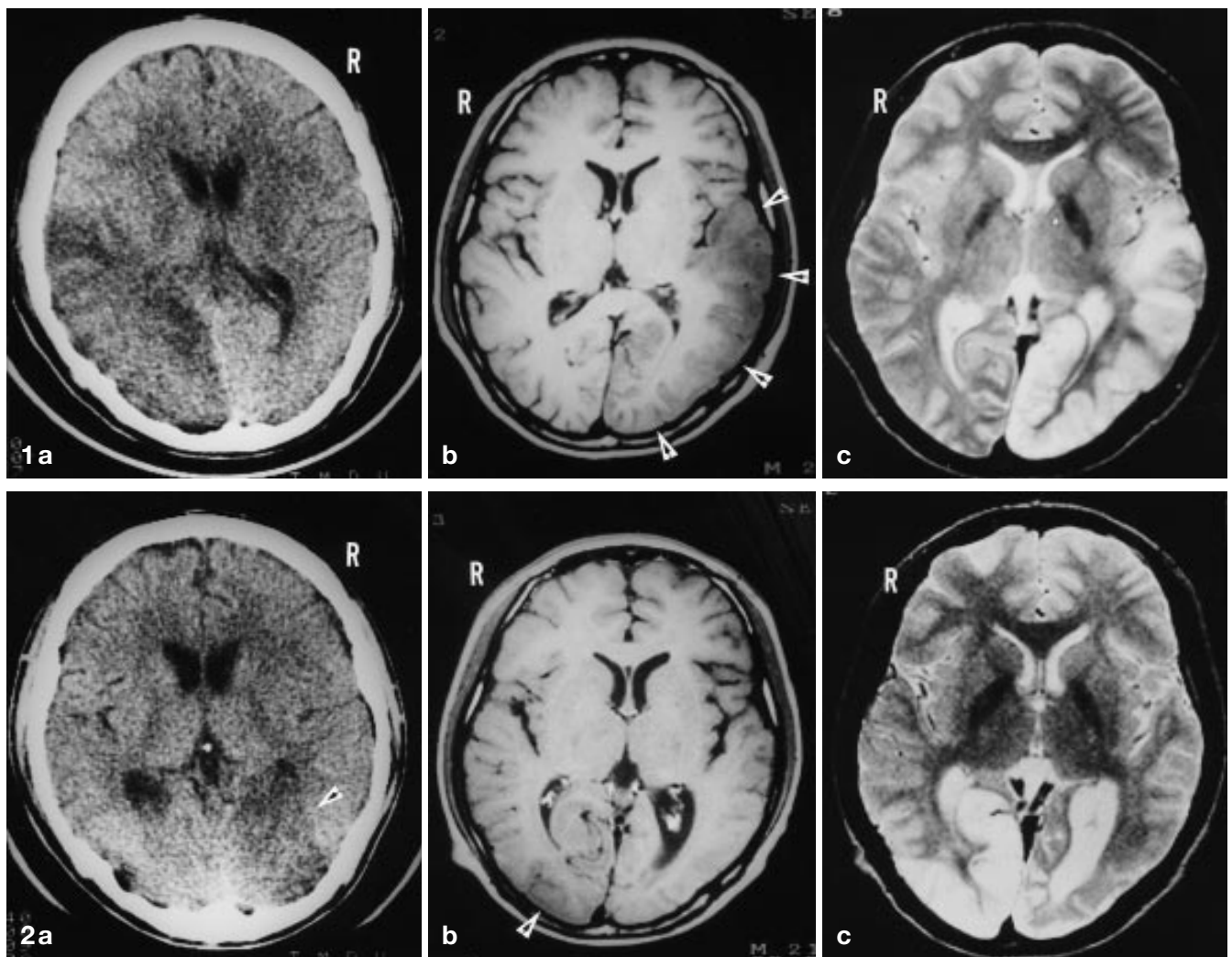


Fig. 1 **a** CT 4 days after the second attack, showing low density in the left temporo-occipital region. **b** T1-weighted MRI, showing an area with slightly low signal intensity (*arrows*) in the left temporal and occipital lobes. **c** T2-weighted image demonstrating cortical high signal in the same area and low signal indicating calcification in the basal ganglia

Fig. 2 **a** CT 6 days after the third attack, showing low density (*arrow*) in the right occipital lobe. **b** T1-weighted image, showing slightly low signal (*arrow*) in the occipital lobe. **c** T2-weighted image, demonstrating cortical high signal in the same area and near-resolution of high signal in the left occipital lobe

At this stage the differential diagnosis included cardiac thromboembolism and migraine complicated by stroke. Because the echocardiogram showed no thrombus in the left atrium and neurological signs were accompanied by severe headache, a thromboembolic origin seemed unlikely, so the patient was suspected of having a migraine-associated stroke. Anticonvulsant and antiplatelet therapy was initiated. Dihydroergotamine mesylate was given for the migrainous headache. The symptoms resolved, and MRI 2 months later showed resolution of the lesion.

Approximately 1 week after the MRI examination, the patient noted scintillation scotomata, followed a few days later by a severe pulsatile headache with vomiting and a left homonymous hemianopia in spite of continuing medication. CT demonstrated a low-density area in the right occipital lobe (Fig. 2a), and MRI a corresponding area of decreased signal intensity on T1-weighted images and increased cortical signal intensity on T2-weighted images (Fig. 2b,c). The visual field defect gradually waned. The MRI findings seemed inconsistent with cerebral infarction, and the patient was diagnosed as having MELAS, based on the presence of ragged red fibres on muscle biopsy. CT 3 weeks later showed resolution of the low-density area. The patient's mother was also diagnosed as having MELAS, on laboratory examinations, clinical signs, and muscle biopsy.

Discussion

Although uncommon, the syndrome of neurological deficits associated with migraine is more frequent in adolescents and young adults. Specific clinical syndromes include hemiplegic migraine, alternating hemi-

plegia of childhood, retinal migraine, ophthalmoplegic migraine and vertebrobasilar migraine. Migraine complicated by stroke has been reported since the last century. Proposed mechanisms for migraine-associated stroke include vasospasm, coagulopathies, arterial dissection, embolism, migrainous arteriopathy and spreading depression [4]. Our patient's symptoms and signs were consistent with migraine. Therefore, we suspected that he had migraine followed by stroke, and initially interpreted the CT and MRI as indicating a cerebral infarct; however, the xenon-enhanced CT was inconsistent with cerebral infarction, and the lesions did not correspond to major vascular territories; angiography was unhelpful.

Two distinct clinical entities, CADASIL (cerebral autosomal dominant arteriopathy with subcortical infarcts and leukoencephalopathy) and MELAS, which present as attacks of migrainous headache followed by strokes, have recently been recognised [1, 5, 6]. CADASIL is an inherited arterial disease of the brain mapped to chromosome 19q12 [5, 6]. CT and MRI show characteristic findings such as small, deep subcortical infarcts and leukoencephalopathy in patients with CADASIL who develop symptoms in mid-adult life [6]. These characteristic neuroradiological findings are different from those in our patient.

High signal in the cerebral convolutions, with less subcortical involvement, on T2-weighted images was characteristic of MRI in our patient. Furthermore, the lesions occurred repeatedly at different times and regions. The areas that gave abnormal signal returned to apparently normal signal intensity. These findings are similar to those of a case reported by Rosen et al. [7], who stated that the posterior temporal and occipital predominance of infarct which show a "migratory" nature is typical of MELAS. A study by Ooiwa et al. [8] showed that xenon-enhanced CT revealed vasodilatation without any reduction in regional cerebral blood flow (CBF) in the affected cerebral cortex on MRI in patients with MELAS. It was concluded that the *stroke-like* episodes associated with MELAS are different in origin from ischaemic stroke. It was suggested that the

vasodilation seen on xenon-enhanced CT was caused by localised metabolic acidosis in the affected cerebral cortex. The xenon-enhanced CT in our patient also showed no decrease in regional CBF. On the other hand, Ohama et al. [9] studied the cerebral blood vessels of two patients with MELAS who had come to autopsy, and stated that cerebral lesions are not due to primary mitochondrial dysfunction involving the brain itself but to mitochondrial angiopathy, of the pial arterioles and small arteries of the brain. Vascular changes at the level of pial and intracerebral arterioles may cause reversible circulatory disturbance in the cerebral cortex, and also account for the lack of correspondence of the lesions to major vascular territories, despite the development of stroke-like episodes. Thus, the pathogenesis of the cerebral lesions seen on MRI remains to be elucidated.

The pathophysiology of MELAS may provide new insight into the mechanism of vertebrobasilar migraine, particularly since the infarct-like lesions in MELAS occur predominantly in the occipital region, presenting with homonymous hemianopia in more than 50 % of patients [10]. There is a strong resemblance in familial occurrence and age of onset between mitochondrial encephalomyopathies and migraine. Montagna et al. [11] suggested that impaired mitochondrial energy metabolism may underlie migraine. Although it is unlikely that mitochondrial abnormalities explain all the mechanisms of migraine, impaired mitochondrial energy metabolism may be responsible in some patients with migraine-associated stroke or migrainous stroke. Specifically, patients with MELAS may be diagnosed as having a migraine-associated stroke in everyday practice, because the symptoms and signs of MELAS are similar to those in migraine-associated stroke, including migrainous stroke. Migraine complicated by stroke may not be a simple clinical entity but include various pathological conditions. It has recently been suggested that the same mutant gene could be involved in the pathogenesis of familial hemiplegic migraine and CADASIL [12]. We suggest that a diagnosis of migraine-associated stroke should not be made until after MELAS has been ruled out.

References

1. Montagna P, Gallassi R, Medori R, Govoni E, Zeviani M, Di Mauro S, Luggaresi E, Andermann F (1988) MELAS syndrome: characteristic migrainous and epileptic features and maternal transmission. *Neurology* 38: 751–754
2. Nakagawa M, Osame M (1990) Clinical aspects of mitochondrial encephalomyopathy – abnormality of mitochondrial respiratory chain (in Japanese). *Brain Nerve (Tokyo)* 42: 719–733
3. Bousser MG, Baron JC, Chiras J (1985) Ischemic strokes and migraine. *Neuroradiology* 27: 583–587
4. Rothrock JF, Walicke P, Swenson MR, Lyden PD, Logan WR (1988) Migrainous stroke. *Arch Neurol* 45: 63–67
5. Bousser MG, Tournier-Lasserre E (1994) Summary of the proceedings of the First International Workshop on CADASIL. Paris, May 19–21, 1993. *Stroke* 25: 704–707
6. Verin M, Rolland Y, Landgraf F, Chabriat H, Bompais B, Michel A, Vahedi K, Martinet JP, Tournier-Lasserre E, Lemaitre MH, Edan G (1995) New phenotype of the cerebral autosomal dominant arteriopathy mapped to chromosome 19: migraine as the prominent clinical feature. *J Neurol Neurosurg Psychiatry* 59: 579–585

-
7. Rosen L, Phillips S, Enzmann D (1990) Magnetic resonance imaging in MELAS syndrome. *Neuroradiology* 32: 168–171
 8. Ooiwa Y, Uematsu Y, Terada T, Nakai K, Itakura T, Komai N, Moriwaki H (1993) Cerebral blood flow in mitochondrial myopathy, encephalopathy, lactic acidosis and strokelike episodes. *Stroke* 24: 304–309
 9. Ohama E, Ohara S, Ikuta F, Tanaka K, Nishizawa M, Miyatake T (1987) Mitochondrial angiopathy in cerebral blood vessels of mitochondrial encephalopathy. *Acta Neuropathol (Berl)* 74: 226–233
 10. Ciafaloni E, Ricci E, Shanske S, Moraes CT, Silvestri G, Hirano M, Simonetti S, Angelini C, Donati MA, Garcia C (1992) MELAS: clinical features, biochemistry, and molecular genetics. *Ann Neurol* 31: 391–398
 11. Montagna P, Sacquegna T, Martinelli P, Cortelli P, Bresolin N, Moggio M, Baldrati A, Riva R, Lugaesi E (1988) Mitochondrial abnormalities in migraine. Preliminary findings. *Headache* 28: 477–480
 12. Joutel A, Bousser MG, Biouesse V, Labauge P, Chabriat H, Nibbio A, Maciazek J, Meyer B, Bach MA, Weissenbach J, Lathrop GM, Tournier-Lasserre E (1993) A gene for familial hemiplegic migraine maps to chromosome 19, *Nat Genet* 5: 40–45