

# Oral manifestations and differential diagnosis of isolated hypoglossal nerve palsy: report of two cases

Susumu Omura, DDS, PhD,<sup>a</sup> Yuzuru Nakajima,<sup>b</sup> DDS, Sonou Kobayashi, DDS, PHD,<sup>b</sup> Shigeru Ono, MD, DDS, PhD,<sup>a</sup> and Kiyohide Fujita, MD, DDS, PhD,<sup>c</sup> Yokohama, Japan  
YOKOHAMA CITY UNIVERSITY

Isolated hypoglossal nerve palsy is rare, but occasionally it appears as the initial or solitary sign of an intracranial or extracranial space-occupying lesion, a head and neck injury, or a vascular abnormality of the internal carotid artery. Therefore it should be considered in differential diagnosis. We report two cases of isolated unilateral hypoglossal nerve palsy. In Case 1 the cause of the palsy appeared to be hypoglossal nerve neurilemmoma within the hypoglossal canal, whereas in Case 2 the cause could not be identified. Neither patient complained of any disability other than slight dysarthria. The tongue deviated toward the healthy side at rest and toward the affected side on protrusion. Hemiatrophy of the tongue with fatty displacement was demonstrated by means of T<sub>1</sub>-weighted magnetic resonance imaging. Dentists who might at times see patients with isolated hypoglossal nerve palsy should be aware of the significance of its oral manifestation, and they should be able to perform differential diagnosis of patients with the condition who appear for treatment. (*Oral Surg Oral Med Oral Pathol Oral Radiol Endod* 1997;84:635-40)

Isolated hypoglossal nerve palsy (IHNP) is extremely rare, because intramedullary lesions usually involve either adjacent cranial nerve nuclei or corticospinal, pyramidal, or spinothalamic tracts, and because extramedullary lesions usually involve other lower cranial nerves. However, IHNP occasionally appears as the initial sign, and sometimes as the solitary sign, of an intracranial or extracranial (or both intracranial and extracranial) space-occupying lesion, of a head and neck injury, or of a vascular abnormality.

Dentists rarely encounter patients with IHNP as their first clinicians, and they tend to know little about hypoglossal nerve palsy except that it manifests itself as deviation of the tongue toward the ipsilateral side on protrusion. IHNP involves minimal disability; for this reason, it is often overlooked until quite late, by which time patients may show signs of cerebellar or brainstem compression or other cranial nerve deficit.<sup>1,2</sup> We suspect that IHNP, although rare, is more prevalent than is commonly believed. For the sake of early diagnosis and timely referral of patients with IHNP to neurologists, dentists should be aware of the significance of the oral manifestations of the condition and be able to perform differential diagnosis. This article reports two cases of IHNP and discusses differential diagnosis of

the disease on the basis of the literature of the past decade.

## CASE REPORTS

### Case 1

A 72-year-old man was referred to our clinic by his primary physician for evaluation of lingual deviation toward the right side on protrusion. Relevant medical history included mild hypertension and diabetes mellitus, for which he was taking medication. The patient had no history of dysarthria or dysphagia, and he had not noticed the lingual deviation.

The results of the general physical examination of the patient were unremarkable. Intraoral examination revealed marked left-sided hemiatrophy of the tongue without fasciculation, inability of the patient to deviate the tongue toward the right inside of his mouth, deviation of the tongue toward the right side at rest (Fig. 1, A), and deviation toward the left side on protrusion (Fig. 1, B). The patient showed normal pharyngeal sensation and a brisk bilateral gag reflex. Cerebellar function was normal, and no symptoms and signs of brain stem compression or increased intracranial pressure were observed. Standard routine blood and cerebrospinal fluid examinations were normal. Plane radiographic examination of the skull revealed no abnormalities. According to coronal T<sub>1</sub>-weighted magnetic resonance imaging (MRI), left-sided hemiatrophy of the tongue was clearly shown by deviation of the median septum to the left side. The atrophied left half of the tongue showed high signal intensity, similar to that of subdermal fat tissue (Fig. 1, C). Computed tomography (CT) scans showed cortical bone erosion and widening of the left hypoglossal canal (Fig. 1, D), and MRI revealed a soft tissue mass within the hypoglossal canal. The signal of the lesion was similar to that of the right hypoglossal nerve on T<sub>1</sub>- and T<sub>2</sub>-weighted images (Fig. 1, E, F). Radiologic findings uniformly suggested a tumor originating in the hypoglossal nerve. The patient was clinically diagnosed with unilateral isolated hypoglossal nerve palsy, most likely

<sup>a</sup>Assistant Professor, Department of Oral and Maxillofacial Surgery, School of Medicine.

<sup>b</sup>Instructor, Department of Oral and Maxillofacial Surgery, School of Medicine.

<sup>c</sup>Professor, Department of Oral and Maxillofacial Surgery, School of Medicine.

Received for publication Apr. 23, 1997; accepted for publication July 10, 1997.

Copyright © 1997 by Mosby-Year Book, Inc.

1079-2104/97/\$5.00 + 0 7/13/85919

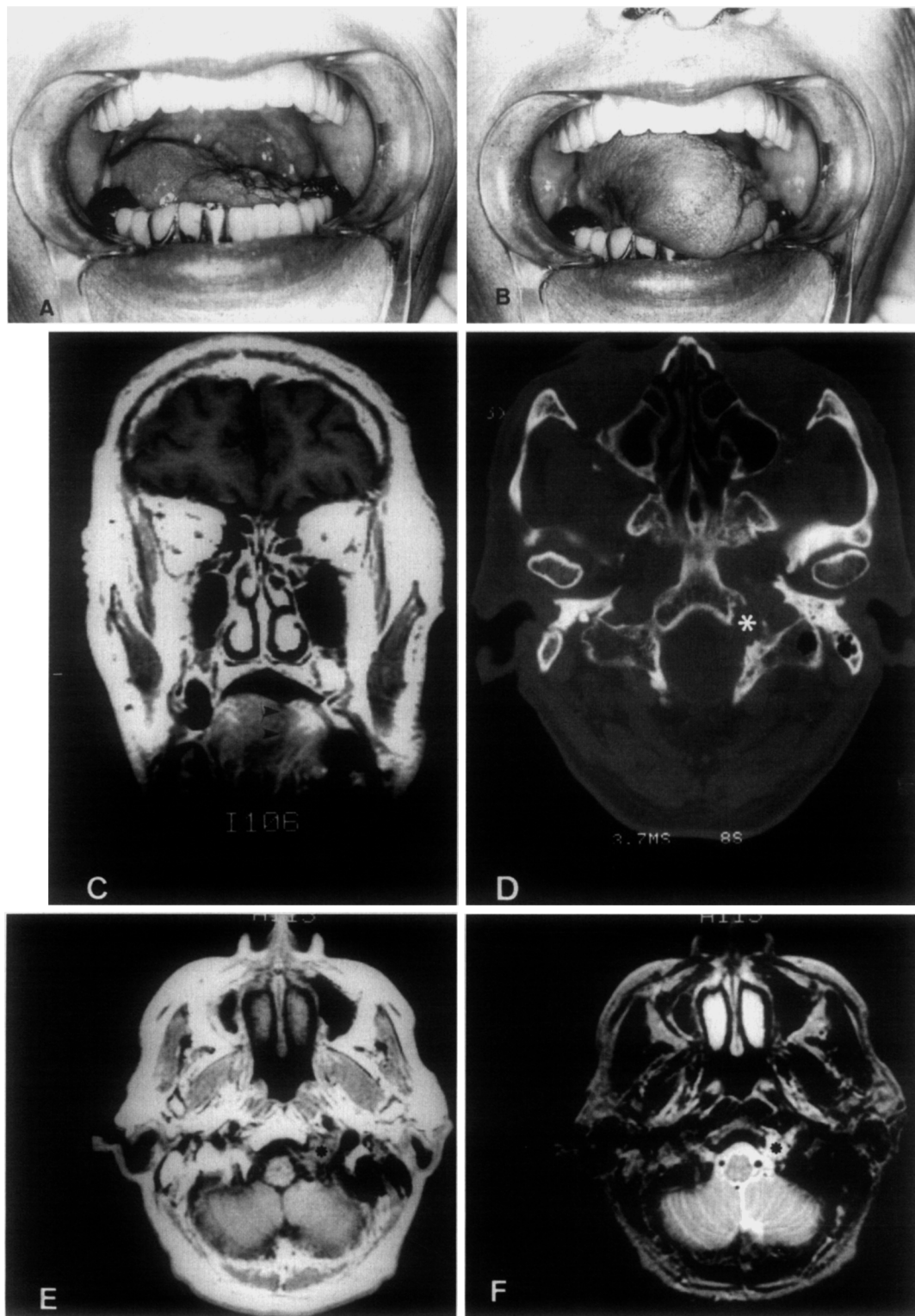

Fig. 1. **A**, Tongue deviates toward right side at rest. Left-sided hemiatrophy is evident. **B**, Tongue deviates toward left side on protrusion. **C**, Coronal T<sub>1</sub>-weighted MR image shows left-sided hemiatrophy and shift of septum to left side (*arrowheads*). Dorsal part of atrophied tongue shows a high signal intensity, similar to that of subdermal fat tissue. **D**, Axial CT scan shows cortical bone erosion and widening of left hypoglossal canal (*asterisk*). **E**, Axial T<sub>1</sub>-weighted MR image shows lesion in left hypoglossal canal (*asterisk*). **F**, Axial T<sub>2</sub>-weighted MR image shows lesion in left hypoglossal canal (*asterisk*).

resulting from hypoglossal nerve neurilemmoma. Because of the patient's advanced age and because of the projected difficulty of safe separation of the lesion from the hypoglossal nerve, a surgical approach was not indicated. The patient's condition was followed over a 3-year period, and no other remaining cranial nerve deficit was observed.

### Case 2

A 60-year-old woman complaining of an unpleasant sensation in her tongue visited our clinic. Her past medical history was not relevant. The patient had a 3-month history of slurred speech. Neurologic examination revealed slight dysarthria, atrophy, and occasional fasciculation of the right side of the tongue. The patient's tongue deviated toward the left side at rest and toward the right side on protrusion (Fig. 2, A, B). Gag reflex, palatal movement, and sensation were normal. Axial T<sub>1</sub>-weighted MRI showed high signal intensity of the right half of the tongue margin, similar to that of the subdermal fat tissue (Fig. 2, C). CT scans and MRIs of the skull revealed no significant findings. A bone scan showed no abnormal uptake, and internal carotid artery (ICA) angiography was normal. The patient was neurologically diagnosed with isolated hypoglossal nerve palsy of unknown origin. The patient was referred to a neurologist but declined further invasive examination. Over a 2-year period of observation, no improvement in the patient's speech has been observed. However, other neurologic conditions have remained stable.

### DISCUSSION

Isolated hypoglossal nerve palsy is rare. During the past decade, 26 cases of IHNP have been reported in the English-language literature.<sup>3-25</sup> However, IHNP may be more prevalent than commonly thought. When gradually progressive IHNP appears as the first sign of an intracranial or extracranial space-occupying lesion, the patient may not become aware of the nerve deficit and may be without complaint until adjacent cranial nerves become involved or long tract signs become evident.<sup>1,2</sup> In some cases, IHNP may be overlooked at the time of clinical examination because the examining clinician has little knowledge of the clinical presentation, dysfunction, and radiologic findings of this condition, all of which change in a time-dependent fashion after onset. Differential diagnosis and diagnostic procedures of lesions presenting IHNP have not been well documented.

According to the 26 previously reported cases of IHNP, the causes of the condition can be classified into four major groups: tumors or cysts (seven cases),<sup>3-9</sup> head and neck injuries (six cases),<sup>10-15</sup> abnormalities of the ICA (two cases),<sup>16-17</sup> and tuberculosis and rheumatoid arthritis of the cervical spine (six cases).<sup>18-20</sup> Each of these potential causes should be considered in the differential diagnosis. One of the other five cases involved an extremely rare pathologic condition,<sup>21</sup> and there were four cases of unknown origin.<sup>22-25</sup>

The presence of a tumor or cyst is the most common cause of IHNP. Metastasis to the base of the skull<sup>3,4</sup> or to the neck,<sup>5</sup> chondroid chordoma in the hypoglossal canal,<sup>6</sup> arachnoid cyst in the posterior fossa,<sup>7</sup> adenoid cystic carcinoma of the tongue,<sup>8</sup> and hypoglossal neurilemmoma of the neck<sup>9</sup> have all been reported as causes. In Case 1 CT scans and MRIs of the head and neck clearly showed a lesion in the hypoglossal canal. The lesion was clinically diagnosed as hypoglossal nerve neurilemmoma, although no pathological specimen was obtained. Neurilemmoma arising from the hypoglossal nerve is rare, but in this case it necessarily caused IHNP as a first symptom, because the nerve from which the tumor originated showed signs of marked dysfunction before adjacent nerves are involved.<sup>1</sup> An intrabony lesion limited to the hypoglossal canal would spare the remaining cranial nerves and result in an isolated nerve deficit, as in the case described.

Metastasis to the base of the skull often results in an isolated cranial nerve deficit, occasionally leading to the detection of primary cancer. IHNP can occur as an initial symptom of metastasis to the occipital condyle area.<sup>26</sup> Regardless of the patient's history with respect to cancer, a bone scan is indicated for a person with IHNP so that metastasis to the base of the skull might be ruled out.

Head and neck trauma can also cause traumatic IHNP.<sup>10-15</sup> Mechanically, traumatic IHNP can be classified as whiplash-type hyperextension neck injury<sup>10-12</sup> or occipitoatlantoaxial complex injury.<sup>13,14</sup> An interesting feature of traumatic IHNP is that it occasionally appears in the late post-traumatic period. This delayed onset of clinical symptoms may lead to referral to an oral surgeon for assistance. Of the five reported cases of traumatic IHNP, only one case showed immediate onset after injury<sup>10</sup> and the others showed delayed onset from 6 days to 45 days after injury.<sup>11-14</sup> CT scans are essential for patients with IHNP and also a history of persistent neck pain and stiffness after a head and neck injury; the possibility of a fracture involving the occipital condyle<sup>14</sup> or odontoid process,<sup>13</sup> which is difficult to demonstrate on plain radiography, has to be investigated.

When a patient with a history of trauma shows no evidence of fracture of the occipitoatlantoaxial complex on a CT scan or MRI, the cause of IHNP is considered to be whiplash involving hyper-extension of the hypoglossal nerve of the neck.<sup>10-12</sup> In such a case, IHNP often appears bilaterally, but it usually improves spontaneously without specific treatment. Iatrogenic traumatic IHNP results from operative complication after carotid endarterectomy.<sup>27,28</sup> A review of the literature indicates a 5% incidence of IHNP after such surgery.<sup>29</sup>

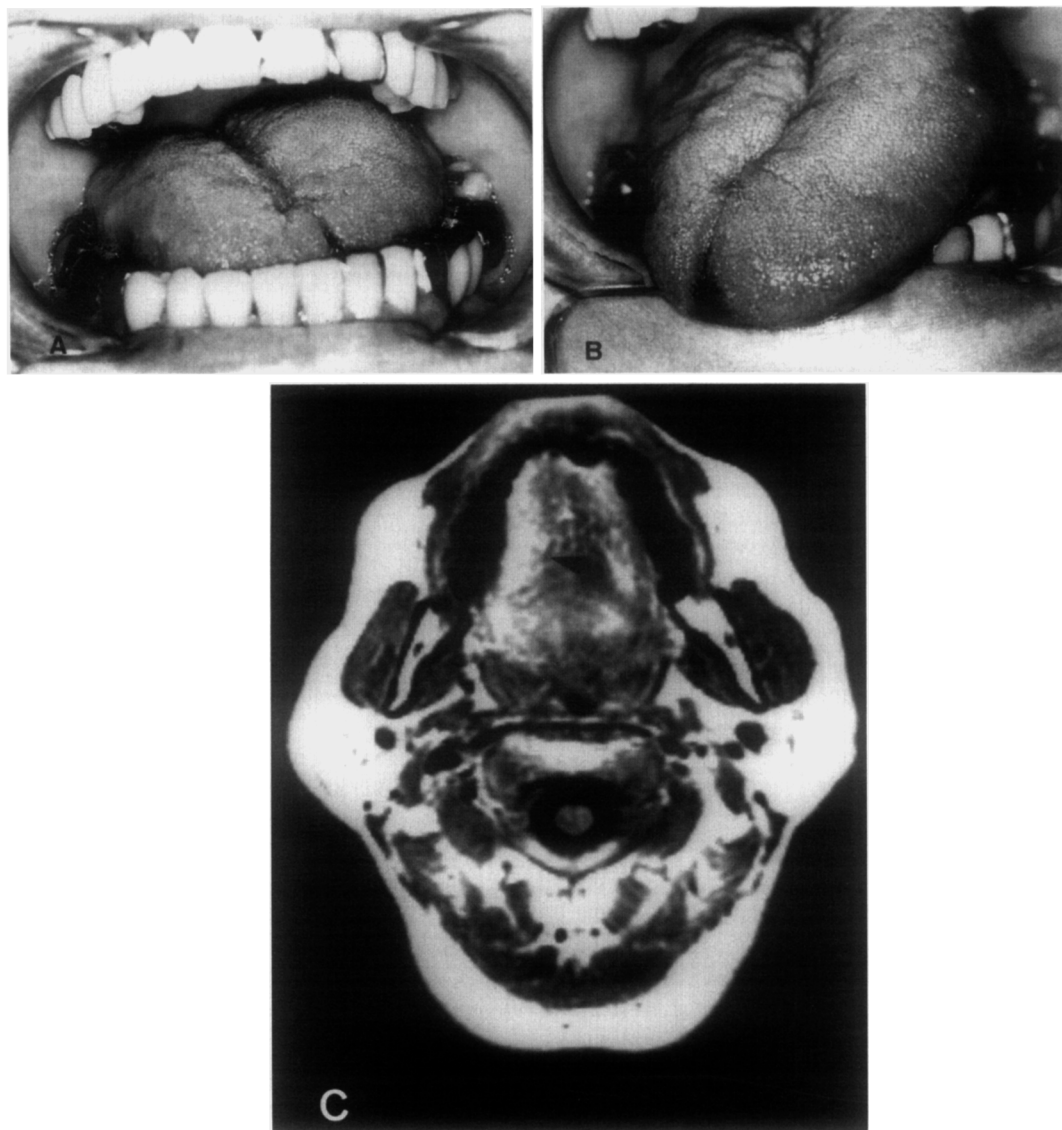


Fig. 2. A, Slight right-sided hemiatrophy and deviation of tongue toward left side at rest. B, Deviation of tongue toward right side on protrusion. C, Axial T<sub>1</sub>-weighted MR image shows that signal intensity of right half of tongue is greater than that of left half (*arrow*).

Most cases result not from transection but from hyperextension of the nerve during surgery.

In addition to head and neck trauma, IHNP with severe neck pain and stiffness can develop in association with tuberculosis<sup>19,20</sup> or rheumatoid arthritis<sup>18</sup> of the cervical spine. As these conditions progress, destructive changes of the occipitoatlantoaxial complex occur. Destruction of the base of the skull involving the hypoglossal canal or subluxation of the odontoid process can cause IHNP with severe neck pain and marked restriction of neck movement. In the current cases, neither patient has a significant history of trauma or persistent neck pain and stiffness.

Another major cause of IHNP is ICA abnormality. The hypoglossal nerve leaves the cranium through the hypoglossal canal, passes down beside the internal and external carotid arteries, and then passes anteriorly across the external carotid artery near the angle of the mandible. Because of its contiguity to the ICA, the hypoglossal nerve is subject to direct compression or stretching as a result of vascular abnormalities. Vascular abnormalities reported to cause IHNP include ICA aneurysm, pseudoaneurysm, spontaneous dissection,<sup>16,17</sup> tortuosity of the ICA,<sup>30</sup> and lateral position of the external carotid artery.<sup>31</sup> Patients with ICA vascular abnormalities tend to have preceding episodes of

severe, throbbing, ipsilateral temporal pain 6 to 10 days before the onset of IHNP. To investigate the possibility of ICA vascular abnormality, carotid angiography is indicated for patients who experience severe headache before the onset of IHNP. In Case 2, the cause of the IHNP did not appear to be related to ICA vascular abnormality, because the patient had no history of severe headaches and CT scans and angiography of the carotid arteries were normal.

Several cases of IHNP of unknown origin have been reported.<sup>22,23</sup> Although cases of IHNP after tooth extraction<sup>24</sup> and arthroscopy of the shoulder<sup>25</sup> have been reported, its relationship to the procedures in these cases remains uncertain. In a case of systemic lupus erythematosus with IHNP,<sup>21</sup> the cause of the IHNP was not established. Accordingly, these cases should be categorized as IHNP of unknown origin. Fortunately, cases of unknown origin tend to be benign. In most cases, IHNP improved slowly and resolved completely within a year without specific treatment. In the current Case 2, no lesion was observed on CT scans, MRIs, bone scan, or carotid angiography. Over a 2-year follow-up period, the patient showed no further cranial nerve deficit or long tract signs and no evidence of improvement of IHNP. The cause did not appear to be a gradually expanding space-occupying lesion. Periodic follow-up without specific treatment was indicated because of the possibility that the IHNP occurred as an initial sign of a different neuropathologic condition.

The relationship between IHNP and viral infections such as infectious mononucleosis,<sup>32</sup> the common cold,<sup>33</sup> and influenza vaccination<sup>34</sup> has been discussed in previous publications. During the past decade, however, few studies have reported IHNP in association with viral infection. The pathogenesis of IHNP in cases of viral infection is controversial.

The symptoms and dysfunction of IHNP change time dependently. Hemiatrophy and deviation of the tongue on protrusion are typical symptoms. However, hemiatrophy does not occur immediately after the onset of IHNP. Several weeks after onset, the affected side of the tongue appears to be larger than the healthy side at rest.<sup>11,22-25</sup> This may be one reason that IHNP tends to be overlooked at the time of initial clinical examination. Hemiatrophy with fatty replacement requires time to manifest. In the current cases, hemiatrophy of the tongue was clearly demonstrated on MRIs by a shift of the septum to the ipsilateral side. High signal intensity of the paralyzed tongue, similar to that of subdermal fat tissue on T<sub>1</sub>-weighted images, indicated fatty displacement of the tongue muscle. No previous report has presented correlation between MRIs and hemiatrophy of the tongue. CT scans and MRIs are useful in assessing not only the causes of IHNP but also the changes of the

tongue that occur with IHNP; this fosters early and accurate diagnosis of the condition. Silvester<sup>8</sup> reported a case of adenoid cystic carcinoma of the tongue manifesting itself as hypoglossal nerve palsy. In this case, CT scans were used only to investigate a possibly primary neurologic cause of IHNP, and diagnosis was made based on patient's difficulty with moving the right side of the tongue. CT scans and MRIs of the tongue can differentiate adenoid cystic carcinoma from atrophy with fatty displacement produced by nerve palsy.

The extent of dysfunction produced by IHNP is alliterative and depends on the type of onset. Sudden onset of unilateral IHNP, typically caused by trauma or an ICA aneurysm, is usually accompanied by moderate dysarthria. Patients cannot adequately manipulate solid foods in the mouth with the tongue, and this occasionally leads to moderate dysphagia, which gradually resolves by means of a compensatory mechanism. Sudden onset of bilateral IHNP, which typically occurs in association with head and neck injury, is accompanied by severe dysphagia and dysarthria. Because the patient in such a case cannot move the tongue to swallow saliva, a tracheotomy is required to control aspiration into the lung.<sup>12</sup> On the other hand, slowly progressive unilateral IHNP, which generally occurs in association with a slowly expanding space-occupying lesion, is not accompanied by dysphagia. Patients become aware of slurred speech after hemiatrophy proceeds to a certain extent, as in the current cases.

Clinicians should know that most patients with unilateral IHNP have no complaints except slight dysarthria and that the affected side of the tongue often appears to be larger than the healthy side in a resting position. MRIs accurately evaluate the extent of atrophy and degeneration resulting from IHNP. Differential diagnosis requires the complete examination of medical history and systemic radiology, focusing on the variety of lesions that manifest themselves in connection with IHNP.

## REFERENCES

1. Ulso C, Sehested P, Overgaard J. Intracranial hypoglossal neurofibroma: diagnosis and postoperative care. *Surg Neurol* 1981;16:65-8.
2. Dalon EJ, Tucker WS, Rotenberg D, Chui M. Intracranial hypoglossal schwannoma as an unusual cause of facial nerve palsy. *J Neurosurg* 1982;56:420-3.
3. Shiraiishi T, Yanagida H, Takada K, Yasuhara Y. Unusual cranial metastasis from hepatoma presenting as isolated unilateral hypoglossal nerve paresis (case report). *Neurol Med Chir* 1992;32:166-8.
4. Hemmings KW. Isolated hypoglossal nerve palsy as a presenting feature of prostatic carcinoma: a case report. *Br J Oral Maxillofac Surg* 1990;28:125-7.
5. Woo E, Yu EL. Isolated hypoglossal nerve palsy due to metastatic germinoma in the neck: a ventriculoatrial shunt-related complication. *Neurosurgery* 1988;23:237-40.

6. Millingen K, Prentice M. Isolated unilateral hypoglossal nerve palsy due to a chondroid chordoma. *Clin Exp Neurol* 1987;23:213-7.
7. Cartwright MJ, Eisenberg MB, Page LK. Posterior fossa arachnoid cyst presenting with an isolated twelfth nerve paresis: case report and review of the literature. *Clin Neurol Neurosurg* 1991;93:69-72.
8. Silvester KC, Barnes S. Adenoid cystic carcinoma of the tongue presenting as a hypoglossal nerve palsy. *Br J Oral Maxillofac Surg* 1990;28:122-4.
9. Bochlogyros PN, Kanakis P, Tsikou-papafrangou N, Chase D. A large, painless mass in the submandibular space. *J Oral Maxillofac Surg* 1992;50:1213-6.
10. Brennan RJ, Shirley JP, Compton JS. Bilateral hypoglossal nerve palsies following head injury. *J Emerg Med* 1993;11:167-8.
11. Dukes K, Bannerjee SK. Hypoglossal nerve palsy following hyperextension neck injury. *Injury* 1993;24:133-4.
12. Freixinet J, Lorenzo F, Gallego H, Rodriguez De Castro R, Sole J. Bilateral traumatic hypoglossal nerve paralysis. *Br J Oral Maxillofac Surg* 1996;34:309-10.
13. Orbay T, Aykol S, Seckin Z, Ergun R. Late hypoglossal nerve palsy following fracture of the occipital condyle. *Surg Neurol* 1989;31:402-4.
14. Castling B, Hicks K. Traumatic isolated hypoglossal nerve palsy: case report and review of the literature. *Br J Oral Maxillofac Surg* 1995;33:171-3.
15. Nagai K, Sakuramoto C, Goto F. Unilateral hypoglossal nerve paralysis following the use of the laryngeal mask airway. *Anaesthesia* 1994;49:603-4.
16. Anzola GP, Gualandi GF, Orlandini A, Scipione V. Lower cranial nerve palsy produced by internal carotid artery dilation: report of two cases. *Ital J Neurol Sci* 1987;8:375-9.
17. Nusynowitz RN, Stricof DD. Pseudoaneurysm of the cervical internal carotid artery with associated hypoglossal nerve paralysis: demonstration by CT and angiography. *Neuroradiology* 1990;32:229-31.
18. Macedo TF, Gow PJ, Heap SW, Wallis WE. Bilateral hypoglossal nerve palsy due to vertical subluxation of the odontoid process in rheumatoid arthritis. *Br J Rheumatol* 1988;27:317-20.
19. Richards IM, White AM, O'Sullivan MM, Jessop JD, Williams BD. Unilateral palsy of the hypoglossal nerve in a patient with tuberculosis of the first cervical vertebra. *Br J Rheumatol* 1989;28:540-2.
20. Lifeso R. Atlanto-axial tuberculosis in adults. *J Bone Joint Surg Br* 1987;69:183-7.
21. Chan CN, Li E, Lai FM, Pang JA. An unusual case of systemic lupus erythematosus with isolated hypoglossal nerve palsy, fulminant acute pneumonitis, and pulmonary amyloidosis. *Ann Rheum Dis* 1989;48:236-9.
22. Sugama S, Matsunaga T, Ito F, Eto Y, Maekawa K. Transient, unilateral isolated hypoglossal nerve palsy. *Brain Dev* 1992;14:122-3.
23. Saito H, Onuma T. Isolated hypoglossal nerve palsy and Horner's syndrome with benign course. *J Neurol Neurosurg Psychiatry* 1991;54:282-3.
24. Stankiewicz JA, Pazevic JP. Hypoglossal nerve palsy after tooth extraction. *J Oral Maxillofac Surg* 1988;46:148-9.
25. Mullins RC, Drez D Jr, Cooper J. Hypoglossal nerve palsy after arthroscopy of the shoulder and open operation with the patient in the beach-chair position: a case report. *J Bone and Joint Surg* 1992;74-A:137-9.
26. Greenberg HS, Deck MDF, Vikram B, Chu FCH, Posner JB. Metastasis to the base of the skull: clinical findings in 43 patients. *Neurology* 1981;31:530-7.
27. Maniglia AJ, Han DP. Cranial nerve injury following carotid endarterectomy: an analysis of 336 procedures. *Head Neck* 1991;13:121-4.
28. Gutrecht JA, Jones HR Jr. Bilateral hypoglossal nerve injury after bilateral carotid endarterectomy. *Stroke* 1988;19:261-2.
29. Knight FW, Yeager RM, Morris DM. Cranial nerve injuries during carotid endarterectomy. *Am J Surg* 1987;154:529-32.
30. Scotti G, Melancon D, Olivier A. Hypoglossal paralysis due to compression by a tortuous internal carotid artery in the neck. *Neuroradiology* 1978;14:263-5.
31. Ueda S, Koyama Y, Takase K. Peripheral hypoglossal nerve palsy caused by lateral position of the external carotid artery and an abnormally high position of bifurcation of the external and internal carotid arteries (case report). *Stroke* 1984;15:736-9.
32. Wright GDS, Lee KD. An isolated right hypoglossal nerve palsy in association with infectious mononucleosis. *Postgrad Med J* 1980;56:185-6.
33. Afifi AK, Rafai ZH, Faris KB. Isolated, reversible hypoglossal nerve palsy. *Arch Neurol* 1984;41:1218.
34. Felix JK, Schwartz RH, Myers GJ. Isolated hypoglossal nerve paralysis following influenza vaccination. *Am J Child* 1976;13:82-3.

*Reprint requests:*

Susumu Omura, DDS, PhD

Department of Oral and Maxillofacial Surgery

School of Medicine, Yokohama City University

3-9 Fukuura Kanazawa-ku, Yokohama, 236 Japan