

Yoshifumi Fukuo^{a,b}
Tomohiro Abe^{a,b}
Seiji Hayasaka^b

^a Ophthalmology, Itoigawa Hospital, Niigata, Japan;

^b Department of Ophthalmology, Toyama Medical and Pharmaceutical University, Toyama, Japan

Acute Comitant Esotropia in a Boy with Head Trauma and Convulsions Receiving Carbamazepine

Abstract

We examined an 11-year-old boy who complained of acute onset of diplopia. The patient had head trauma and postsurgical convulsions and had been treated with carbamazepine. Diplopia developed after the dose of carbamazepine was increased to 700 mg/day. On examination, comitant esotropia and lateral gaze nystagmus were found. These disorders disappeared after carbamazepine was decreased to 400 mg/day. We believe that acute comitant esotropia and lateral gaze nystagmus may have been precipitated by head trauma and carbamazepine in our patient.

Key Words

Acute comitant esotropia
Head trauma
Carbamazepine

Introduction

Acute onset of esotropia with diplopia in older children is uncommon in relation to the high frequencies of infantile or congenital esotropia [1–6]. We recently experienced this uncommon condition and nystagmus in a boy with head trauma and convulsions who was receiving carbamazepine.

Case Report

An 11-year-old boy complained of the sudden onset of diplopia on September 5, 1995. The patient had undergone the removal of an epidural hematoma following head trauma at the age of 6 years. Postsurgically, convulsions developed. Thereafter, the patient was treated with orally administered carbamazepine, 400–600 mg/day. The mean serum level of carbamazepine measured 3 times in 1995 was 9.1 µg/ml. The patient also had atopic dermatitis for 6 years, which was sometimes treated with corticosteroid ointment but not with systemic corticosteroids. No preceding infection, physical or psychic shock, or ocular occlusion were noted. In late August, the patient received carbamazepine, 700 mg/day.

On examination, comitant esodeviation with 40 prism diopters at both near and distance was found (fig. 1). The deviations determined by cover and alternate cover tests were the same. The result of after image test showed normal retinal correspondence. Crusts and scratches were visible on his face. His visual acuity was 1.0 OD and 0.8 OS.

Eye movement was not disturbed bilaterally. Left lateral gaze nystagmus was seen. Cycloplegic refraction was +1.0D OD and +1.25D OS. Both eyes appeared otherwise normal. Goldmann perimetry showed bilaterally normal findings. On computed tomography of the brain and orbits, the scar was observed, but no brain edema was found. No other neurologic abnormalities were noted. The patient's body weight was 56 kg. Laboratory test results, including blood cell count, blood chemistry, urinalysis and chest X-ray were negative or within normal range. The serum level of carbamazepine was 12.5 µg/ml.

The esodeviation remained for 4 days. The dose of carbamazepine was reduced to 400 mg/day on September 6. The esodeviation and lateral gaze nystagmus disappeared on September 9, 1995 (fig. 2). No esodeviation determined by alternate cover test or diplopia was observed during the follow-up period of 12 months. The patient had 120 arc seconds of stereoacuity at that time.

Discussion

Acute comitant esotropia reportedly occurs in older children and adults. It is sometimes accompanied by diplopia, large angle esotropia, and no signs of paralysis [1–6]. Our patient was an 11-year-old boy who had diplopia and large angle esotropia. He had no signs of paralysis. Acute comitant esotropia is thought to develop following artificial interruption of fusion, such as patching one eye, or physical or

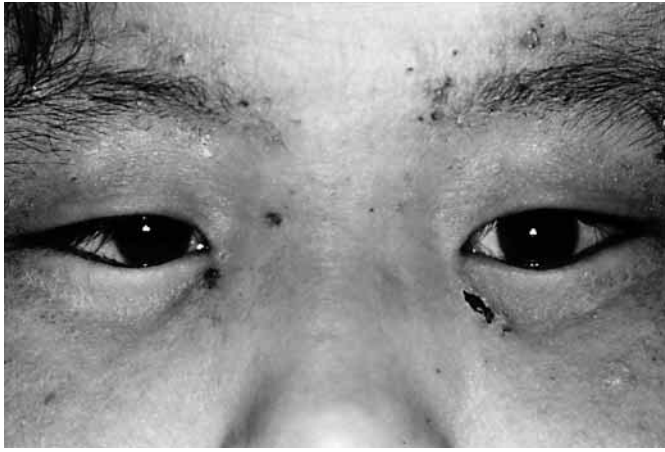

Fig. 1. Acute comitant esotropia, crusts and scratches are visible on September 5, 1995.

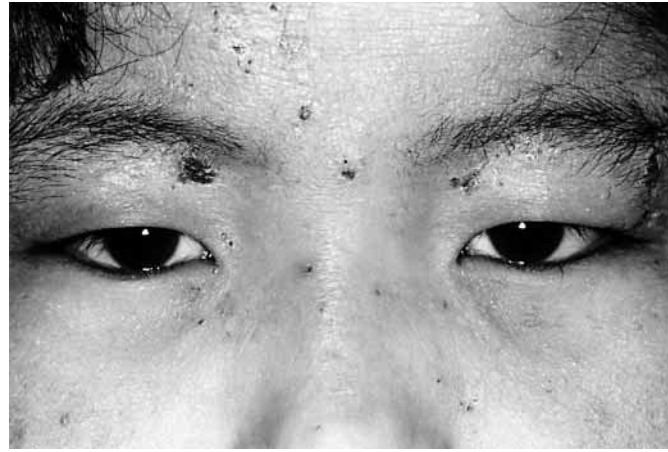


Fig. 2. No esotropia is observed on September 10, 1995.

psychic shock. The disorder is sometimes associated with myopia and neurological disease, including brain tumor [1–6]. Our patient had head trauma and convulsions, but no patching of one eye, physical or psychic shock, myopia, or brain tumor. Acute comitant esotropia in most patients is reportedly permanent, although a few cases become transient [1, 3]. When brain tumor and edema improve, the acute comitant esotropia is thought to disappear [3]. Our patient exhibited esotropia for the short duration of 4 days. It is unlikely that our patient had transient decompensating esophoria, because esophoria was not found by cover and alternate cover test when esodeviation disappeared.

Our patient had received carbamazepine for the treatment of convulsions. Several adverse effects including

ataxia, diplopia, dizziness, and gaze nystagmus are usually associated with high plasma levels of the drug and disappear after decreasing the dose of the drug [7, 8]. In our patient, acute comitant esotropia and lateral gaze nystagmus developed after increasing the dose of the drug. The serum level of carbamazepine was elevated at that time.

Our patient had crusts and scratches on his face. It is unlikely that atopic dermatitis and steroid ointment caused the acute onset of comitant esotropia, because many patients with atopic dermatitis who are treated with the ointment do not show this effect.

We believe that the esotropia and nystagmus in our patient may have been precipitated by head trauma and carbamazepine.

References

- 1 Burian HM, Miller JE: Comitant convergent strabismus with acute onset. *Am J Ophthalmol* 1958;45:55–64.
- 2 Clark AC, Nelson LB, Simon JW, Wagner R, Rubin SE: Acute acquired comitant esotropia. *Br J Ophthalmol* 1989;73:636–638.
- 3 Williams AS, Hoyt CS: Acute comitant esotropia in children with brain tumors. *Arch Ophthalmol* 1989;107:376–378.
- 4 Ohtsuki H, Hasebe S, Kobashi R, Okano M, Furuse T: Critical period for restoration of normal stereoacuity in acute-onset comitant esotropia. *Am J Ophthalmol* 1994;118:502–508.
- 5 Hoyt CS, Good WV: Acute onset comitant esotropia: When is it a sign of serious neurological disease? *Br J Ophthalmol* 1995;79:498–501.
- 6 Burke J, Firth AY: Temporary prism treatment of acute esotropia precipitated by fusion disruption. *Br J Ophthalmol* 1995;79:787–788.
- 7 Riva R, Contin M, Albani F, Perucca E, Ambrosetto G, Procaccianti G, Santucci M, Baruzzi A: Lateral gaze nystagmus in carbamazepine-treated epileptic patients: Correlation with total and free plasma concentrations of parent drug and its 10,11-epoxide metabolite. *Ther Drug Monit* 1985;7:277–282.
- 8 Remler BF, Leigh RJ, Osorio I, Tomsak RL: The characteristics and mechanisms of visual disturbance associated with anticonvulsant therapy. *Neurology* 1990;40:791–796.