

Transient autobiographic amnesia

EEG and single-photon emission CT evidence of an organic etiology

Annalena Venneri, PhD; and Paolo Caffarra, MD

Article abstract—We describe a 44-year-old patient who had a transient attack of autobiographic amnesia. When assessed during the attack, her learning abilities were normal, with no sign of anterograde amnesia. In the remote memory domain, she showed a striking dissociation between a detailed knowledge of public events and famous people and a complete loss of autobiographic information. During the attack, EEG recorded bilateral frontotemporal slow waves and single-photon emission CT (SPECT) showed hypoperfusion in the right temporal and parietal lobes; no abnormalities were detected when both EEG and SPECT were repeated 1 week later. This case provides evidence for an organic etiology for the episode and supports the hypothesis that autobiographic memory is independent of other forms of retrograde memory.

NEUROLOGY 1998;50:186–191

Amnesia may be observed as a transient or permanent phenomenon. Transient global amnesia (TGA) is common (see refs. 1 and 2 for a review). More recently, a few cases of transient partial deficits of memory, affecting verbal memory only,³ or topographic memory⁴ have been reported.

Cases of transient memory deficit with loss of personal identity can also be found in the literature (see ref. 5 for a review). These have been classified as cases of hysterical or psychogenic amnesia (psychogenic fugue), where the critical features for differentiating them from organic amnesia were loss of personal identity (preserved in genuine cases of organic TGA) and preserved anterograde memory (normally greatly impaired in organic TGA).

We report a patient who suffered from a transient autobiographic memory loss, from which she recovered spontaneously after 17 hours. Her neuropsychological and neuroimaging findings are discussed, focusing on the differential diagnosis between an organic and a psychogenic etiology.

Case report. TB is a 44-year-old right-handed woman with 13 years of formal education who works as a secretary with no history of psychiatric disturbance or drug or alcohol abuse.

On June 12, 1993, during her morning coffee break, she left her office and went into a nearby shop. At the check-out, she became confused and repeatedly asked the people standing near to her what was happening. She could not recall anything about herself and was so distressed that the shop manager called an ambulance. She was admitted after a few minutes to the emergency room of Parma Hospital. Her neurologic examination disclosed no sign of sensory or motor deficits, and deep tendon reflexes were symmetric. She was alert, spatially oriented, but unable to

recall any personal information about herself, her work, and family contexts. She appeared worried and could not understand why she could remember everything but information about herself.

TB's profile appeared different from cases of TGA, because she could easily remember things that had happened since the onset of the episode. An interview with a psychiatrist discovered no pathologic profile. Nor did we find by interviewing her husband anything relevant or any possible motive that could justify desire to simulate amnesia nor any stressful event that could have precipitated it. TB was under no pharmacologic treatment of any kind. Her routine blood and chemical investigations were within normal limits.

To ascertain the nature and the extent of TB's memory disorder, a neuropsychological examination was carried out during her stay in the emergency room.

Neuropsychologic examination. TB was cooperative and willing to perform the neuropsychologic tasks. She performed normally on digit span (seven digits forward and five backward)⁶ and visuospatial span (five blocks).⁷ She scored well within the range of performance of the normal reference population on long-term memory tasks such as prose memory (10.5), paired associate learning (11.5),⁸ and supra-span spatial learning (15.32).⁷ Her score on an abstract reasoning task⁹ was close to the median score achieved by the normal reference sample as well as her performance on attention^{7,10} and language^{11,12} tests. TB's semantic knowledge was intact; she could name and provide detailed physical descriptions of living and nonliving objects both after visual presentation and verbal description and name abstract things after verbal description. She knew the meaning of some symbols (e.g., wedding ring) and meaningful gestures.

Retrograde memory. TB's autobiographic memory was tested on a formal standardized questionnaire¹³ intended

From the Department of Psychology (Dr. Venneri), University of Aberdeen, UK; and the Istituto di Neurologia (Dr. Caffarra), University of Parma, Italy. Supported by M.U.R.S.T. grant 60%, 96 to P.C.

Received February 15, 1997. Accepted in final form July 21, 1997.

Address correspondence and reprint requests to Dr. Annalena Venneri, Department of Psychology, University of Aberdeen, King's College, Aberdeen, AB24 2UB, UK.

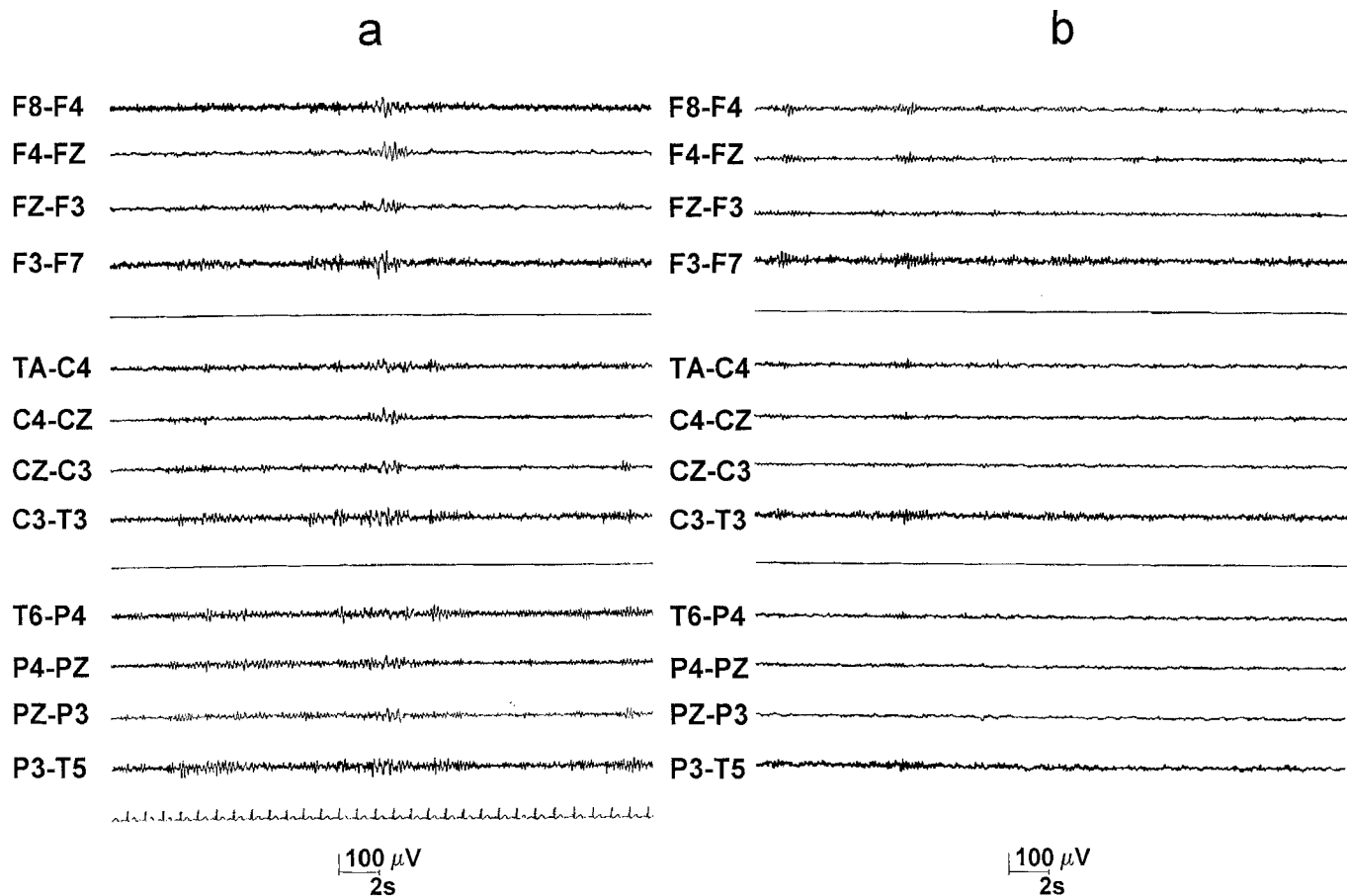


Figure 1. EEG performed during (a) and after (b) the episode of transient amnesia. Bilateral frontotemporal slow waves were recorded during the attack. No abnormalities were detected 1 week later.

to assess three periods of her life: childhood/adolescence, early adulthood, and late adulthood, up to 2 years before testing. She showed no recollection of any important event in her life. TB could tell the examiner her name (she had been told that by the hospital staff) but could not recollect any personal information. When she first saw them, TB failed to recognize her husband and daughter, toward whom she showed no emotional reaction. She was unable to give details of her own education and occupation. Asked if she could say something about the duties of a secretary, she was able to list possible duties as well as those of other professions (e.g., doctor, nurse, teacher). It was clear from the examination that she had lost both episodic and semantic autobiographic memory.

On the Famous Face Recognition Test,¹⁴ TB's performance was at ceiling; she could precisely indicate the face corresponding to the famous name stated by the examiner among four alternatives. She could also promptly identify—and provide the corresponding name, although not requested—the familiar face among four choices (one famous target and three unknown distracters) on the Familiarity Check Test.¹⁴ Her knowledge of events that had been in the news in the preceding 18 months was excellent. TB recalled all the major events that had taken place in Italian politics (at that time many representatives of the leading party had been prosecuted for corruption) for which she could recall time and place.

Seventeen hours after onset, after having had some sleep, TB spontaneously recovered and was discharged.

Neurophysiologic and neuroimaging findings. During the attack, the EEG recorded bilateral frontotemporal slow waves (figure 1a).

High-resolution single-photon emission CT (SPECT) was also carried out. Images were obtained with an annular SPECT (Vertex ADAC) with a spatial resolution of 7.2 mm full-width at half maximum (FWHM) in the center of the axial plane. The injected dose of ^{99m}Tc hexamethyl propyleneamine oxime (HM-PAO) was 740 Mbq (20 mCi) and imaging was performed 15 to 30 minutes after injection. Sixty-four axial slices, each 2 mm thick, were reconstructed. A SPECT image analysis was carried out on a SUN (SPARC) work station. Circular regions of interest (ROIs) were manually positioned on the cortical and subcortical structures and on the cerebellar hemispheres. Mean counts were calculated for each ROI. Average values were obtained from the multiple ROIs included in nine anatomofunctional areas according to the Damasio and Damasio¹⁵ atlas. The data were then analyzed as ratios between counts for the SPECT study in each anatomofunctional region and the cerebellum count.

The SPECT investigation showed a considerable reduction in blood flow in the right temporal and parietal regions (figure 2a). No abnormalities were detected by the EEG recorded 1 week later (June 19, 1993) (see figure 1b). A second SPECT study was carried out on that occasion, but no relevant abnormalities were detected (figure 2b).

No difference in blood flow was detected in the cerebellar regions, the two values being virtually identical; in

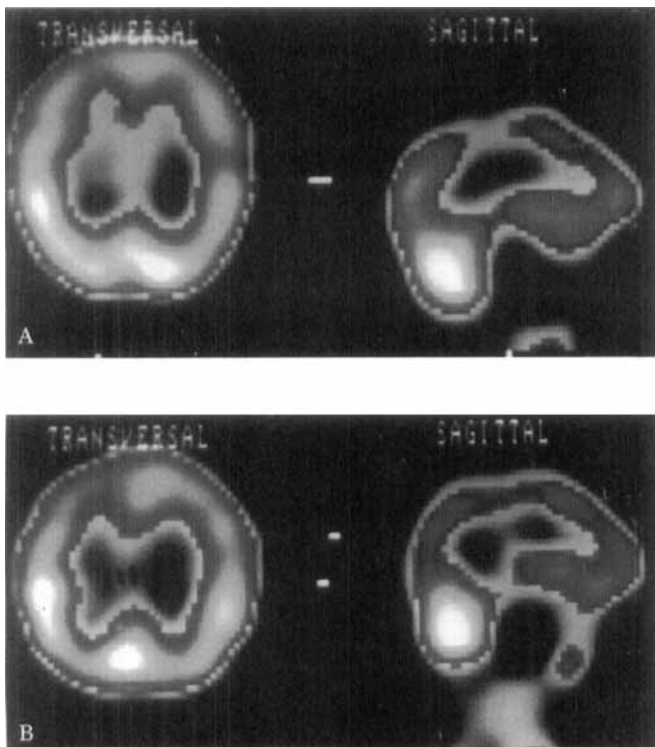


Figure 2. SPECT scans performed during (A) and after (B) the episode of transient memory loss. Transverse images are shown on the left side of each figure and sagittal images are shown on the right side of each figure. Hypoperfusion of the right temporal and parietal regions was detected during the attack. Cerebral perfusion appeared normal 1 week later.

contrast, a considerable blood flow increment (between 32% and 53%) was observed in the temporal and parietal regions (table). The increment in other cortical areas was not greater than 6%.

A CT was performed a few days later. No morphologic abnormalities were detected.

Follow-up. TB was re-examined 1 year later. No further episodes were reported; TB manifested no psychiatric disturbance since the foregoing episode of transient memory loss. During the re-examination, a structured psychiat-

Table Comparison between blood flow values expressed as ratios of the values normalized to the cerebellum (raw counts shown in parentheses) measured with SPECT during the attack (June 12) and 1 week later (June 19)

Cerebral area	June 12, 1993	June 19, 1993	Increment (%)
Parietal	0.428 (30,557)	0.656 (46,808)	53.182
Temporal	0.588 (41,948)	0.782 (55,759)	32.924
Cerebellum	1 (71,238)	1 (71,257)	0.027

The increase in blood flow is represented by the absolute value of the difference between the SPECT values obtained in the same cerebral areas during the attack and 1 week later and computing the percentage of increment with respect to the values acquired by the SPECT performed during the attack. The cerebral perfusion was virtually unmodified in the cerebellar regions; a marked difference between the two SPECTs was detected in the parietal and temporal areas.

ric interview (MMPI questionnaire) was also administered; her profile disclosed no personality abnormalities. Two more years have elapsed since the follow-up, and to the best of our knowledge, no further episodes have occurred.

Discussion. TB suffered an episode of transient autobiographic amnesia, her transient memory loss being confined to the autobiographic domain; her retrograde memory for famous people and events, her semantic memory, and her anterograde memory were all spared.

Etiology. Several etiologic hypotheses could justify TB's cognitive profile. Malingering was ruled out, because this patient had nothing to gain by simulating amnesia neither at the time of this episode nor afterward as ascertained by the follow-up. A more difficult problem is differentiating between psychogenic and organic causes of amnesia, especially when no obvious damage to the gross structures of the brain is found. Without a clear "link between brain and behavior," this argues for a psychogenic label. However, on some occasions, abnormal brain functioning—in absence of structural damage—is accepted as evidence of an organic etiology for a phenomenon. For example, abnormalities of the electrical activity of the brain (as detected with EEG) without detectable structural damage is a well-known cause of epilepsy; nobody, however, questions the organic origin of epilepsy. In this patient, in addition to the neurophysiologic and neuroimaging findings, the clinical presentation also supports an organic etiology. Some authors^{16,17} claim that loss of personal identity is a critical feature of psychogenic fugues, and it is rarely observed in organic amnesia. But there is evidence that repetitive questioning is characteristic of organic amnesia and is not observed in psychogenic fugues.¹⁸ Indeed, TB's great concern about her condition is at odds with a sense of general indifference toward the situation observed in fugue states.¹⁹ Moreover, several people witnessed the onset of TB's attack, whereas in cases of psychogenic fugues, no clear testimony of the onset is available, and often the patient is found wandering around, sometimes even for several days.

Neurophysiology and neuroimaging. EEG abnormalities (both slow waves and sharp waves) in cases of TGA have been reported many times (see ref. 5 for review), but no clear agreement on the meaning of these abnormalities is available. Some authors²⁰ claim that in many cases these abnormalities are rather nonspecific. TB's EEG record during the attack showed bilateral frontotemporal slow waves that were not detected by the record 1 week later. However, EEG data alone would not support a strong conclusion. TB underwent a cerebral SPECT twice, during the attack and 1 week later. Yet, data on the test-retest reliability of blood flow measurement with SPECT are scanty, and one should establish that the right temporoparietal hypoperfusion detected during the attack cannot be accounted for by low reliability of the SPECT technique or physio-

logic changes in perfusion of those areas. A study of the reproducibility of SPECT results²¹ has shown a high positive correlation (with level of significance ranging from $p < 0.001$ to $p < 0.01$) between two different measurements with SPECT. In this study, the intraindividual variability between the measurements ranged from 0.3% to 15% (mean 6.2%). Therefore, the proportion of the changes (ranging from 32% to 53%) in the temporal and parietal areas observed in our patient's results is extremely large, indicating that the SPECT detected genuine pathologic changes that caused TB's amnesic episode. This rules out the hypothesis that the difference we detected might be the result of a technical artefact. It may be suggested that the changes might have been caused by anxiety. However, TB's SPECT profile does not resemble those of cases of psychiatric disease, including anxiety disturbances, which show abnormalities mainly in the frontal lobes.^{22,23}

A few studies have reported neuroimaging findings in TGA. Reduced brain perfusion and metabolism (unilateral or bilateral, more frequently of the frontal and/or temporal regions) detected with SPECT or PET during TGA episodes has been repeatedly reported.²⁴⁻²⁹ Several physiopathologic explanations have been provided in those cases: ischemia, seizures, and migraine. Our patient had no history of migraine, seizures, or vascular problems; however, the possibility that the first SPECT might have detected postischemic hypoperfusion cannot be excluded.

Neuroanatomic considerations. Some studies^{30,31} emphasize the role of the frontal lobes in autobiographic memory. A disparate finding is that of Hokkanen et al.,³² who described a patient showing isolated retrograde amnesia for autobiographic memory after dysfunction of the left temporal lobe (detected by SPECT and EEG). TB's temporary abnormalities were localized bilaterally in the fronto-temporal regions (as recorded by EEG) and in the right temporal and parietal lobes (as detected by SPECT). The cerebral areas involved in the electrical and blood flow abnormalities in our patient partially overlap with those identified in other cases of autobiographic memory loss, thus supporting the hypothesis of an organic etiology for TB's amnesia.

The neuroanatomic evidence on the question of which cerebral areas are concerned with autobiographic information is conflicting and inconclusive. A descriptive model³³ has been suggested to explain the cognitive organization of autobiographic memory. This model provides an integration of structures and processes involved in this type of memory, positing a thematic organization for the cognitive architecture of autobiographic memory, according to major life events. However, Conway³⁴ suggested that although autobiographic memory seems to have a very complex cognitive architecture, some aspects of the model may be localized. A detailed discussion of the model is beyond the aim of this article; we will only mention that it incorporates several steps, each of

which may have a different location in the brain. Some aspects (i.e., the generative retrieval cycle) may well be localized in the frontal areas; others (i.e., the complex thematic knowledge base) might be located in other neocortical areas and others (i.e., the phenomenologic record) in the posterior sensory areas. Either dysfunction of the neurologic pathways that connect these various areas or damage to specific areas—or indeed a combination of both—may result in autobiographic memory disturbances. This view justifies the heterogeneity of anatomic lesions that resulted in loss of autobiographic information reported in the literature.

A recent study with PET³⁵ that aimed to establish the functional anatomy involved in the retrieval of affect-laden autobiographic information has shown that the neural substrate for autobiographic memory involves "a network of primarily right hemispheric regions including temporomedial and temporolateral cortex, amygdala and hippocampus-parahippocampus, insula, posterior cingulate cortex, temporoparietal cortex, and prefrontal cortex" (p. 4277). Evidence from this study seems to point to a widespread substrate for autobiographic memory, probably because such memory involves affect-based information. The findings of this activation study are strongly in agreement with the SPECT findings of our patient, who shows loss of autobiographic information and decrease in blood flow in the right temporoparietal areas. In this view, the possibility that the simultaneous presence in our patient of autobiographic memory loss and a decrease in blood flow in the right temporoparietal regions may be mere coincidence seems rather unlikely.

Cognitive aspects. Permanent selective loss of memory for autobiographic information has been already observed in a few cases.^{32,36-40} Therefore, it seems reasonable that the same phenomenon may be observed as a transient loss. The transient nature of the loss should not be surprising; episodes of partial memory loss have been already reported (e.g., verbal memory,³ topographic memory⁴). As for other aspects of memory, it is possible that memory for autobiographic information might be temporarily disrupted and give rise to transient deficits, from which abrupt recovery is possible.

The case we described provides further support for the hypothesis of a fractionation of retrograde memory into subcomponents,⁴¹ confirming the independent status of autobiographic memory. TB showed a striking dissociation between her intact knowledge of remote public events and famous people and her complete loss of both episodic and semantic autobiographic information, components of autobiographic memory that have often been reported as dissociable.^{36-38,42,43}

Conclusion. This case provides evidence of a selective transient deficit of memory affecting the autobiographic domain whose onset, limited duration, and clinical presentation parallels cases of TGA. We provided evidence of neurophysiologic and blood flow abnormalities during the attack, with subsequent re-

turn to normality. On consideration of several etiologic hypotheses, we believe that the evidence is strong enough to support an organic origin for the episode.

The distinction between organic and psychogenic amnesia, however, remains very subtle. Markowitsch¹⁹ stressed the similarities between the two forms of amnesia from a cognitive point of view, suggesting that the actual mechanism responsible for loss of memories for retrograde information is the consequence of an inability of access to information both in organic and psychogenic amnesia, because both represent a temporary (and partial or selective) memory loss. Despite these similarities, we argue that a combination of clinical, neuropsychological, neurophysiologic, and neuroimaging examinations may provide some help for differentiating the etiology. As with TGA, however, the neurologic factor triggering the episode remains unexplained.

Acknowledgment

We are grateful to Bruno Calbani, Nuclear Medicine Unit, Parma General Hospital, who performed the two SPECT studies.

References

1. Fisher CM, Adams RD. Transient global amnesia. *Acta Neurol Scand* 1964;40:7-83.
2. Hodges JR, Warlow CP. Syndromes of transient amnesia: toward a classification. A study of 153 cases. *J Neurol Neurosurg Psychiatry* 1990;53:834-843.
3. Damasio AR, Graff-Radford NR, Damasio H. Transient partial amnesia. *Arch Neurol* 1983;40:656-657.
4. Stracciari A, Lorusso S, Pazzaglia P. Transient topographical amnesia. *J Neurol Neurosurg Psychiatry* 1994;57:1423-1425.
5. Hodges JR. Transient amnesia. Clinical and neuropsychological aspects. London: W.B. Saunders Company, 1991.
6. Orsini A, Grossi D, Capitani E, Laiacona M, Papagno C, Vallar G. Verbal and spatial immediate memory span: normative data from 1355 adults and 1112 children. *Ital J Neurol Sci* 1987;8:539-548.
7. Spinnler H, Tognoni G. Standardizzazione e taratura italiana di test neuropsicologici. *Ital J Neurol Sci* 1987;6(suppl. 8):1-120.
8. Novelli G, Papagno C, Capitani E, Laiacona M, Cappa SF, Vallar G. Tre test clinici di memoria verbale a lungo termine. Taratura su soggetti normali. *Arch Psicol Neurol Psichiatria* 1986;47:278-296.
9. Raven JC. Progressive matrices: sets A, AB, and B. *Etablissements d'Applications Psychotechniques*. Seine: Clamart, 1947.
10. Venneri A, Molinari MA, Pentore R, Cotticelli B, Nichelli P, Caffarra P. Shortened Stroop color-word test: its application in Alzheimer's disease. In: Nicolini M, Zatta PF, Corain B, eds. Alzheimer's disease and related disorders. New York: Pergamon, 1993:81-82.
11. De Renzi E, Faglioni P. Normative data and screening power of a shortened version of the Token Test. *Cortex* 1978;14:41-49.
12. Novelli G, Papagno C, Capitani E, Laiacona M, Cappa SF, Vallar G. Tre test clinici di produzione lessicale. Taratura su soggetti normali. *Arch Psicol Neurol Psichiatria* 1986;47:477-506.
13. Borrini G, Dall'Ora P, Della Sala S, Marinelli L, Spinnler H. Autobiographical memory. Sensitivity to age and education of a standardised inquiry. *Psychol Med* 1989;19:215-224.
14. Faglioni P, Cremonini AM, De Renzi E. Taratura su soggetti normali di test di facce sconosciute e familiari. Un contributo allo studio della prosopagnosia. *Arch Psicol Neurol Psichiatria* 1991;52:339-350.

15. Damasio H, Damasio AR. Lesions analysis in neuropsychology. New York: Oxford University Press, 1989.
16. Kopelman MD. Amnesia: organic and psychogenic. *Br J Psych* 1987;150:428-442.
17. Kopelman MD, Christensen H, Puffett A, Stanhope N. The great escape: a neuropsychological study of psychogenic amnesia. *Neuropsychologia* 1994;32:675-691.
18. Hodges JR, Ward CD. Observation during transient global amnesia: a behavioural and neuropsychological study of five cases. *Brain* 1989;112:595-620.
19. Markowitsch HJ. Retrograde amnesia: similarities between organic and psychogenic forms. *Neurol Psych Brain Res* 1996;4:1-8.
20. Miller JW, Yanagihara T, Petersen RC, Klass DW. Transient global amnesia and epilepsy. Electroencephalographic distinction. *Arch Neurol* 1987;44:629-633.
21. Podreka I, Baumgartner C, Suess E, et al. Quantification of regional cerebral blood flow with IMP-SPECT. *Stroke* 1989;20:183-191.
22. Machlin SR, Harris GJ, Pearlson GD, Hoehnsaric R, Jeffery P, Camargo EE. Elevated medial-frontal cerebral blood-flow in obsessive-compulsive patients. A SPECT study. *Am J Psychiatry* 1991;148:1240-1242.
23. Woods SW. Regional cerebral blood-flow imaging with SPECT in psychiatric disease. Focus on schizophrenia, anxiety disorders, and substance abuse. *J Clin Psychiatry* 1992;53:20-25.
24. Trillet M, Croisile B, Philippon B, Vial C, Laurent B, Guillot M. Ictus amnésique et débits sanguins cérébraux. *Rev Neurol* 1987;143:536-539.
25. Fayad P, Kain T, Hoffer P, Smith E, Brass LM. SPECT findings in transient global amnesia (TGA). *Neurology* 1990;40(suppl. 1):171.
26. Stillhard G, Landis T, Schiess R, Regard M, Sailer G. Bitemporal hypoperfusion in transient global amnesia: 99m-Tc-HM-PAO SPECT and neuropsychological findings during and after an attack. *J Neurol Neurosurg Psychiatry* 1990;53:339-342.
27. Laloux P, Brichant C, Cauwe F, Decoster P. Technetium-99m HM-PAO single photon emission computed tomography imaging in transient global amnesia. *Arch Neurol* 1992;49:543-546.
28. Lin KN, Liu RS, Yeh TP, Wang SJ, Liu HC. Posterior ischemia during an attack of transient global amnesia. *Stroke* 1993;24:1093-1095.
29. Baron JC, Petit-Taboué MC, Le Doze F, Desgranges B, Ravenel N, Marchal G. Right frontal cortex hypometabolism in transient global amnesia. A PET study. *Brain* 1994;117:545-552.
30. Kopelman MD. Frontal dysfunction and memory deficits in the alcoholic Korsakoff syndrome and Alzheimer-type dementia. *Brain* 1991;114:117-137.
31. Della Sala S, Laiacona M, Spinnler H, Trivelli C. Autobiographical recollection and frontal damage. *Neuropsychologia* 1993;31:823-839.
32. Hokkanen L, Launes J, Vataja R, Valanne L, Ivanainen M. Isolated retrograde amnesia for autobiographical material associated with acute left temporal lobe encephalitis. *Psychol Med* 1995;25:203-208.
33. Conway MA. A structural model of autobiographical memory. In: Conway MA, Rubin DC, Spinnler H, Wagenaar WA, eds. Theoretical perspectives on autobiographical memory. The Netherlands: Kluwer Academic Publishers, 1992:167-194.
34. Conway MA. Impairments of autobiographical memory. In: Spinnler H, Boller F, eds. Handbook of neuropsychology. Amsterdam: Elsevier, 1993:175-191.
35. Fink GR, Markowitsch HJ, Reinkemeier M, Bruckbauer T, Kessler J, Heiss WD. Cerebral representation of one's own past: neural networks involved in autobiographical memory. *J Neurosci* 1996;16:4275-4282.
36. Dalla Barba G, Cipolotti L, Denes G. Autobiographical memory loss and confabulation in Korsakoff's syndrome: a case report. *Cortex* 1990;26:525-534.
37. McCarthy RA, Warrington EK. Actors but not scripts: the dissociation of people and events in retrograde amnesia. *Neuropsychologia* 1992;30:633-644.
38. Hodges JR, McCarthy RA. Autobiographical amnesia resulting from bilateral paramedian thalamic infarction: a case study in cognitive neurobiology. *Brain* 1993;116:921-940.

39. Stracciari A, Ghidoni E, Guarino M, Poletti M, Pazzaglia P. Post-traumatic retrograde amnesia with selective impairment of autobiographical memory. *Cortex* 1994;30:459-468.
40. Lucchelli F, Muggia S, Spinnler H. The "Petites Madeleins" phenomenon in two amnesic patients. Sudden recovery of forgotten memories. *Brain* 1995;118:167-183.
41. Greene JDW, Hodges JR. The fractionation of remote memory. Evidence from a longitudinal study of dementia of Alzheimer type. *Brain* 1996;119:129-142.
42. Warrington EK. The selective impairment of semantic memory. *Q J Exp Psychol* 1975;27:635-657.
43. De Renzi E, Liotti M, Nichelli P. Semantic amnesia with preservation of autobiographic memory: a case report. *Cortex* 1987;23:575-597.

Correlations of flow velocity changes during mental activity and recovery from aphasia in ischemic stroke

M. Silvestrini, MD; E. Troisi, MD; M. Matteis, MD; C. Razzano, ST; and Carlo Caltagirone, MD

Article abstract—Mean flow velocity in the middle cerebral arteries (MCAs) during a rest period and during execution of a word-fluency task were measured by means of bilateral transcranial Doppler ultrasonography in 26 stroke patients with Broca's aphasia and in 25 healthy controls. Changes in flow velocity were calculated as percentage of increase from rest to mental activity. In patients, the evaluation was made within 21 days from onset of symptoms and after 2 months of speech therapy, when they were classified into two groups on the basis of extent of recovery from aphasia: absent or slight recovery (group 1, 10 patients) and good recovery (group 2, 16 patients). During the word-fluency task in the first evaluation, the increase in flow velocity in the left MCA was similar in controls and in group 2 patients. In both groups the increase was higher than in group 1 patients ($p < 0.0001$). Changes in mean flow velocity on the right side were slight and comparable in the three groups of study subjects. After speech therapy, group 1 patients showed a hemodynamic pattern on both sides similar to that observed in the first examination. In group 2 patients, comparison between values of the first and second evaluations showed that the increase of flow velocity in the left MCA was similar. On the right side, the increase was higher in the second than in the first examination ($p < 0.01$). These data further support the involvement of cerebral areas contralateral to the lesion in functional recovery after stroke. Moreover, the presence of an activation of areas in the lesioned hemisphere, soon after stroke onset, seems to be a predictor of recovery from aphasia.

NEUROLOGY 1998;50:191-195

Aphasia is a common and disabling symptom in stroke.¹ Early prediction of improvement is essential for planning the reintegration of patients into social life and their need for care and, more specifically, for selecting subjects who might benefit most from rehabilitation.^{2,3} Prognostic indicators have been widely investigated. There is considerable uncertainty about the role of patients' clinical characteristics,⁴ even if initial severity of the language disorder seems to be relevant.^{1,5} Some studies have provided indications about the importance of location and size of lesions evaluated with brain CT or MRI.⁶ However, morphologic examinations are not able to detect structural lesions at the cellular or synaptic level or functional changes in areas located in both the affected and contralateral hemispheres. In this respect, studies of cerebral metabolism and flow using PET have provided very interesting data about

the importance of residual functionality of structures in the dominant hemisphere^{7,8} and of early activation of areas in the unaffected hemisphere^{9,10} in the recovery from aphasia and other neurologic deficits. These functional data seem to be more reliable as early predictors of the outcome of stroke patients than the morphologic ones. Investigation techniques able to provide data on cerebral regional flow and metabolism are, however, too expensive and not widely available enough for routine use. With transcranial Doppler ultrasonography (TCD) it is possible to obtain information about changes in cerebral activity in both normal^{11,12} and pathologic conditions.¹³ Our aim in this study was to investigate the correlations between cerebral hemodynamics detected with TCD during mental activity requiring activation of the damaged area and clinical course of aphasia in patients after stroke.

From the Clinic of Neurology (Drs. Silvestrini and Caltagirone), "Tor Vergata" University of Rome; and IRCCS "S. Lucia" (Drs. Troisi, Matteis, Razzano, and Caltagirone), Rome, Italy.

Received December 24, 1996. Accepted in final form July 31, 1997.

Address correspondence and reprint requests to Dr. Mauro Silvestrini, Clinica Neurologica, Università di Roma "Tor Vergata," Ospedale S. Eugenio, P.le dell'Umanesimo 10, 00144 Roma, Italy.

Neurology[®]

Transient autobiographic amnesia: EEG and single-photon emission CT evidence of an organic etiology

Annalena Venneri and Paolo Caffarra

Neurology 1998;50;186-191

DOI 10.1212/WNL.50.1.186

This information is current as of January 1, 1998

Updated Information & Services	including high resolution figures, can be found at: http://www.neurology.org/content/50/1/186.full.html
References	This article cites 35 articles, 6 of which you can access for free at: http://www.neurology.org/content/50/1/186.full.html##ref-list-1
Citations	This article has been cited by 1 HighWire-hosted articles: http://www.neurology.org/content/50/1/186.full.html##otherarticles
Permissions & Licensing	Information about reproducing this article in parts (figures, tables) or in its entirety can be found online at: http://www.neurology.org/misc/about.xhtml#permissions
Reprints	Information about ordering reprints can be found online: http://www.neurology.org/misc/addir.xhtml#reprintsus

Neurology® is the official journal of the American Academy of Neurology. Published continuously since 1951, it is now a weekly with 48 issues per year. Copyright . All rights reserved. Print ISSN: 0028-3878. Online ISSN: 1526-632X.

