

8. Jackson MJ, Schaefer JA, Johnson MA, Morris AAM, Turnbull DM, Bindhoff LA. Presentation and clinical investigation of mitochondrial respiratory chain disease: a study of 51 patients. *Brain* 1995;118:339-357.
9. Ho VB, Fitz CR, Chuang SH, Geyer CA. Bilateral basal ganglia lesions: paediatric differential considerations. *Radiographics* 1993;13:269-292.
10. Kellermann K, Heuser L, Mertens T. Stammganglien-Enzephalitis nach Mumps. *Monatsschrift Kinderheilkunde* 1982;310:624-627.
11. Pettigrew LC, Jankovic J. Hemidystonia: a report of 22 patients and a review of the literature. *J Neurol Neurosurg Psychiatry* 1985;48:650-657.
12. Marsden CD, Obeso JA, Zarranz JJ, Lang AE. The anatomical basis of symptomatic hemidystonia. *Brain* 1985;108:463-483.

Focal Myoclonus Associated With Posterior Thalamic Hematoma



Lee and Marsden recently reviewed the reports of abnormal movements associated with focal lesions of the thalamus and subthalamic region.¹ The presence of myoclonic jerks was reported in a single case; however, negative myoclonus or acute asterixis occurred in 13 of 62 cases. They concluded that thalamic lesions, mainly those affecting the ventrolateral thalamus, may cause asterixis.¹

Lera et al. documented movement disorders with a complex dystonic pattern, choreic movements, and pseudorhythmic, slow, predominantly distal jerks in patients with lesions of the posterolateral area of the contralateral thalamus.² Ghika et al. described a syndrome they called "jerky dystonic unsteady hand," characterized by a delayed display of hyperkinetic features (dystonia, chorea, tremor, and myoclonus), associated with motor and sensory disorders in patients with posterior thalamic ischemia.³

We report a patient with a hemorrhagic lesion in the region of the posterior thalamic nucleus who developed a delayed form of complex myoclonus in the contralateral upper limb.

Case Report

A 68-year-old hypertensive woman suddenly developed weakness on her right side on July 18, 1992. Initial neurologic examination performed 6 h after onset showed her to be alert and oriented, with a right hemiparesis and hemihypesthesia. Deep tendon reflexes were symmetric, with a right extensor plantar response. Cranial nerves and visual fields were normal. No involuntary movements or ataxia were discerned. Clinical examination disclosed moderate hypertension. Laboratory findings, including blood count, erythrocyte sedimentation rate (ESR), and routine serum biochemistry, were normal. A computed tomographic scan of the brain showed a large cerebral

hematoma in the left posterior thalamic region, involving the posterior limb of the internal capsule. Hemiparesis and hemihypesthesia gradually improved. At the time of discharge, 20 days after onset, slight hemiparesis and hemihypesthesia persisted on the right side.

Six months later, the patient developed involuntary movements in her right arm. Neurologic examination disclosed facial hypomimia, a mild right hemiparesis with hyperreflexia, and hemihypesthesia. Rapid alternating movements of the hand were normal, with superimposed myoclonic jerks of variable amplitude and duration. Ataxia or dysmetria was difficult to exclude in the right arm because of superimposed involuntary movements, although the findings on heel-shin testing were normal and pathologic rebound was absent on the right side. The right arm displayed hyperkinetic involuntary movements, which were brief, sudden, non-stimulus-sensitive, with variable amplitude. These mainly involved the hand and were present at rest, during posturing, and with action. Rhythmic appearance at times suggested a rest tremor.

However, an electromyographic (EMG) recording at rest with needle electrodes disclosed irregular burst lengths of <300 ms (range, 50-200 ms) with synchronous activity of agonist and antagonist muscles (Fig. 1), without proximal EMG activity. At this time, the EMG recording with action excluded irregular brief lapses corresponding to asterixis. A polygraphic recording including electroencephalographic (EEG) tracing with electrodes placed on the left frontoparietal region failed to show a cortical component. Back averaging was not available at this time. Transcranial brain magnetic stimulation, performed using a coil centered over the vertex with surface electrode recording from thenar and anterior tibial muscles at rest

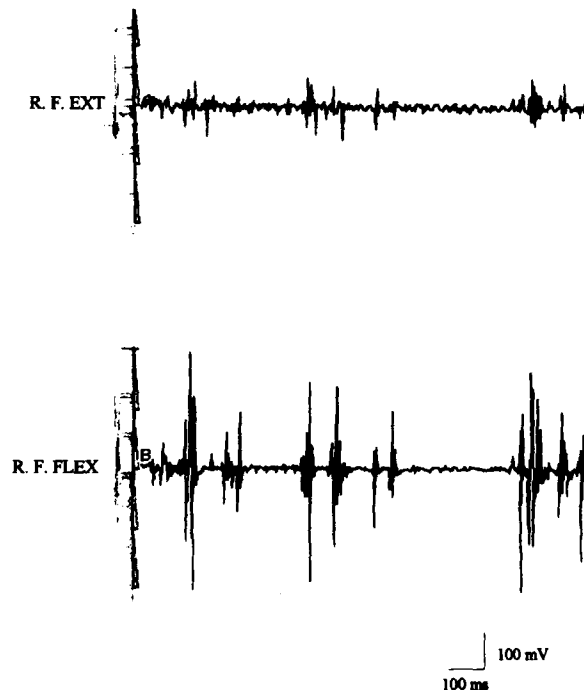


FIG. 1. Electromyographic recording of myoclonus at rest in right finger extensor and finger flexor muscles. The shortest electromyographic bursts are in the 50- to 250-ms range.

A videotape accompanies this article.

Received July 17, 1996; revisions received January 9 and May 28, 1997. Accepted May 30, 1997.

Address correspondence and reprint requests to Dr. E. M. Gatto at Sanatorio Mitre, Departamento de Neurología, Sanchez de Bustamante 2190, (1425) Buenos Aires, Argentina.

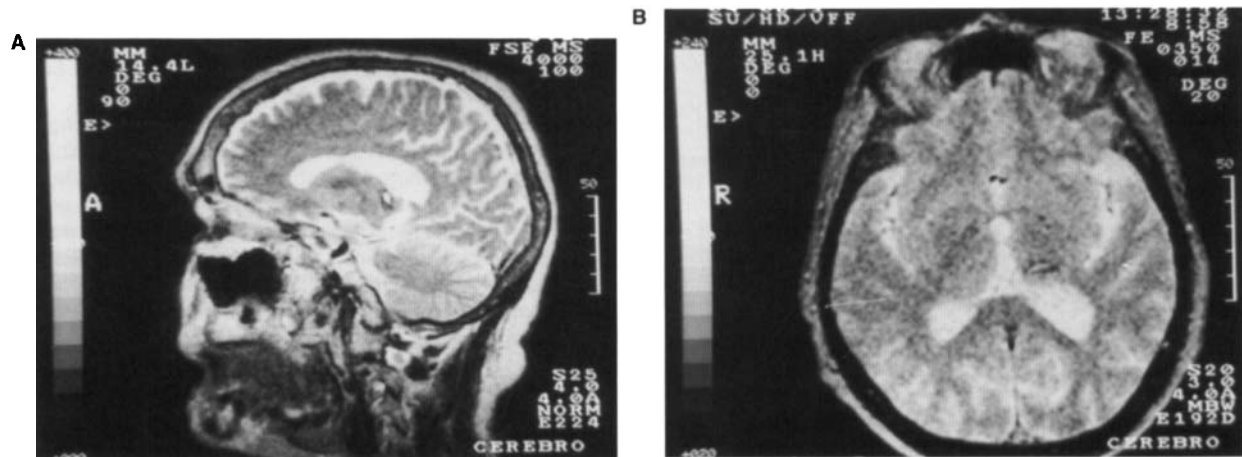


FIG. 2. (A) Sagittal section using T2-weighted magnetic resonance image (4000/100) showing sequela left posterior cerebral hematoma and hemosiderin findings, located in posterior thalamic nucleus. (B) Axial echo-gradient T2-weighted magnetic resonance image showing only paramagnetic hemoglobin-derived residue in the pulvinar region (350/14), according to Hassler's atlas.

and during voluntary contraction demonstrated normal motor-evoked potential latency, threshold, amplitude, and central motor conduction time. Magnetic resonance imaging (MRI) 2 and 4 years after the stroke disclosed a reabsorbing thalamic hematoma mostly involving the posterior or pulvinar nucleus (Fig. 2). The patient was treated with piracetam, clonazepam, valproic acid, and trihexiphenidyl, although without benefit.

Physical examination performed in March 1996 disclosed a moderate residual right hemiparesis, with partial recovery of superficial and deep sensory sensation, and myoclonus in the right arm at rest, enhanced during posture and action, with distal predominance (see the videotape). As before, it was difficult to exclude the presence of ataxia on the finger–nose test because of abnormal movements.

Discussion

Our patient presented with delayed-onset myoclonus after posterior thalamic hematoma.⁴ MRI performed 2 and 4 years after onset demonstrated a residual lesion primarily affecting the contralateral posterior thalamic nucleus.^{5–7}

Myoclonus has rarely been reported secondary to thalamic lesions, mainly described as following involvement of the ventrolateral nucleus or surrounding structures.¹ Paradoxically, ventrolateral thalamotomy has reportedly been useful in refractory essential myoclonus and myoclonic dystonia.⁸ Although the pathophysiological mechanism remains obscure, a probable loss of inhibitory influence of the internal globus pallidus and substantia nigra reticulata on the thalamus has been hypothesized.⁹ Furthermore, the delayed onset and progression imply that the syndrome could hardly be caused by the initial lesion itself, but rather by the development of postsynaptic supersensitivity or secondary reorganization of involved pathways.¹⁰ Lesions of the posterior thalamic nucleus have been related to a variety of delayed movement disorders, including tremor,¹¹ asterixis, myoclonus, and chorea.^{12,13} As in our case, frequent positive or negative myoclonus may mimic the appearance of tremor.¹⁴ In our patient, the EMG was consistent with a classification of hyperkinesia as myoclonus and excluded other types of abnormal movements such as “rubral” tremor (defined as a tremor of large amplitude, frequency of <4 Hz, and

arising from alternating contraction of antagonist muscle groups).¹⁵

Ghika et al. were the first to report a complex delayed hyperkinetic motor syndrome associated with Dejerine–Roussy syndrome, hemiataxia, and quadrantsia after a circumscribed thalamic lesion secondary to a posterior choroidal artery infarction.³ In our case, the hemorrhagic posterior thalamic nucleus lesion induced a delayed myoclonus with a mild hemiparesis and sensory disturbances. Such cases lend support to the hypothesis that the topographic distribution of the lesions within the thalamus are not uniform, making accurate clinicoanatomic correlation difficult.

Legend to the Videotape

This video shows a patient 2, 4, and 5 years after a posterior thalamic hematoma. At rest, a focal myoclonus was present mimicking tremor, which increased during action. An index-finger test was inconclusive in excluding ataxia, because of superimposed involuntary movements. Alternating movements and finger tapping were normal.

Emilia M. Gatto
 Maria C. Zurrú
 Carlos Rugilo
 Sanatorio Mitre
 Ana M. Pardal
 Manuel Martinez
 Manuel M. Fernandez Pardal
 British Hospital
 Buenos Aires
 Argentina

References

1. Lee MS, Marsden CD. Review: movement disorders following lesions of the thalamus or subthalamic region. *Mov Disord* 1994; 5:493–507.
2. Lera G, Scipioni O, García S, Fischbein G, Gershanik O. A peculiar pattern of movement disorders due to contralateral focal thalamic lesions [Abstract]. *Mov Disord* 1994;9(suppl 1):145.
3. Ghika J, Bogousslavsky J, Henderson J, Maeder P, Regli F. The

- 'jerky dystonic unsteady hand': a delayed motor syndrome in posterior thalamic infarctions. *J Neurol* 1994;241:537-542.
4. Obeso JA, Artieda J, Marsden CD. Different clinical presentations of myoclonus. In: Jankovic J, Tolosa E, eds. *Parkinson's disease and movement disorders*. Baltimore: Williams and Wilkins, 1993: 315-328.
 5. Steinke W, Sacco RL, Mohr JP, et al. Thalamic stroke: presentation and prognosis of infarcts and hemorrhages. *Arch Neurol* 1992; 49:703-710.
 6. Bogousslavsky J, Regli F, Uske A. Thalamic infarcts: clinical syndromes, etiology and prognosis. *Neurology* 1988;38:837-848.
 7. Lehermy S, Vidailhet M, Dormont D, et al. Striatopallidal and thalamic dystonia: a magnetic resonance imaging anatomoclinical study. *Arch Neurol* 1996;53:241-250.
 8. Segawa M. Pathophysiologies of dystonia and myoclonus: consideration from the standpoint of treatment. *Rinsho Shinkeigaku* 1995; 35:1390-1393.
 9. Miwa H, Hatori K, Kondo T, Imai H, Mizuno Y. Thalamic tremor: case reports and implications of the tremor-generating mechanism. *Neurology* 1996;46:75-79.
 10. Louis DE, Lynch T, Ford B, Greene P, Bressman SB, Fahn S. Delayed-onset cerebellar syndrome. *Arch Neurol* 1996;53:450-454.
 11. Kim JS. Delayed onset hand tremor caused by cerebral infarction. *Stroke* 1992;23:292-294.
 12. Donat JR. Unilateral asterixis due to thalamic hemorrhage. *Neurology* 1980;30:83-84.
 13. Milandre L, Brosset C, Gabriel B, Khalil R. Mouvements involontaires transitoires et infarctus thalamiques. *Rev Neurol (Paris)* 1993;149:402-406.
 14. Hallett M. Electrophysiologic evaluation of tremor and central disorders of movements. In: Aminoff MJ, ed. *Electrodiagnosis in clinical neurology*. 2nd ed. New York: Churchill Livingstone, 1986:385-401.
 15. Deuschl G, Krack P, Lauk M, Timmer J. Clinical neurophysiology of tremor. *J Clin Neurophysiol* 1996;13:110-121.

Abrupt Onset of Transient Pseudochoreoathetosis Associated With Proprioceptive Sensory Loss as a Result of a Thalamic Infarction



The most common movement disorder following a focal lesion in the thalamus has been a delayed onset of hemidystonia, usually involving the distal part of the limbs. The most common lesion responsible for this has been described as being a vascular lesion in the posterolateral part of the thalamus,¹ which is supplied by the thalamogeniculate artery originating from the posterior cerebral artery (PCA).^{2,3}

Obstruction of the PCA proximal to the origin of the thalamogeniculate artery may cause posterolateral thalamic, temporal, and occipital infarction.^{2,3} However, in a recent review

of movement disorders following a focal lesion of the thalamus, only a few patients with delayed-onset movement disorders following thalamic and occipital infarction caused by PCA obstruction have been identified.¹⁻⁴

We describe the case of a 41-year-old woman who developed a sudden onset of left hemisensory loss, hemianopia, and hemichoreoathetosis resulting from right posterolateral thalamic, temporal, and occipital infarction. She had no motor weakness. As the proprioceptive sensory disturbance improved, the involuntary movement disappeared. These findings may suggest that intact pyramidal tract and transient abnormal proprioceptive sensory inputs to the motor control system caused the abrupt onset of transient pseudochoreoathetosis seen in our patient.

Case History

A 41-year-old woman developed a sudden onset of stroke 9 h after an uneventful operation to remove creases from her forehead. The stroke began with left hemisensory disturbances and choreoathetoid movements of her left arm and leg. She lost her fine manual skills and was unable to stand or walk.

Her blood pressure was normal. She did not have a cardiac murmur or arrhythmia. Neurologic examination disclosed a left homonymous hemianopia and a full range of eye movement without nystagmus. She had no facial weakness. While lying down, she had athetoid movements in the distal part of her left arm and leg. While sitting, her left arm shook at times. While she stretched out both hands to the front, choreic movements of her left arm were enhanced to involve the proximal part. Her left arm was affected more severely than her leg, but her face was spared (videotape segment 1). She could not suppress the involuntary movements by mental concentration. The fine finger movements of her left hand were clumsy. Her muscle tone was normal. On manual motor tests, she had no motor weakness in any of her limbs. Her tendon reflexes were hyperactive on the left side, and her left plantar reflex was equivocal.

Sensory examination revealed complete absence of joint position sense, vibration sense, and light-touch sense over the left side of her body. The pain sense over the left side of her body was decreased to approximately half that of the right side. Because of the involuntary movements, cerebellar function tests were difficult to assess. The results of routine laboratory examinations were normal. Prolonged electrocardiographic monitoring and echocardiography showed no abnormalities. The results of a serum lupus anticoagulant test and antiphospholipid antibody test were normal, as were those of a serum anticardiolipin antibody test. The findings of antinuclear antibody, anti-DNA, and LE cell tests were normal, as were the results of anti-Ro and anti-La tests.

A T2-weighted brain magnetic resonance imaging study showed high-signal-intensity lesions at the right posterolateral thalamus and temporo-occipital lobe (Fig. 1). A magnetic resonance cerebral angiographic study showed an obstruction at the proximal part of the right PCA. As the sensory disturbances improved over a period of 3 months, the involuntary movements changed to a fixed dystonia involving distal parts of her left hand. Around that time, she resumed independent walking.

At the follow-up examination 6 months after the onset of the stroke, her position and light-touch sense had returned to normal. She had hypalgesia over the left side of her body and decreased vibration sense on the left medial malleolus. While

A videotape accompanies this article.

Received September 3, 1996; revision received February 20, 1997. Accepted February 25, 1997.

Address correspondence and reprint requests to Dr. M. S. Lee at Department of Neurology, Youngdong Severance Hospital, Yonsei University College of Medicine, 146-92 Dogok-dong, Kangnam-koo, Seoul, South Korea.