

- 'jerky dystonic unsteady hand': a delayed motor syndrome in posterior thalamic infarctions. *J Neurol* 1994;241:537-542.
4. Obeso JA, Artieda J, Marsden CD. Different clinical presentations of myoclonus. In: Jankovic J, Tolosa E, eds. *Parkinson's disease and movement disorders*. Baltimore: Williams and Wilkins, 1993: 315-328.
  5. Steinke W, Sacco RL, Mohr JP, et al. Thalamic stroke: presentation and prognosis of infarcts and hemorrhages. *Arch Neurol* 1992; 49:703-710.
  6. Bogousslavsky J, Regli F, Uske A. Thalamic infarcts: clinical syndromes, etiology and prognosis. *Neurology* 1988;38:837-848.
  7. Lehermy S, Vidailhet M, Dormont D, et al. Striatopallidal and thalamic dystonia: a magnetic resonance imaging anatomoclinical study. *Arch Neurol* 1996;53:241-250.
  8. Segawa M. Pathophysiologies of dystonia and myoclonus: consideration from the standpoint of treatment. *Rinsho Shinkeigaku* 1995; 35:1390-1393.
  9. Miwa H, Hatori K, Kondo T, Imai H, Mizuno Y. Thalamic tremor: case reports and implications of the tremor-generating mechanism. *Neurology* 1996;46:75-79.
  10. Louis DE, Lynch T, Ford B, Greene P, Bressman SB, Fahn S. Delayed-onset cerebellar syndrome. *Arch Neurol* 1996;53:450-454.
  11. Kim JS. Delayed onset hand tremor caused by cerebral infarction. *Stroke* 1992;23:292-294.
  12. Donat JR. Unilateral asterixis due to thalamic hemorrhage. *Neurology* 1980;30:83-84.
  13. Milandre L, Brosset C, Gabriel B, Khalil R. Mouvements involontaires transitoires et infarctus thalamiques. *Rev Neurol (Paris)* 1993;149:402-406.
  14. Hallett M. Electrophysiologic evaluation of tremor and central disorders of movements. In: Aminoff MJ, ed. *Electrodiagnosis in clinical neurology*. 2nd ed. New York: Churchill Livingstone, 1986:385-401.
  15. Deuschl G, Krack P, Lauk M, Timmer J. Clinical neurophysiology of tremor. *J Clin Neurophysiol* 1996;13:110-121.

### Abrupt Onset of Transient Pseudochoreoathetosis Associated With Proprioceptive Sensory Loss as a Result of a Thalamic Infarction



The most common movement disorder following a focal lesion in the thalamus has been a delayed onset of hemidystonia, usually involving the distal part of the limbs. The most common lesion responsible for this has been described as being a vascular lesion in the posterolateral part of the thalamus,<sup>1</sup> which is supplied by the thalamogeniculate artery originating from the posterior cerebral artery (PCA).<sup>2,3</sup>

Obstruction of the PCA proximal to the origin of the thalamogeniculate artery may cause posterolateral thalamic, temporal, and occipital infarction.<sup>2,3</sup> However, in a recent review

of movement disorders following a focal lesion of the thalamus, only a few patients with delayed-onset movement disorders following thalamic and occipital infarction caused by PCA obstruction have been identified.<sup>1-4</sup>

We describe the case of a 41-year-old woman who developed a sudden onset of left hemisensory loss, hemianopia, and hemichoreoathetosis resulting from right posterolateral thalamic, temporal, and occipital infarction. She had no motor weakness. As the proprioceptive sensory disturbance improved, the involuntary movement disappeared. These findings may suggest that intact pyramidal tract and transient abnormal proprioceptive sensory inputs to the motor control system caused the abrupt onset of transient pseudochoreoathetosis seen in our patient.

### Case History

A 41-year-old woman developed a sudden onset of stroke 9 h after an uneventful operation to remove creases from her forehead. The stroke began with left hemisensory disturbances and choreoathetoid movements of her left arm and leg. She lost her fine manual skills and was unable to stand or walk.

Her blood pressure was normal. She did not have a cardiac murmur or arrhythmia. Neurologic examination disclosed a left homonymous hemianopia and a full range of eye movement without nystagmus. She had no facial weakness. While lying down, she had athetoid movements in the distal part of her left arm and leg. While sitting, her left arm shook at times. While she stretched out both hands to the front, choreic movements of her left arm were enhanced to involve the proximal part. Her left arm was affected more severely than her leg, but her face was spared (videotape segment 1). She could not suppress the involuntary movements by mental concentration. The fine finger movements of her left hand were clumsy. Her muscle tone was normal. On manual motor tests, she had no motor weakness in any of her limbs. Her tendon reflexes were hyperactive on the left side, and her left plantar reflex was equivocal.

Sensory examination revealed complete absence of joint position sense, vibration sense, and light-touch sense over the left side of her body. The pain sense over the left side of her body was decreased to approximately half that of the right side. Because of the involuntary movements, cerebellar function tests were difficult to assess. The results of routine laboratory examinations were normal. Prolonged electrocardiographic monitoring and echocardiography showed no abnormalities. The results of a serum lupus anticoagulant test and antiphospholipid antibody test were normal, as were those of a serum anticardiolipin antibody test. The findings of antinuclear antibody, anti-DNA, and LE cell tests were normal, as were the results of anti-Ro and anti-La tests.

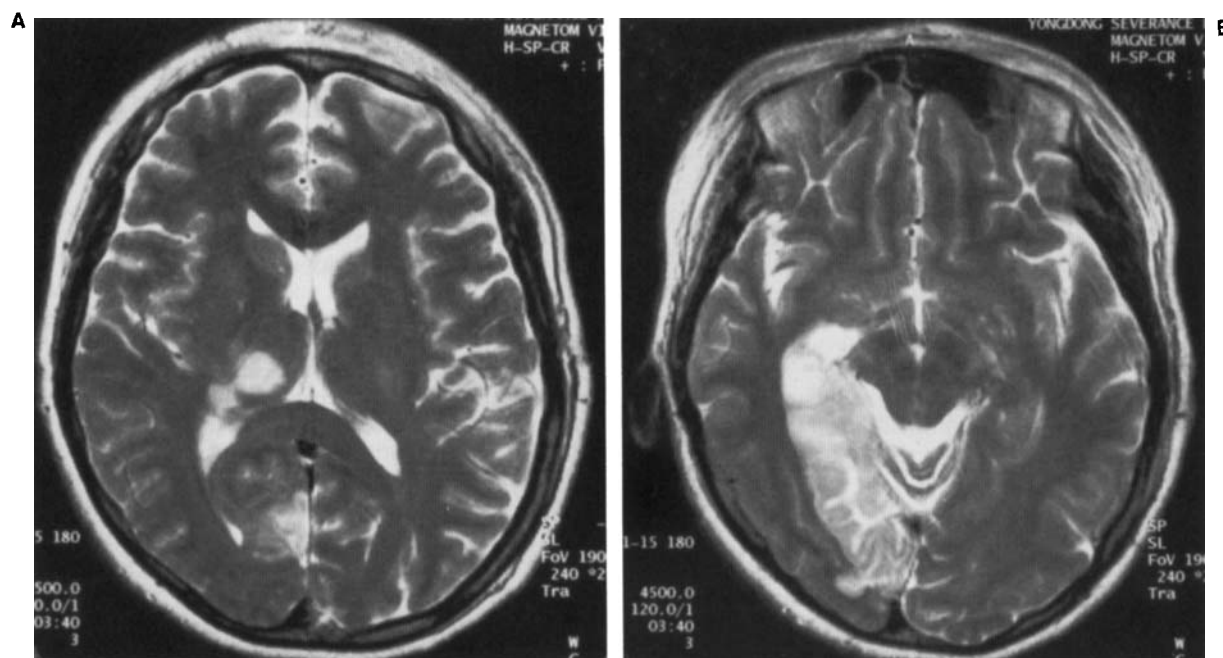
A T2-weighted brain magnetic resonance imaging study showed high-signal-intensity lesions at the right posterolateral thalamus and temporo-occipital lobe (Fig. 1). A magnetic resonance cerebral angiographic study showed an obstruction at the proximal part of the right PCA. As the sensory disturbances improved over a period of 3 months, the involuntary movements changed to a fixed dystonia involving distal parts of her left hand. Around that time, she resumed independent walking.

At the follow-up examination 6 months after the onset of the stroke, her position and light-touch sense had returned to normal. She had hypalgesia over the left side of her body and decreased vibration sense on the left medial malleolus. While

A videotape accompanies this article.

Received September 3, 1996; revision received February 20, 1997. Accepted February 25, 1997.

Address correspondence and reprint requests to Dr. M. S. Lee at Department of Neurology, Youngdong Severance Hospital, Yonsei University College of Medicine, 146-92 Dogok-dong, Kangnam-koo, Seoul, South Korea.



**FIG. 1.** A T2-weighted axial magnetic resonance imaging scan of the brain shows high-signal-intensity lesions at the posterolateral part of the right thalamus (A) and temporal and occipital lobe (B).

walking, sitting, and stretching out both hands in front of her, there was no choreoathetoid movement (videotape segment 2).

### Discussion

A thalamic lacunar infarction resulting from an arteriosclerotic thrombosis of a single penetrating artery gives rise to a variety of clinical syndromes such as a pure sensory stroke, ataxic hemiparesis, painful ataxic hemiparesis, ataxic crural paresis, and hypesthesia-ataxia-hemiparesis.<sup>5,6</sup> Fisher<sup>5</sup> included acute dystonia as a form of thalamic lacunar syndrome. However, acute dystonia is a rare consequence of thalamic lacunar infarction.<sup>1</sup>

The extent of the lesion described in the original report by Dejerine and Roussy<sup>7</sup> was larger than the size of a lacuna. The size of a lacuna after an obstruction of a single penetrating branch of the thalamogeniculate artery is too small to inflict major damage to the dispersed pallidal, cerebellar, and somatosensory thalamic afferent tracts. These observations support the argument that the PCA occlusion, which may cause an infarction in the area of the several thalamogeniculate artery branches, is the main cause of the thalamic syndrome.<sup>8</sup>

PCA obstruction proximal to the origin of the thalamogeniculate artery causes posterolateral thalamic infarction, and in some cases is accompanied by temporal and occipital infarction (typical thalamic syndrome). The temporal and occipital lobes may be spared if there are well-developed leptomeningeal collaterals from the middle cerebral artery (pure thalamic syndrome).<sup>2,3</sup> In patients with typical thalamic syndrome, temporal and occipital lobe infarction may lead to a contralateral hemianopia and, with left-sided lesions, additional alexia and/or Wernicke's aphasia.

An infarction in the area of thalamogeniculate artery may

involve ventral posteromedial and ventral posterolateral thalamic nuclei, which contain the main terminals of the fibers of the spinothalamic tract, trigeminothalamic tract, and medial lemniscus. Only a portion of the fibers of the posterior limb of the internal capsule is involved. The posterior portion of the lenticular nucleus and the pallidothalamic, cerebellothalamic, and subthalamic connections may also be involved.

The typical and pure thalamic syndrome following such lesions can be characterized by a persistent superficial hemianesthesia with deep sensory disturbances, recoverable hemiparesis, and mild hemiataxia. After a delay, some patients develop spontaneous thalamic pain or athetoid movements, predominantly involving distal parts of the arm.<sup>7,9</sup>

However, movement disorders after posterolateral thalamic, temporal, and occipital infarction (typical thalamic syndrome) have been rarely mentioned.<sup>1</sup> Martin<sup>4</sup> reported the case of a patient who developed persistent hemiballism and hemichorea 3 months after a hemiplegia. An autopsy revealed thrombosis at the PCA in the portion lying posterolateral to the midbrain, with extensive infarction of the occipital lobe and the lateral thalamus. Microscopic examination revealed degeneration of the fibers passing across the internal capsule and the subthalamic area that connects the subthalamic nucleus and the pallidum.

A magnetic resonance imaging scan of our patient's brain showed right posterolateral thalamic, temporal, and occipital infarction. A magnetic resonance cerebral angiographic study showed an obstruction at the proximal part of the right PCA.<sup>2-4</sup> However, our patient had no hemiparesis and developed choreoathetoid movements abruptly as an initial manifestation of the stroke. Interestingly, as the proprioceptive sensory disturbance improved, choreoathetoid movements disappeared.

The mechanisms responsible for the unusual clinical features seen in our patient are difficult to decipher. Abnormal thalamocortical neuronal inputs resulted from the damage to the subthalamic connections or to the thalamic afferent fibers from the globus pallidus or cerebellum may have caused the choreo-athetoid movements seen in our patient.<sup>1</sup> However, the clinical course of our patient suggests a close relationship between the involuntary movement and abnormal proprioceptive sensation. Sharp et al.<sup>10</sup> reported the cases of seven patients who developed pseudochoreoathetosis and proprioceptive sensory loss resulting from a lesion in the parietal lobe, thalamus, spinal cord, or peripheral nerve. The authors postulated that the loss of proprioception causes alterations in cortical sensory inputs to the striatum, striatal dysfunction, and finally variable mixtures of athetosis, chorea, and dystonia. Still unknown, however, is why only a small proportion of patients with proprioceptive sensory loss develop such involuntary movements.

### Legends to the Videotape

**Segment 1.** This 41 year-old woman has athetoid movements involving distal parts of her left arm. While sitting, she at times has choreic movements of her left arm. Maintaining the posture of her arms enhances the athetoid movements of her left hand and increases the amplitude of choreic movements of her left arm.

**Segment 2.** Six months after the onset of the stroke, the patient shows marked improvement in the choreoathetoid movements while maintaining the posture of her arms.

Myung Sik Lee  
Young Duk Kim  
Jeong Taek Kim  
Chul Hyung Lyoo

Department of Neurology  
Yonsei Brain Research Center  
Yongdong Severance Hospital  
Yonsei University College of Medicine  
Seoul  
South Korea

### References

1. Lee MS, Marsden CD. Movement disorders following lesions of the thalamus or subthalamic region. *Mov Disord* 1994;9:493-507.
2. Foix C, Masson A. Le syndrome de l'artère cérébrale postérieure. *Presse Med* 1923;31:361-365.
3. Foix C, Hillemand P. Les syndromes de la région thalamique. *Presse Med* 1925;33:113-117.
4. Martin JP. Hemichorea (hemiballism) without lesions in the corpus Luysii. *Brain* 1957;80:1-12.
5. Fisher CM. Lacunar strokes and infarcts: a review. *Neurology* 1982;32:871-876.
6. Mohr JP. Lacunes. *Stroke* 1982;13:3-11.
7. Dejerine J, Roussy G. Le syndrome thalamique. *Rev Neurol (Paris)* 1906;14:521-531.
8. Caplan LR, Dewitt LD, Pessin MS, Gorelick PB, Adelman LS. Lateral thalamic infarcts. *Arch Neurol* 1988;45:959-964.
9. Martin JJ. Thalamic syndromes. In: Vinken PJ, Bruyn GW, eds. *Handbook of clinical neurology*, vol 2 (Localization in Clinical Neurology). Amsterdam: North-Holland, 1969:469-496.
10. Sharp FR, Rando TA, Greenberg SA, Brown L, Sagar SM. Pseudochoreoathetosis: movements associated with loss of proprioception. *Arch Neurol* 1994;51:1103-1109.

## Bibrachial Sensory Athetosis and Dystonia in Delayed Postirradiation Myelopathy



Radiation injury to the spinal cord may cause transient<sup>1</sup> or permanent<sup>2</sup> myelopathy. The association of delayed postirradiation cervical myelopathy in a 63-year-old woman with bibrachial sensory athetosis and dystonia of both hands is reported. This is probably the result of loss of proprioception in the arms as a result of "radiation vasculomyelinopathy" involving bilateral fasciculus cuneatus with relative sparing of the medially located fasciculus gracilis. The involuntary movements were ameliorated after short-term therapy with corticosteroids and warfarin. Serial magnetic resonance imaging (MRI) of the cervical cord showed sequential changes from myeloedema with ring-enhancing lesion to eventual cervical cord atrophy.

### Case Report

A 63-year-old woman was healthy until 1992 when she noticed a nodule on the right side of her neck. Biopsy of the right cervical lymph nodes and a nasopharyngeal tumor confirmed an anaplastic carcinoma of the nasopharynx. A total dose of 76 Gy/56 fractions of gamma ray irradiation to the nasopharynx and to the neck resulted in complete remission. In January 1995, she had a "girdle sensation" around the umbilicus, numbness of the legs, and gait unsteadiness when walking in a dark room. Ascending numbness, involuntary movements of the arms, constipation, and urinary retention brought her to our attention. Examinations revealed that she had high blood pressure ranging from 140 to 200 mm Hg systolic and 90 to 110 mm Hg diastolic. The sensory deficits extended from both feet to the C4 level. Proprioception was most severely affected. Crude touch, pain, and thermal sensations were also impaired to a lesser degree. Romberg sign was positive. Tendon jerks were brisk in all limbs. Babinski sign was absent, and higher cortical functions remained normal. Limb coordination, including finger-to-nose test, heel-to-knee test, and tandem gait could be accomplished only by visual compensation in a well-illuminated room. Both hands showed writhing movements of the fingers (athetosis) and bibrachial dystonia with posture holding and on attempted volitional movements. While she was writing with one hand, "overflow phenomenon" was noted in the other hand. Athetosis and dystonia were exaggerated when both arms were kept outstretched with the eyes closed. By visual cue, athetosis was ameliorated; however, hand dystonia remained. Writing was especially difficult with the eyes closed. MRI of the cervical cord showed a long segment of cervical cord edema (myeloedema) and a ring-enhancing lesion extending from C2 to C4 segments (Fig. 1A and B). MRI of the brain and chest radiograph were unremarkable. Cerebrospinal fluid

A videotape segment accompanies this article.

Received September 20, 1996; revisions received February 20 and June 23, 1997. Accepted June 24, 1997.

Address correspondence and reprint requests to Dr. P. Thajeb at P.O. Box 54-20, Section of Neurology, Cathay General Hospital, 280, Sect. 4 Jen Ai Road, Taipei, Taiwan, ROC.