

Karl-Olof Lövblad  
Pramod Kelkar  
Christoph Ozdoba  
Gianpaolo Ramelli  
Luca Remonda  
Gerhard Schroth

## Pure methotrexate encephalopathy presenting with seizures: CT and MRI features

Received: 23 June 1997  
Accepted: 8 September 1997

K-O. Lövblad (✉) · P. Kelkar · C. Ozdoba  
L. Remonda · G. Schroth  
Department of Neuroradiology,  
Institute of Diagnostic Radiology,  
Inselspital, University of Bern,  
CH-3010 Bern, Switzerland

G. Ramelli  
Department of Pediatrics, Inselspital,  
University of Bern, Bern, Switzerland

**Abstract** With the advent of chemotherapy, mortality rates in acute lymphoblastic leukaemia (ALL) have decreased, but complications in the central nervous system have appeared. These include direct involvement of the brain itself and the development of chemotherapy-related encephalopathy as a delayed reaction. In most reported cases, this encephalopathy is believed to be due to necrotising angiitis arising from the combination of chemotherapy with adjuvant radiotherapy. We report the cases of four children with ALL who had been treated with high-dose intravenous and intrathecal chemotherapy but no radiation therapy, and who were admitted to hospital because of sei-

zures. CT of the brain revealed the presence of diffuse periventricular white matter hypodensities in all cases and subcortical hyperdense foci in three cases. MRI showed diffuse hyperintense white matter lesions on T2-weighted images in all four patients; hypointense changes were observed on susceptibility-sensitive FLASH sequences in the hyperdense foci seen on CT as well as changes that were hyperintense on T1-weighted images. It was, therefore, concluded that the lesions corresponded to a leukoencephalopathy with calcific deposits. These findings are of a pure form of methotrexate encephalopathy causing seizures.

### Introduction

Acute lymphoblastic leukaemia (ALL) is the most common malignancy in childhood. Before the advent of modern chemotherapeutic agents, the prognosis was bleak with a survival rate of only a few months. With the advent of current chemotherapeutic regimes, survival has increased and up to 60% of patients are considered to be cured. Primary central nervous involvement is uncommon, with only 5% of children being thus affected [1]. Without adequate prophylaxis, however, a majority of patients will eventually develop involvement of the central nervous system. This might be due to the sanctuary created by the blood-brain barrier, which effectively prevents chemotherapeutic agents from reaching this area [1]. Therefore, central nervous system prophylaxis has a central place

in the treatment of ALL [2]. It can involve intrathecal administration of chemotherapeutic agents (such as methotrexate), radiation therapy to the neuraxis, or a combination of both, as well as high doses of systemically administered drugs. Abnormalities on CT of the brain are known to occur in some of these patients [3–5]. One such abnormality is the presence of cerebral subcortical calcifications associated with methotrexate leukoencephalopathy [6–8]. Changes on MRI have been reported to occur in 0–51% of cases [9–13]. These findings have been said to be due to vasculitis produced by the combination of chemotherapy and radiation therapy [14]. We report the neuroimaging features in four children with ALL who had been treated with intrathecal methotrexate and who were referred acutely for neuroimaging because of seizures.

## Materials and methods

All four patients had been treated according to the same protocol when they presented with seizures requiring neuroimaging. The therapy they had undergone consisted of high-dosage intravenous methotrexate ( $2.5 \text{ g/m}^2/24 \text{ h}$ ) in combination with intrathecal triple therapy (methotrexate, hydrocortisone and Ara-C).

Each of the four patients had CT of the brain (Highlight Advantage scanner; General Electric Corporation, Milwaukee, Wis.) using contiguous 5-mm sections acquired in the axial plane parallel to the cantho-meatal line with a matrix of  $512 \times 512$  before and after intravenous contrast medium administration. MRI was performed on a 1.5-T Magnetom Vision system (Siemens, Erlangen, Germany); T1-weighted, T2-weighted and proton density scans were acquired in the axial plane; T2-weighted images were also acquired in the coronal plane; in addition, T2-weighted fast low angle shot (FLASH) images were acquired in the axial plane. All scans employed a  $256 \times 256$  matrix with 5-mm-thick slices. Finally, T1-weighted images were acquired in the coronal, axial and sagittal planes after intravenous administration of Gd-DTPA.

## Case histories

### Case 1

A 3-year-old boy with common ALL since the age of 2 years and without primary involvement of the CNS was in remission at the time of admission. He had been treated with methotrexate for about a year and had received the last dose of chemotherapy 10 days prior to admission. On the day of his admission, he had multiple petit mal fits before developing a fit which progressed to grand mal status.

CT of the brain revealed multiple bilateral subcortical calcifications in the frontal and temporal areas which showed slight enhancement after contrast medium administration (Fig. 1 a). There were also diffuse hypodense areas in the deep cerebral white matter. MRI showed signs of diffuse leukoencephalopathy with the presence, on T2-weighted images, of diffuse hyperintensities in the cerebral white matter (Fig. 1 b). Repeat MRI 3 months later revealed a slight change in the extent of the white matter changes (Fig. 1 c); subcortical hyperintensities were now visible on T1-weighted images (Fig. 1 d). On the T2-weighted FLASH sequence, it was possible to see discrete hypointensities in the areas of the calcifications noted on CT (Fig. 1 e). The calcification pattern was clearly located subcortically along the U-fibres (Fig. 1 f.g).

### Case 2

A 5-year-old girl with common ALL since the age of 3 years and without involvement of the CNS had been treated with methotrexate for 15 months. Her growth had become slightly retarded and she had developed mild osteopenia. She was considered to be in remission when she was admitted because of a focal leftsided convulsion which had been preceded by multiple petit mal fits.

CT revealed calcifications in both frontal and parietal lobes, as well as in the right temporal and occipital lobes (Fig. 2 a). There was also a calcification in the basal ganglia on the right side. MRI showed, in the same locations, hyperintensities on T1-weighted images (Fig. 2 b). The lesions were located in the U-fibres. After intravenous administration of contrast medium, the lesions enhanced diffusely (Fig. 2 c,d). There were also diffuse hyperintensities in the white matter on T2-weighted images.

Repeat MRI 2 months later showed a marked progression of the white matter changes; both the diffuse periventricular changes with T2 and the subcortical changes with T1 weighting were shown to have changed over time, demonstrating the active nature of the process.

### Case 3

A 3-year-old boy with pre-B ALL since the age of 2 years and without involvement of the CNS had received chemotherapy with methotrexate and was considered in remission at the time of his hospitalisation. He had suddenly become ill, cried, vomited and became unconscious.

CT of the brain revealed a single calcification in the parieto-occipital region of the right hemisphere. MRI showed discrete changes in the parieto-occipital region consisting of diffuse hyperintensities in the white matter on T2-weighted images.

### Case 4

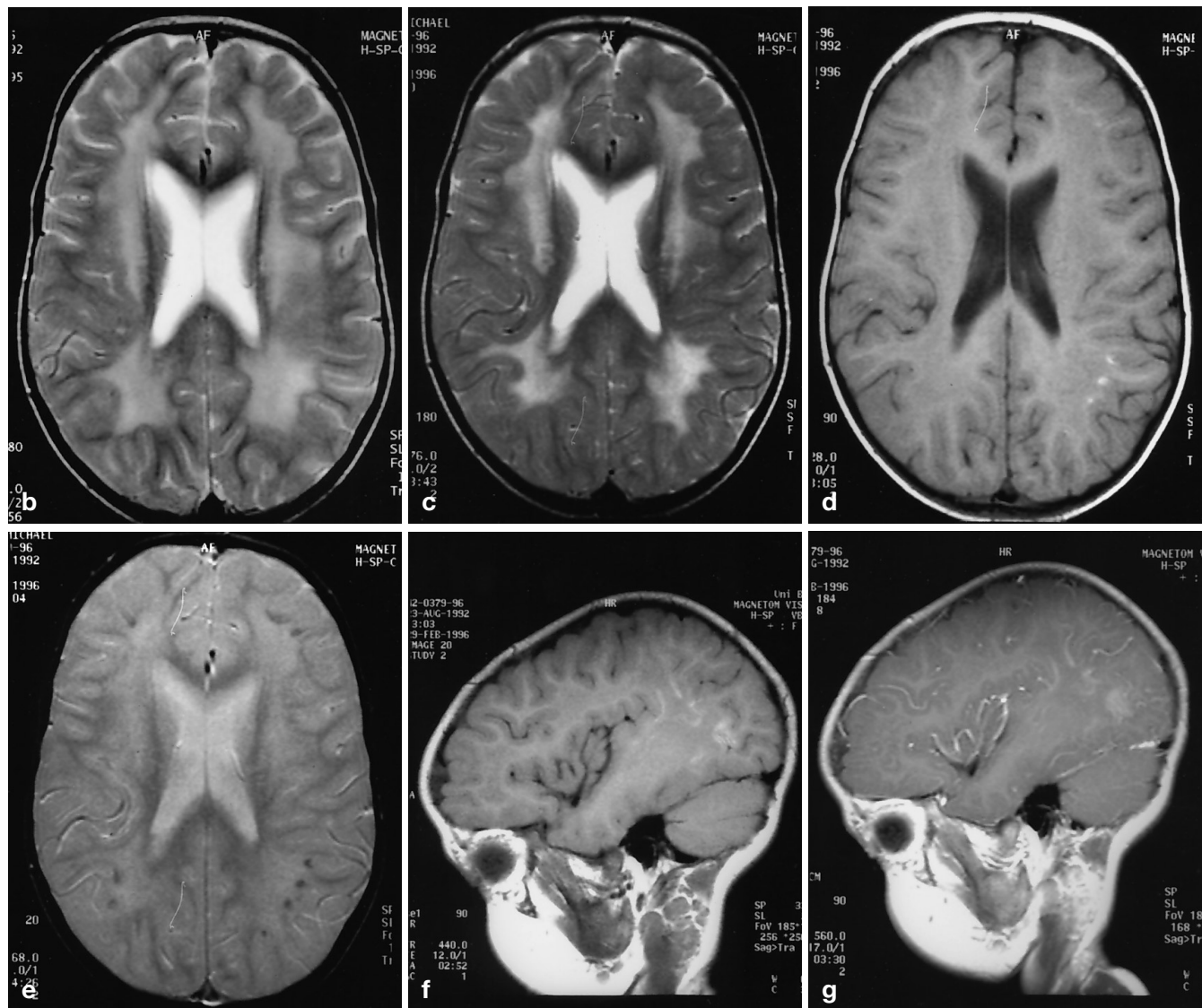
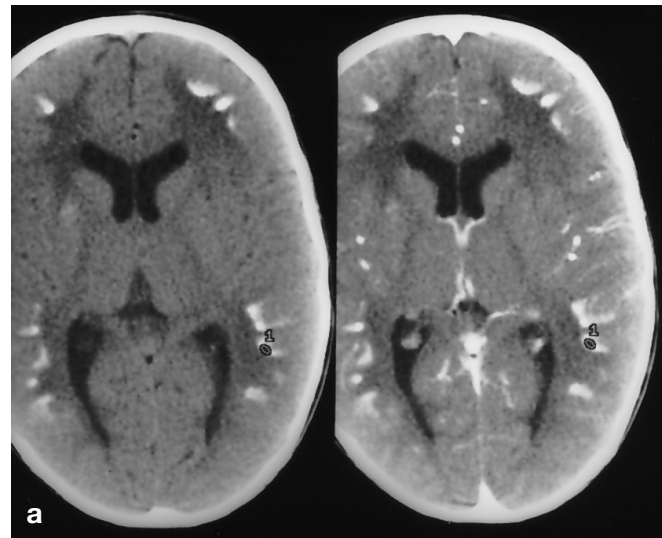
A 5-year-old boy had pre-B ALL. A CT scan had been performed at the age of 2 years and had been considered normal. He suffered a thrombosis of the sigmoid and transverse sinuses on the left side 12 months prior to his current hospitalisation. An MRI had been performed at the time of the thrombosis of the sigmoid sinus, and follow-up examinations had shown the affected sinuses to have recanalised almost completely with only slight vessel wall irregularities still being present. The white matter at that time was normal. MRI at the time of admission showed diffuse hyperintensities in the deep periventricular white matter on T2-weighted imaging. There were no signal abnormalities on the FLASH images that would suggest the presence of calcification.

## Discussion

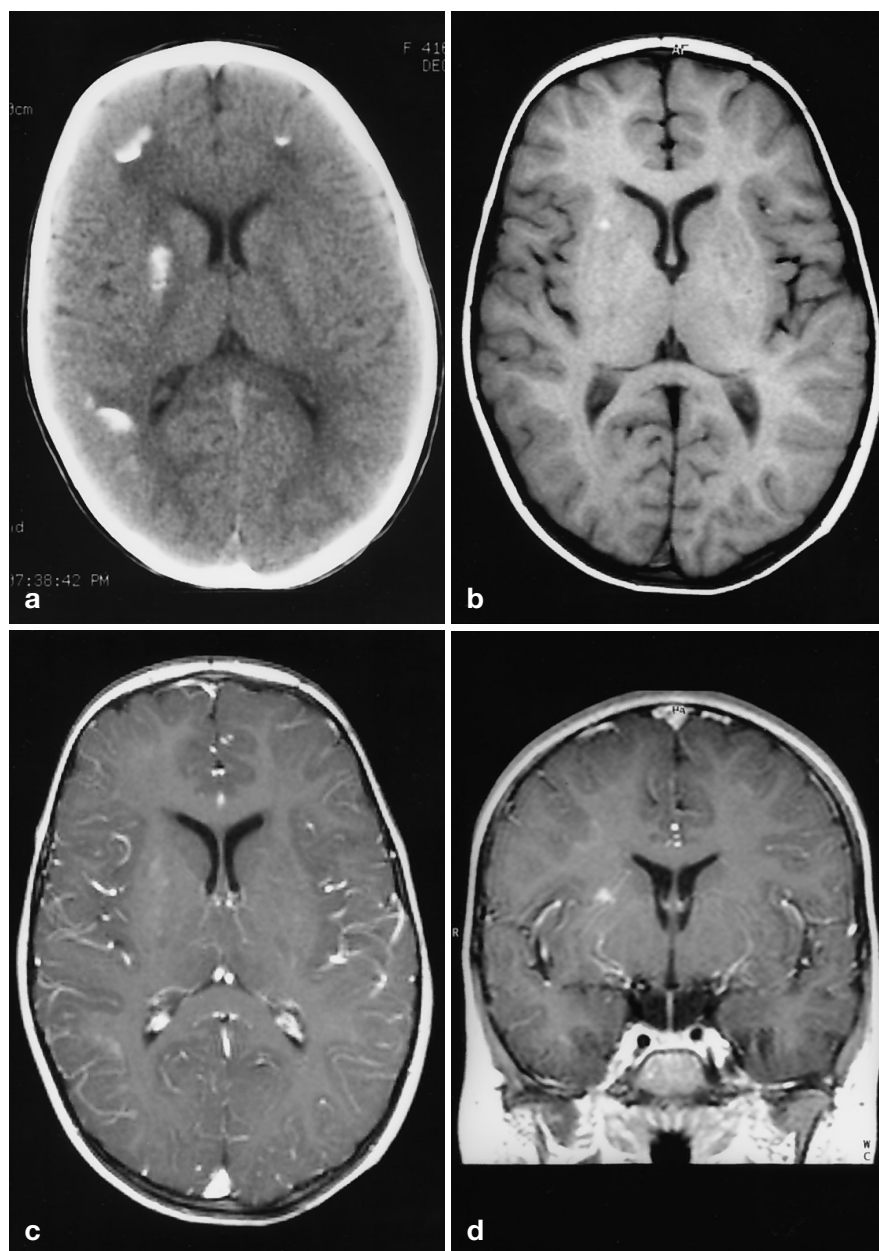
With the advent of modern chemotherapeutic agents, the prognosis of children with ALL has changed dramatically; however, the decrease in mortality has been accompanied by an increase in involvement of the central nervous system. Therefore, prophylaxis which includes irradiation and intrathecal chemotherapy is now commonplace. We have reported four cases of cerebral calcification associated with ALL and high-dose chemotherapy in young children but no adjuvant radiotherapy. The findings correspond to those described in methotrexate leukoencephalopathy [3–7]. Although this classically occurs in patients treated for ALL, it has also been reported in patients treated with methotrexate and irradiation for cerebral tumours [7].

All four patients in the present study had had leukaemia without primary involvement of the CNS when they presented with epileptic fits. The first examination carried out in all children was CT in order to rule out an intracerebral haematoma; indeed, a possible side effect of chemotherapy is thrombocytopenia, which could induce cerebral haemorrhages. The CT scans in three of the cases revealed multiple cerebral calcifications.

**Fig. 1** **a** Axial CT scan of the brain before (*left*) and after (*right*) contrast medium administration showing bilateral subcortical enhancing calcified foci. Mean attenuation values of 93 HU were measured in a 3-mm region of interest (ROI) before contrast medium administration and 115 HU after intravenous contrast medium administration. **b** T2-weighted axial MRI scan showing diffuse periventricular white matter hyperintensities in both hemispheres. **c** MRI performed 3 months later showing the white matter lesions to be still present bilaterally, their extension having changed slightly. **d** T1-weighted axial MRI demonstrating the presence of additional subcortical hyperintense foci in the left frontal and occipital lobes. **e** T2-weighted FLASH MRI demonstrating the presence of subcortical hypointensities in the left frontal lobe and in both occipital lobes, corresponding to calcifications. **f** Sagittal T1-weighted MRI demonstrating the gyriform pattern of subcortical calcific hyperintensities. **g** Sagittal contrast-enhanced T1-weighted MRI showing the hyperintensities to enhance diffusely, especially in the occipital region



**Fig. 2** **a** Axial CT showing multiple hyperdense foci located subcortically bilaterally as well as in the basal ganglia on the right side. **b** The corresponding T1-weighted axial MRI showing hyperintensities located in the basal ganglia. **c** After contrast medium administration, the lesions enhance diffusely in the basal ganglia, and the right-sided subcortical lesion, which was less evident on the unenhanced image, also enhances slightly. **d** Coronal contrast-enhanced MRI showing the enhancing lesion in the right basal ganglia



These lesions were not expansile and did enhance slightly after contrast medium administration.

MRI was subsequently performed in all cases. Indeed, in the acute phase, the CT scans did not conclusively exclude the lesions being haemorrhagic. MRI showed that these lesions did not display the magnetic properties of blood degradation products. FLASH sequences were especially helpful in determining the calcific nature of the lesions.

Calcification as a result of cranial radiation to the central nervous system is well recognised, being found on CT in 10–28 % of children thus treated [8, 15]. In

cases of severe diffuse calcification, the findings on a standard skull X-ray may even mimic those seen in Sturge-Weber syndrome [16]. In a series of 163 autopsied brains of children treated for leukaemia, 17 % had non-inflammatory mineralising microangiopathy with cerebral necrosis and calcification in the vessel walls [17]. The presence of both calcifications and epileptic seizures indicates an advanced form of methotrexate encephalopathy, with changes that are irreversible at this stage. The association of these calcifications with epileptic fits is well documented; in one study, seizures were present in 6 % of patients [8].

According to Ball, the changes seen in these cases correspond to late "delayed" injury where vascular involvement leads to ischaemia, infarction and necrosis. In this situation, enhancement with gadolinium is common [14], as seen in our cases.

One series studying the brain CT features of children with ALL who had received chemotherapy showed that 7 of 23 children had areas of periventricular low density and slight ventricular enlargement but only one showed calcification [3]. In another series, only 6 of 28 patients had normal scans, with one patient presenting the typical calcifications as the only finding [5]. There have also been reports of dementia as an associated finding [7].

Younger patients, especially those less than 10 years old, are more at risk of developing these sequelae [2, 14]. It seems that it is usually the combination of chemotherapy with radiation therapy that causes calcification; indeed, a study of 43 patients treated with methotrexate alone showed no pathological calcification [4].

MRI is known to be more sensitive to the white matter changes present in these cases [10], but the reports are not always in agreement [13] and the changes have also been reported to be reversible and present only for a limited time [13]. Kramer et al., for instance, reported that patients receiving less than 2500 cGy had no cerebral changes on MRI, even in the presence of cognitive impairment [12]. However, in their study, Davis et al. found that children with and without associated radiotherapy had as great a risk of developing calcification after chemotherapy [15]. As it has been suggested that the calcifications are due to radiation-induced vasculopathy,

the enhancement observed on both CT and MRI in the calcified foci and in the subcortical U-fibres, even if very discrete, are also indicative of a localised disruption of the blood-brain barrier.

In our series, none of the patients underwent radiotherapy; they were, however, treated with high-dose chemotherapy comprising both intravenous and intrathecal methotrexate. These findings suggest that methotrexate alone is capable, when administered in high doses and intrathecally, of inducing this leukoencephalopathy. The exact role of methotrexate in causing these sequelae [2], when administered alone, is still unclear. Pääkko et al. reported the occurrence of one such case among 11 patients who had received no radiation therapy [13]. They later concluded, however, that these changes are rather rare and do not warrant routine follow-up MRI in asymptomatic children after a baseline assessment [9]. Even if most children with neurological symptoms have normal scans [13], the onset of severe symptoms such as the seizures in our series should prompt more aggressive neuroimaging. CT as the first step is necessary in order to rule out haemorrhage; MRI, especially T2-weighted imaging, will more clearly demonstrate the presence of the diffuse white matter changes [13, 14].

White matter changes associated with cerebral calcification in children might be due to other primary diseases, but the CT and MRI appearances in these cases, together with a clinical history of ALL treated by chemotherapy but not radiation, allowed us to conclude with confidence that the patients suffered from a pure form of methotrexate encephalopathy.

## References

- Berg S, Poplack DG (1995) Clinical manifestations of acute lymphocytic leukemia in children. In: Hoffman R, Benz EJ, Shattil SJ, Furie B, Cohen HJ, Silberstein LE (eds) *Hematology, basic principles and practice*, 2nd edn. Churchill Livingstone, New York, pp 1067–1074
- Sallan SE, Cohen HJ (1995) Therapy for acute lymphocytic leukemia in children. In: Hoffman R, Benz EJ, Shattil SJ, Furie B, Cohen HJ, Silberstein LE (eds) *Hematology, basic principles and practice*, 2nd edn. Churchill Livingstone, New York, pp 1075–1084
- Pedersen H, Clausen N (1981) The development of cerebral CT changes during treatment of acute lymphocytic leukemia in childhood. *Neuroradiology* 22: 79–84
- Ochs JJ, Berger P, Brecher ML, et al (1980) Computed tomography brain scans in children with acute lymphocytic leukemia receiving methotrexate alone as central nervous system prophylaxis. *Cancer* 45: 2274–2278
- Lund E, Hamborg-Pedersen B (1984) Computed tomography of the brain following prophylactic treatment with irradiation therapy and intraspinal methotrexate in children with acute lymphoblastic leukemia. *Neuroradiology* 26: 351–358
- Flament-Durand J, Ketelbant-Balasse P, Maurus R, et al (1975) Intracranial calcifications appearing during the course of acute lymphocytic leukemia treated with methotrexate and x rays. *Cancer* 35: 319–325
- Fernandez-Bougas A, Ramirez Jimenez H, Vazquez Zanudio J, et al (1992) Brain calcification and dementia in children treated with radiotherapy and intrathecal methotrexate. *J Neurosurg Sci* 36: 211–214
- Chessells JM, Cox TCS, Kendall B, et al (1990) Neurotoxicity in lymphoblastic leukaemia: comparison of oral and intramuscular methotrexate and two doses of radiation. *Arch Dis Child* 65: 416–422
- Pääkko E, Vainionpää L, Pyhtinen J, Lanning M (1996) Minor changes on cranial MRI during treatment in children with acute lymphoblastic leukaemia. *Neuroradiology* 38: 264–268
- Ito M, Akiyama Y, Asato R, et al (1991) Early diagnosis of acute lymphocytic leukemia by MRI. *Pediatr Neurol* 7: 426–439

11. Kingma A, Mooyaart EL, Kamps WA, et al (1993) Magnetic resonance imaging of the brain and neuropsychological evaluation in children treated for acute lymphoblastic leukemia at a young age. *Am J Pediatr Hematol Oncol* 15: 231–238
12. Kramer JH, Norman D, Brant-Zawadzki M, et al (1988) Absence of white matter changes on magnetic resonance imaging in children treated with CNS prophylaxis therapy for leukemia. *Cancer* 61: 928–930
13. Pääko E, Vainiopää L, Lanning M, et al (1992) White matter changes in children treated for acute lymphoblastic leukemia. *Cancer* 70: 2727–2733
14. Ball WS, Prenger EC, Ballard ET (1992) Neurotoxicity of radio/chemotherapy in children: pathologic and MR correlation. *AJNR* 13: 761–776
15. Davis PC, Hoffman JC, Pearl GC, Braun IF (1986) CT evaluation of effects of cranial radiation therapy in children. *AJR* 147: 587–592
16. Garwicz S, Mortensson W (1976) Intracranial calcification mimicking the Sturge-Weber syndrome: a consequence of cerebral folic acid deficiency? *Pediatr Radiol* 5: 5–9
17. Price RA, Birdwell DA (1978) The central nervous system in childhood leukemia. III. Mineralizing microangiopathy and dystrophic calcification. *Cancer* 42: 717–728

## BOOK REVIEW

**Kathryn North: Neurofibromatosis type 1 in childhood (with one chapter by David H. Gutmann):** London MacKeith Press for the International Child Neurology Association 1997. 132 pp, with illustrations, (ISBN 1-898683-13-1), \$ 47.95.

*Type of book:* A single-author text except for one chapter by David H. Gutmann.

*Scope:* This book provides a comprehensive overview of neurofibromatosis type 1 with emphasis on cognitive functions and occurrence of optic glioma. The use of MRI as a diagnostic tool in this disease discussed in detail.

*Contents:* The book begins with a historical perspective of the disease, noting that a significant portion of the information presented is derived from the 200 patients seen at the neurofibromatosis 1 clinic estab-

lished in 1991 at the Royal Alexandra Hospital for Children in Sydney, Australia.

“This patient population formed the basis for detailed studies of two of the most common complications of NF1 in childhood – academic learning disabilities and optic gliomas.” The introduction is then followed by chapters on the molecular biology of NF1, the clinical manifestations of NF1 patients, and two chapters on cognitive function. There is discussion of the role of MRI T2 signal abnormalities. Chapters on optic gliomas in NF1, the role of visual evoked potentials as screening and approach to assessment and management, and MRI as a tool in NF1 all follows. There are multiple appendices.

*Strengths:* The writing is clear and there is an up-to-date comprehensive chapter on genetics and description of most of the findings in NF1. The emphasis clearly is on cognitive function and the role MRI may play in detecting abnormalities in these children. There is major emphasis on diag-

nostic tools of which the radiologist may not be aware. The authors also deal with indications for studies in this population and their cost-effectiveness.

*Deficiencies:* The book has several major deficiencies. The images are less than optimal, and there is no discussion of the management of many of the problems, i.e., orthopedic.

*Recommended readership:* This volume would be useful in a library as a reference text.

*Overall grading:* \*\*\*

Thomas L. Slovis, M.D.

### Grading key

\*\*\*\*\* = outstanding; \*\*\*\* = excellent;  
\*\*\* = good; \*\* = fair; \* = poor