

Clinical Trial of Low Density Lipoprotein-Apheresis for Treatment of Diabetic Gangrene

Takashi IIZUKA, Haruyo TAKEDA, Hiromi INOUE, Terukazu MIYAMOTO, Hiroko ITO,
Masao OMURA, Hiroyuki TSUJI, Shyozo CHIBA and Tetsuo NISHIKAWA

A 68-year-old man with a 28-year history of non-insulin dependent diabetes mellitus (NIDDM) was admitted to our hospital because of foot gangrene. He had previously suffered from cerebral infarction resulting in right hemiplegia and his right foot was amputated because of right femoral lesion presenting diabetic foot gangrene 5 years previously. The diabetic foot gangrene gradually became worse, although he had received various medications. Then, we attempted to treat the patient with low density lipoprotein (LDL)-apheresis ten times a month. The foot gangrene itself and the local circulation around the gangrene lesion were remarkably improved after treatment with LDL-apheresis. We present here the first case of diabetic foot gangrene improved by LDL-apheresis. LDL-apheresis therapy is anticipated to be a new therapeutic approach for treatment of fatal foot gangrene associated with diabetes mellitus.
(Internal Medicine 36: 898-902, 1997)

Key words: low density lipoprotein (LDL)-apheresis, non-insulin dependent diabetes mellitus (NIDDM), foot gangrene

Introduction

Diabetes mellitus is one of the most common and serious metabolic disorders characterized by various complications involving diabetic micro- and macroangiopathy (1-3). The diabetic complications which typically develop due to poor control of diabetes sometimes induce diabetic foot gangrene. As it is very difficult to successfully treat diabetic foot gangrene and achieve complete healing, sometimes it is necessary to perform amputation. However, lowering of the serum low density lipoprotein (LDL) by a variety of techniques such as LDL-apheresis and medications, has beneficial effects for prevention and regression of atherosclerosis in patients with hypercholesterolemia (4). Moreover, LDL-apheresis is also well known to be beneficial for improving peripheral circulatory insufficiency such as foot gangrene induced by arteriosclerosis obliterance. On the other hand, there have never been any reports describing whether or not the treatment with LDL-apheresis improves diabetic foot gangrene. Thus, we attempted to examine the effect of LDL-apheresis therapy on diabetic foot gangrene in a patient with non-insulin dependent diabetes mellitus (NIDDM).

Case Report

A 68-year-old man was admitted to Yokohama Rosai Hospital due to foot gangrene in January 1996. He was first noticed to have diabetes mellitus and hypertension by a regular health check-up examination when he was 40 years old. However, he did not visit any hospitals. He was started on insulin therapy from March 1991 due to poor control of blood sugar levels. He suffered from cerebral infarction in October 1991, resulting in right hemiplegia. In November 1991, his right foot was amputated because of a right femoral lesion presenting diabetic foot gangrene. He smoked 15 to 20 cigarettes a day for 42 years until he stopped smoking in November 1991.

On admission, his height was 160 cm and body weight 45 kg. His temperature was 36.5°C, radial pulse rate 72/min, and blood pressure 120/70 mmHg. The visual acuity was normal. No abnormal heart sounds were heard. A chest roentgenogram disclosed marked elongation of the aorta with calcification in the aortic arch and an abdominal roentgenogram showed distension of the small and large bowels due to a large volume of air. His right thigh was amputated at one-third lower femoral lesion. Pulsation was absent at the peripheral arteries in the left lower extremity, especially at the dorsalis pedis, the tibialis and popliteal arteries. His tendon jerk reflex was absent at the left

From the Department of Medicine, Yokohama Rosai Hospital, Yokohama

Received for publication November 28, 1996; Accepted for publication August 6, 1997

Reprint requests should be addressed to Dr. Takashi Iizuka, the Department of Medicine, Yokohama Rosai Hospital, Yokohama, Kanagawa 222

lower extremity.

He injected insulin (6 units/day of Novolin 30R) by himself every morning and had a 1,400 kcal-diet; the laboratory data during this treatment is shown in Table 1. The levels of fasting plasma glucose and HbA_{1C} were 126 mg/dl and 6.0%, respectively. The serum concentrations of total cholesterol, LDL-cholesterol, triglyceride and high density lipoprotein (HDL)-cholesterol were 179 mg/dl, 105 mg/dl, 65 mg/dl, and 61.2 mg/dl, respectively.

Clinical course

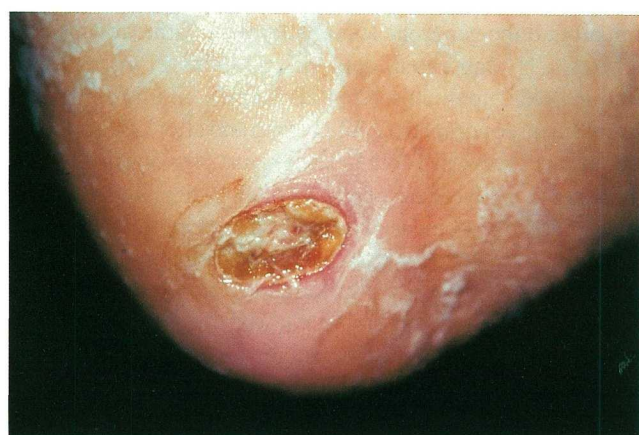Although the patient underwent various types of treatment such as hyperbaric oxygen therapy and, drip infusion of PGE₁ and antibiotics, the lesion of gangrene gradually became worse. Then, we attempted to treat the patient with LDL-apheresis ten times a month in March 1996. The gangrene improved gradually after LDL-apheresis therapy as shown in Fig. 1A and B. As shown in Fig. 2, thermography of his left lower extremity demonstrated a remarkable improvement in the local circula-

tion around the gangrene lesion after the treatment with LDL-apheresis. His laboratory data including the serum concentration of lipids, apolipoproteins, fibrinogen and thrombin-anti-thrombin three complex (TAT) before and after LDL-apheresis therapy are shown in Table 2. The serum concentrations of total cholesterol, triglyceride, apolipoprotein B, fibrinogen and TAT were markedly decreased after LDL-apheresis therapy, although the serum levels of HDL-cholesterol, and apolipoprotein A1, A2 and E were not changed. Clinical course of blood glucose and hemoglobin A_{1C} (HbA_{1C}) levels during his admission is shown in Fig. 3, and the blood glucose level was well controlled by insulin with restriction of calorie intake. In October 1996, the lesion of the foot gangrene was nearly completely cured by treatments with LDL-apheresis and various types of supportive therapies and he was discharged from our hospital.

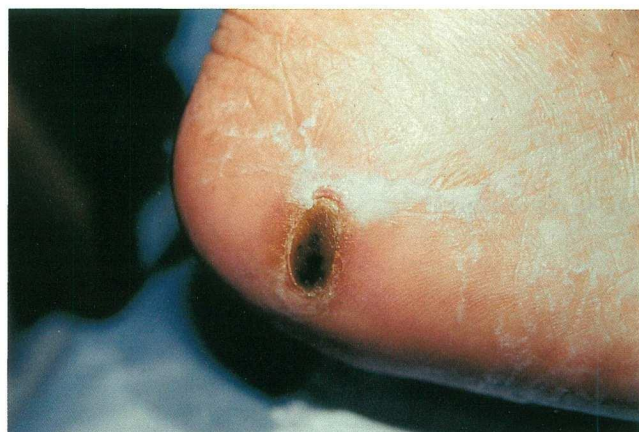Table 1. Laboratory Data on Admission

	(Normal range)		(Normal range)	
WBC	(3,500–8,700)	6,300/μl	T.P.	(6.5–8.0) 6.8 g/dl
RBC	(400–570×10)	428×10	Alb.	(4.0–5.3) 4.1 g/dl
Hb	(13.0–17.0)	12.8 g/dl	U.A.	(2.9–5.9) 4.0 mg/dl
Ht	(38.0–50.0)	38.1%	BUN	(9.0–22.0) 15.4 mg/dl
Plts	(15.0–35.0×10)	17.1×10	Cr	(0.4–0.8) 0.4 mg/dl
CRP	(0.0–0.4)	0.05 mg/dl	Amy.	(32–88) 54 IU/l
			AST	(11–29) 11 IU/l
PT	(80–100)	87%	ALT	(9–36) 15 IU/l
APTT	(30–45)	35.8 seconds	ALP	(98–267) 176 IU/l
Fbg	(200–400)	308 mg/dl	LDH	(226–406) 254 IU/l
Urinalysis			Ch-E	(3.8–7.4) 4.1 IU/ml
Protein	(–)	(–)	G-GTP	(5–65) 20 IU/l
Glucose	(–)	(–)	Na	(139–146) 141 mEq/l
Ketone	(–)	(–)	K	(3.6–4.7) 4.6 mEq/l
Sed. WBC	(1–2/Fs)	0–1/Fs	Cl	(103–110) 101 mEq/l
RBC	(1–2/Fs)	0–1/Fs	T-chol.	(130–220) 179 mg/dl
Epith.	(1–2/Fs)	0–1/Fs	LDL-chol.	(40–150) 105 mg/dl
Ccr	(80–120)	168.4 ml/dl	TG	(36–150) 65 mg/dl
Urinary CPR	(40–145)	28.7 μg/day	HDL-chol.	(40–80) 61.2 mg/dl
Alb.	(0–21.6)	15.6 mg/day	Apo.A1	(105–180) 127 mg/dl
Occult blood	(–)	(–)	Apo.A2	(28–49) 21.4 mg/dl
FBG	(70–100)	126 mg/dl	Apo.B	(55–120) 69 mg/dl
HbA _{1C}	(3.5–5.5)	6.0%	Apo.C2	(2.2–5.9) 3.4 mg/dl
TSH	(0.24–3.70)	3.23 uIU/ml	Apo.C3	(5.7–13.1) 6.4 mg/dl
F-T3	(2.4–4.3)	2.6 pg/ml	Apo.E	(2.8–5.8) 3.2 mg/dl
F-T4	(0.8–2.1)	1.4 ng/dl		

PT: Prothrombin time, APTT: Activated partial thromboplastin time, Fbg: Fibrinogen, Ccr: Creatinine clearance, HbA_{1C}: Hemoglobin A_{1c}, TSH: Thyroid stimulating hormone, F-T3: Free triiodothyronine, F-T4: Free thyroxine, LDH: Lactate dehydrogenase, G-GTP: γ glutamyltranspeptidase, LDL-chol.: Low density lipoprotein-cholesterol, HDL-chol.: High density lipoprotein-cholesterol, T.P.: Total protein, Alb.: Albumin, U.A.: Uric acid, BUN: blood urea nitrogen, Cr: Creatinine, Amy.: Amylase, AST: Aspartate aminotransferase, ALT: Alanine aminotransferase, ALP: Leucine aminopeptidase, T-chol.: Total cholesterol, TG: Triglyceride, Apo.: Apolipoprotein.

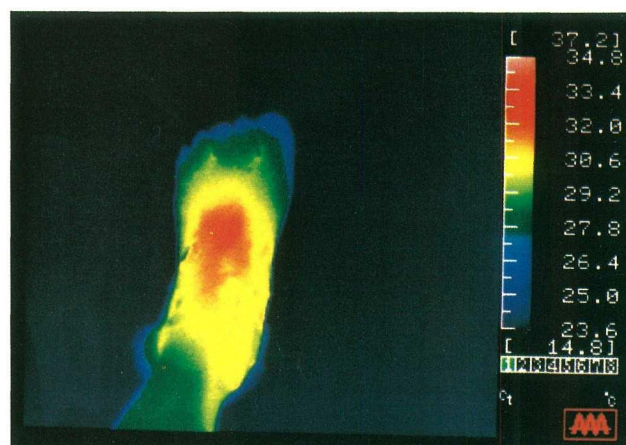


A

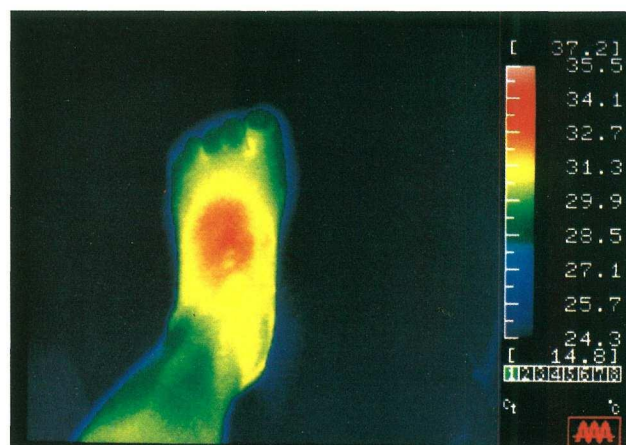


B

Figure 1. Photographs of his left heel. (A) Diabetic gangrene on the left heel associated with skin cyanosis around the gangrene lesion before LDL-apheresis therapy. (B) Improved diabetic gangrene on the left heel after LDL-apheresis therapy for nine times.



A



B

Figure 2. Thermographical examination of his lower extremity. Thermography before (A) and after (B) treatment with LDL-apheresis.

Table 2. Serum Lipids, Apolipoproteins, Fibrinogen and TAT before and after the LDL-Apheresis Therapy

	before LDL-apheresis	after LDL-apheresis
Total-ch.	176 (mg/dl)	93 (mg/dl)
Triglyceride	78 (mg/dl)	30 (mg/dl)
HDL-ch.	61.2 (mg/dl)	61.0 (mg/dl)
Apolipoprotein-A1	125 (mg/dl)	122 (mg/dl)
Apolipoprotein-A2	21.0 (mg/dl)	20.1 (mg/dl)
Apolipoprotein-B	68 (mg/dl)	30 (mg/dl)
Apolipoprotein-E	3.3 (mg/dl)	1.6 (mg/dl)
Fibrinogen	300 (mg/dl)	183 (mg/dl)
TAT	8.3 (μg/l)	7.3 (μg/l)

TAT: thrombin-antithrombin three complex.

Discussion

The present study clearly demonstrated that the lesion of diabetic foot gangrene was almost completely cured by treatment with LDL-apheresis and various supportive therapies, although it has never been reported that LDL-apheresis therapy improves diabetic foot gangrene. It is well known that one of the most severe complications of diabetes mellitus is the loss of a limb. It has been suggested that three major factors leading to tissue necrosis in the diabetic foot are peripheral neuropathy, infection and ischemia. Peripheral ischemia in patients with diabetes mellitus is believed to be induced by micro- and macroangiopathy. It is, however, unlikely that the micro- and macrovascular diseases are a direct cause of diabetic foot gangrene, since almost all patients with diabetic gangrene have peripheral neuropathy which may induce an impairment in protective mechanisms against trauma such as burning. Furthermore, infections with anaerobic bacteria coexisting with

LDL-Apheresis and Diabetic Gangrene

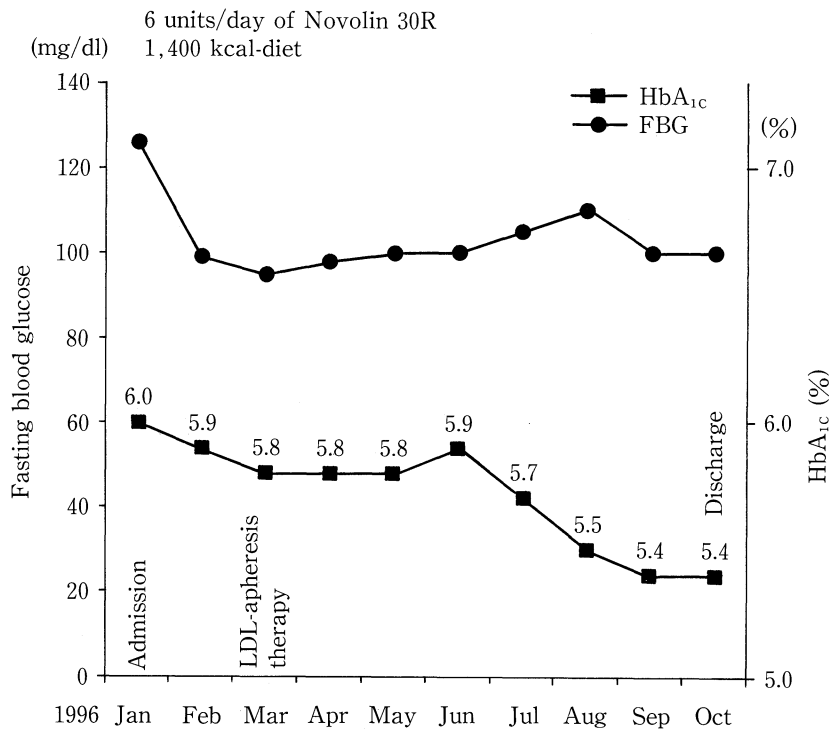


Figure 3. Clinical course of blood glucose and HbA_{1c} levels during admission.

aerobic bacteria are usually observed in most gangrene tissues of the diabetic foot, suggesting that local infection is also an important factor for inducing and worsening gangrene. On the other hand, LDL plays a crucial role in the development of atherosclerosis (7). In the present case, serum lipid levels such as total cholesterol, LDL-cholesterol and apolipoprotein B were not high, compared with the normal range of those lipids, while diabetic foot gangrene became severe and the possibility of remission was thought to be very low when treated by usual therapy.

Many reports have described that LDL-apheresis has a direct effect on removing LDL-cholesterol, finally resulting in regression of atherosclerosis (4, 8–12). It is also believed that LDL-apheresis may improve abnormalities in lipid metabolism (8, 9), peripheral circulation and blood viscosity (10), local immune functions (4), circulating coagulation factors (11), and kallikrein-kinin systems and serum level of NO (12). A previous study suggested that the decreased levels of peri-wound cutaneous perfusion and oxygenation may contribute to the development of diabetic foot gangrene (5). In the present study, the local circulation around the gangrene lesion was remarkably improved after LDL-apheresis. Rubba et al reported that peak blood flow significantly increased in the leg, and blood viscosity was significantly reduced after LDL-apheresis in ten patients with hypercholesterolemia (10). This study also reported that removal of serum fibrinogen was observed after LDL-apheresis therapy (from 300 mg/dl to 183 mg/dl). Tasaki et al reported that LDL-apheresis therapy could remove fibrinogen by LDL-adsorption and lead to an improvement in the local

circulation in patients with arteriosclerotic obliteration (ASO) (11). The present study suggests that LDL-apheresis may affect anticoagulant factors, and improve the local blood flow in patients with diabetic foot gangrene. Although the mechanism of LDL-apheresis therapy improving diabetic foot gangrene is not fully understood, it is speculated that the treatment with LDL-apheresis may induce new collagen synthesis around the lesion of gangrene. Therefore, it is suggested that aggressive treatment of local gangrene tissue induced by diabetes mellitus, such as LDL-apheresis therapy, seems to promote enhancement in local oxygenation of gangrenous tissues.

This study demonstrated that LDL-apheresis therapy may be a new therapeutic approach for improvement in fatal foot gangrene induced by diabetes mellitus.

References

- 1) LoGerfo FW, Coffman JD. Current concepts. Vascular and microvascular disease of the foot in diabetes. Implications for foot care. *N Engl J Med* **311**: 1615, 1984.
- 2) Debridge L, Appleberg M, Reeve TS. Factors associated with development of foot lesions in the diabetic. *Surgery* **93**: 78, 1980.
- 3) McMillan DE. Plasma protein changes, blood viscosity, and diabetic microangiopathy. *Diabetes* **25**: 858, 1976.
- 4) Uno H, Ueki Y, Murashita J, Miyake S, Tominaga Y, Eguchi K, Yano K. Removal of LDL from plasma by adsorption reduces adhesion molecules on mononuclear cells in patients with arteriosclerotic obliterans. *Atherosclerosis* **116**: 93, 1995.
- 5) Pecoraro RE, Ahroni JH, Boyko EJ, Stensel VL. Chronology and determinants of tissue repair in diabetic lower-extremity ulcers. *Diabetes* **40**: 1305, 1991.
- 6) Steinberg D, Parhasarathy S, Carew TE, Khoo JC, Witztum JL. Beyond

- cholesterol. Modifications of low density lipoprotein that increase its atherogenicity. *N Engl J Med* **320**: 915, 1989.
- 7) Ross R. The pathogenesis of atherosclerosis: a perspective for the 1990s. *Nature* **362**: 801, 1993.
 - 8) Bambauer R, Schiel R, Keller HE, Latza R. LDL-apheresis in two patients with extremely elevated lipoprotein (a) levels. *Int J Artif Organs* **18**: 286, 1995.
 - 9) Kritz H, Sinzinger H. Atherosclerotic lesions in humans-plaque stabilization and regression. *Wien Klin Wochenschr* **107**: 555, 1995.
 - 10) Rubba P, Iannuzzi A, Postiglione A, Scarpato N, Montefusco S, Gnasso A, Nappi G, Cortese C, Mancini M. Hemodynamic change in the peripheral circulation after repeat low density lipoprotein apheresis in familial hypercholesterolemia. *Circulation* **81**: 610, 1990.
 - 11) Tasaki H, Tsuda Y, Yamashita K, Toyokawa T. Removal of plasma fibrinogen by LDL apheresis. *Jpn J Apheresis* **15** Suppl: S55, 1996 (Abstract).
 - 12) Ueki Y, Murashima J, Matsunaga Y, Tominaga Y, Miyake S. Generated bradykinin by LDL adsorption induces serum NO in patients with atherosclerotic obliteration. *Jpn J Apheresis* **15** Suppl: S56, 1996 (Abstract).
-