

Case report
Rotatory seizures in juvenile myoclonic epilepsy¹

M. Akif Topçuoğlu *, Serap Saygı, Abdurahman Cığır

Department of Neurology, Hacettepe University Hospitals, Sıhhiye 06100, Ankara, Turkey

Received 1 May 1996; received in revised form 3 September 1996; accepted 3 September 1996

Abstract

Rotatory seizures have been reported in association with focal intracranial lesions. This type of seizure was also described in patients with primary generalized epilepsies. To our knowledge, there is only one previous publication denoted an association between juvenile myoclonic epilepsy (JME) and rotatory seizures. We present two female patients with JME and rotatory seizures together. The onset of myoclonic jerks and generalized tonic clonic (GTC) seizures was in their midteens. Their interictal EEGs showed bilateral symmetric spike and polyspike wave discharges. The rotatory seizures of the patients started at age of 26 and 33 years, respectively. In one of the patients, turning to the left was followed by three or four complete turns, after then, she had GTC seizures. The other patient has turned to the right with only one or two turns and sometimes continued with GTC seizures. Neuroradiologic investigations including brain CT, MRI, and SPECT were performed. Response to valproate therapy of rotatory seizures was good. We believe that rotatory seizures are rarely seen in JME patients, and this causes false diagnosis which lead unsuitable drug choice. © 1997 Elsevier Science B.V.

Keywords: Juvenile myoclonic epilepsy; Rotatory seizures

1. Introduction

Rotatory seizures are very rare and are also called circling or volvular or gyratory seizures. Rotatory seizures have been reported in association with focal intracranial lesions [1–6] and can be seen in patients with primary generalized epilepsies [7].

Juvenile myoclonic epilepsy (JME) is a well recognized epileptic syndrome and clinical or EEG asymmetries have been documented in various ratios [8–16]. To our knowledge, there is only one previous publication about on association between JME and rotatory seizures [17].

In this report, we present two additional patients with JME who have also rotatory seizures.

2. Case reports

2.1. Case 1

A 49 year old woman was seen by one of the authors (S.S.) for intractable seizures in 1992. She had started having generalized tonic clonic (GTC) seizures at 33 years of age. She had been put on phenytoin (350 mg/day) and then in a combined therapy with phenobarbital (300 mg/day). Despite the combined therapy, she was still having generalized seizures. Her husband and daughter reported that in some seizures she has turned to the left and made three to four complete turns before falling and having GTC seizures. When she was asked if she has ever had other types of seizures such as jerks or absence, the history of bilateral myoclonic jerks on awakening since her midteens was elicited. Her neurologic examination was normal and there was no clinical and laboratory evidence for sys-

* Corresponding author. Fax: +90 312 3093451.

¹ Presented at the 21st International Epilepsy Congress, Sydney, Australia, September 3–8, 1995.

temic disease except mild hyperglycemia. She had been admitted to psychiatry clinic for several times for attacks of aggression and paranoid delusions and some antipsychotic drugs with small dosages have been prescribed intermittently. Some previous EEGs and the EEG obtained during the last visit showed generalized spikes and multiple spike and slow wave complexes at 3.5–4 Hz frequency. Computed tomography (CT) of the brain was normal. Valproate (VPA) monotherapy was started (1200 mg/day). She remained seizure-free for the last 3 years with VPA. During the seizure free period, magnetic resonance-imaging (MRI) revealed nonspecific millimetric white matter changes (Fig. 1) whereas single photon emission computed tomography (SPECT) with Tc^{99m} -HMPAO of brain showed hypoperfusion in the left hemisphere (Fig. 2).

2.2. Case 2

A 34 year old woman who has been suffering from GTC seizures and myoclonic jerks for 20 years was seen in our out-patient clinic. Phenytoin (300 mg/day) and clonazepam (2 mg/day) combined therapy, VPA monotherapy (800 mg/day), phenobarbital (300 mg/day) monotherapy all have been tried in the past, but myoclonic jerks and GTC seizures continued. She and witnesses of her seizures spontaneously reported some episodes characterized by turning to the right, making 1–2 complete turns before falling down and having GTC seizures. Onset of this type of seizures was at 26 years of age. Her previous history and family history were unremarkable except a few depressive episodes that required antidepressive drug treatment. Neurologic examination and brain CT were normal. Routine and sleep deprived EEGs revealed generalized multiple spike and slow wave complexes at 4–6 Hz frequency which could also be evoked by intermittent photic

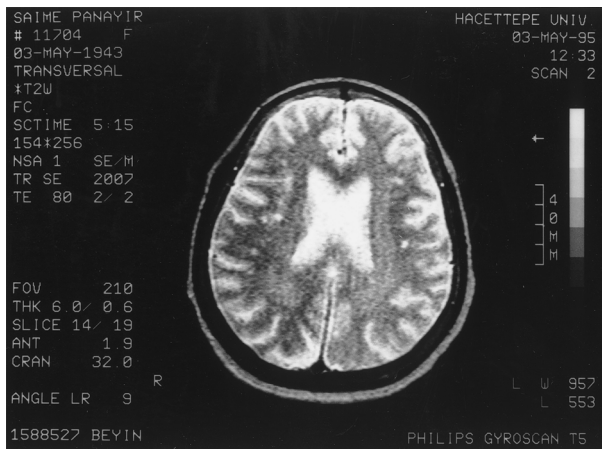


Fig. 1. MRI of Case 1 reveals nonspecific millimetric signal changes in the white matter.

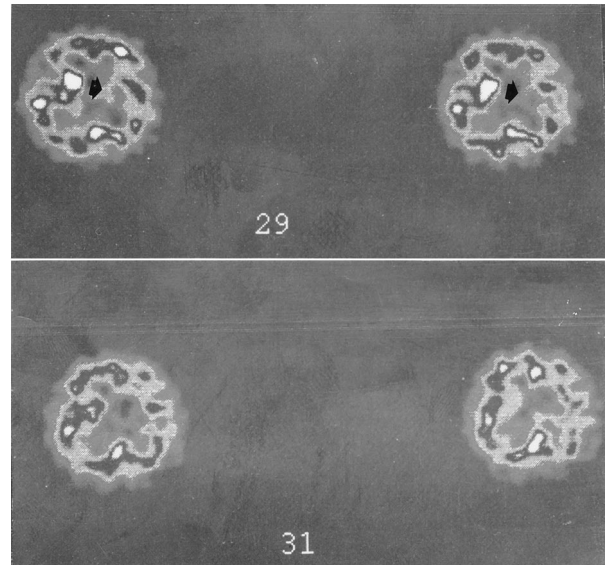


Fig. 2. Brain SPECT study of Case 1 shows hypoperfusion in the left hemisphere.

stimulation. One of her eight EEGs showed slight right lateralization (Fig. 3). VPA (900 mg/day) was added to phenobarbital. During the last 2 years, she has been seizure free with combined therapy of VPA and phenobarbital. MRI and SPECT performed during the seizure free period were normal.

3. Discussion

Rotatory seizures have been reported in association with focal cerebral disease, including brain tumors (astrocytoma, glioma), trauma, infarction, giant aneurysm, depressed skull fracture, calcification and encephalitis [2,4–6].

Gastaut reported 28 patients with versive and rotatory seizures which were associated with generalized spike-wave discharges [7]. Only one case with rotatory seizures have been described in association with JME [17]. If the patients reported by Gastaut are reviewed carefully, it seems that some of these cases may have been JME patients [7]. The two reported cases with JME and rotatory seizures are the only two of our 100 cases with JME which were collected in the last 3 years [18].

Unidirectional head and/or eye turning may rarely occur in typical absence seizures [19,20]. However complete circling associated with absences were not published.

Although typical clinical and electroencephalographic evidences for the diagnosis of JME are present in both of these patients, it took more than 15 years to make a correct diagnosis of JME. This time interval is

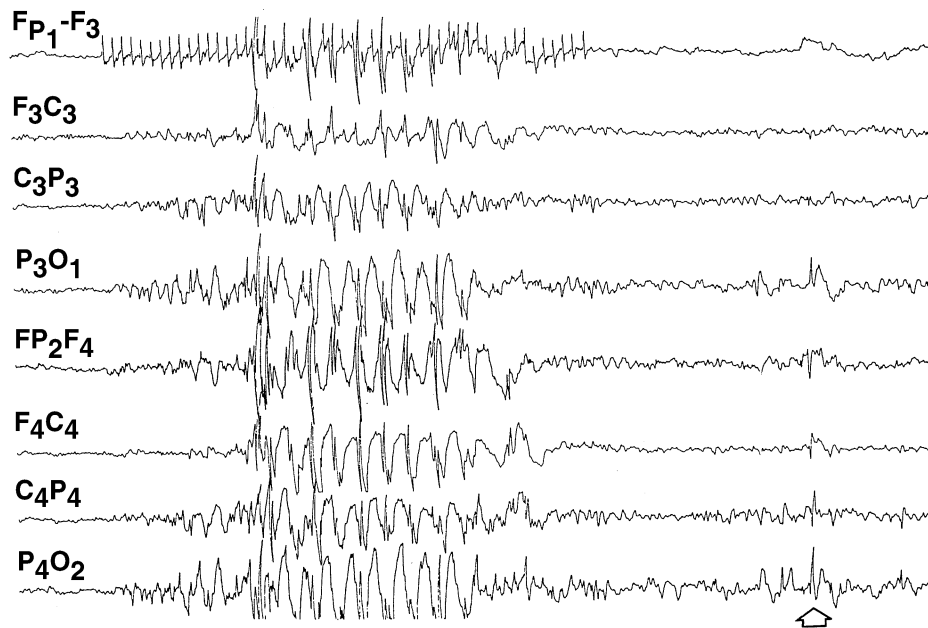


Fig. 3. EEG of Case 2 shows discharges predominantly on the right hemisphere and photosensitivity ($f = 10$ Hz).

longer than for other JME patients without rotatory seizures [18]. Failure to make an accurate diagnosis resulted in poor control of seizures. Delayed diagnosis and taking inappropriate antiepileptic-drugs may contribute to the development of rotatory seizures [1].

There are several possible cerebral structures responsible for circling. Some studies suggest temporal lobe involvement [1,2]. Epileptic foci and lesions associated with circling are located from anterior frontal to temporal, parietal and occipital lobes [1,3–6]. It seems that these seizures can originate from wide areas of cerebral cortex. This raises the possibility that epileptic discharges originating from deeper structures, such as thalamus and striatum can be the common responsible mechanism [1,3,6]. The reason for circling in JME and other generalized epilepsies is not well understood; but it can be due to spreading of the epileptic discharges to the striatum, especially in the elder patients who have had a large number of GTC seizures for a long time because of ineffective treatment due to a wrong diagnosis. In these cases, secondary cortical or deep structural involvement due to repeated GTC seizures may induce rotation [21]. Gestaut postulated a functional imbalance in generalized cerebral excitability. This idea is supported by the findings of clinical and EEG asymmetries in generalized epilepsy. Furthermore, experiments in rats with circling seizures showed some findings suggesting an intrinsic asymmetry of the nigrostriatal dopaminergic system [22]. In both our presented cases, there is not any structural lesion in CT and MRI. But one of the EEGs of Case 2 showed right lateralization which was consistent with the direction of rotation. In Case 1, SPECT showed hypoperfusion in

the left hemisphere. The direction of turning was also to the left. Each of the patients therefore may have a functional but not a structural abnormality and this supports Gastaut's hypothesis.

Rotatory seizures respond well to phenytoin and carbamazepine [1,3,5]. In cases with generalized epilepsy, these drugs seem ineffective for rotatory seizures and should be switched to VPA.

We believe rotatory seizures associated with JME are rarely seen and this combination of seizures may cause diagnostic errors. Rotatory seizures are the best examples of asymmetric motor manifestations associated with a generalized type of epilepsy. Neurologists should keep in mind the possibility of profound and various asymmetries in the presentation of idiopathic generalized epilepsies.

References

- [1] Chandrashekar M, Probhakar S, Sawhney IMS, Dhand UK, Chopra RS. Rotatory seizures. *Epilepsia* 1992;33:522–6.
- [2] Chopra JS, Radhakrishnan K, Razdan K. Circling movements in human viral encephalitis. *J Neurol Neurosurg Psychiatry* 1982;45:659–60.
- [3] Donaldson IM. Volvular epilepsy: a distinctive and underreported seizure type. *Arch Neurol* 1986;43:260–2.
- [4] Hochman MS. Rotatory seizures associated with frontal lobe malignant neoplasm: A case report. *Epilepsia* 1983;24:11–4.
- [5] Joseph TP, Chand RP. Rotatory seizures of frontal lobe origin. *Clin Neurol Neurosurg* 1994;95(3):237–40.
- [6] Leiguarda R, Nogues M, Berthier M. Gyrotory epilepsy in a patient with a thalamic neoplasm. *Epilepsia* 1992;33:826–8.
- [7] Gastaut H, Aguglia U, Tinuper P. Benign versive or circling epilepsy with bilateral 3-cps spike and wave discharges in late childhood. *Ann Neurol* 1986;18:301–3.

- [8] Aliberti V, Grünewald RA, Panayiotopoulos CP, Chroni E. Focal electroencephalographic abnormalities in juvenile myoclonic epilepsy. *Epilepsia* 1994;35(2):297–301.
- [9] Asconape J, Penry K. Some clinical and EEG aspects of benign juvenile myoclonic epilepsy. *Epilepsia* 1984;25(1):108–14.
- [10] Delgado-Escueta AB, Enrile-Bascal FE. Juvenile myoclonic epilepsy of Janz. *Neurology* 1984;34:385–94.
- [11] Dreifuss FE. Juvenile myoclonic epilepsy: Characteristics of a primary generalized epilepsy. *Epilepsia* 1989;30(Suppl 4):s1–7.
- [12] Grünewald RA, Dphill A, Panayiotopoulos CP. Juvenile myoclonic epilepsy: A review. *Arch Neurol* 1993;50:594–8.
- [13] Grunewald RA, Chroni E, Panayiotopoulos CP. Delayed diagnosis of juvenile myoclonic epilepsy. *J Neurol Neurosurg Psychiatry* 1992;55:497–9.
- [14] Janz D. Epilepsy with impulsive petit mal (juvenile myoclonic epilepsy). *Acta Neurol Scand* 1985;72:449–59.
- [15] Lancman ME, Asconape JJ, Penry JK. Clinical and EEG asymmetries in juvenile myoclonic epilepsy. *Epilepsia* 1994;35(2):302–6.
- [16] Panayiotopoulos CP, Obeid T, Tahan AR. Juvenile myoclonic epilepsy: A 5 year prospective study. *Epilepsia* 1994;35(2):285–96.
- [17] Lancman ME, Asconape JJ, Golimstok A. Circling seizures in a case of Juvenile myoclonic epilepsy. *Epilepsia* 1994;35:317–8.
- [18] Topcuoglu MA, Saygi S, Ciger A. Juvenile myoclonic epilepsy: an analysis of 100 cases (Abstract). *Epilepsia* 1995;36(suppl 3):S198–9.
- [19] Panayiotopoulos CP, Chroni E, Daskalopoulos C, Baker A, Rowlinson S, Walsh P. Typical absence seizures in adults: Clinical, EEG, video-EEG findings and diagnostic/syndromic considerations. *J Neurol Neurosurg Psychiatry* 1992;55:1002–8.
- [20] So EL, King DW, Murvin AJ. Misdiagnosis of complex absence seizures. *Arch Neurol* 1984;41:640–1.
- [21] Schneider RC, Calhoun HD, Kooi KA. Circling and rotational automatisms in patients with frontotemporal cortical and subcortical lesions. *J Neurosurg* 1971;35:554–63.
- [22] Msylobodsky M, Rosen S. Hemispheric asymmetry of pentylentetrazol-induced wave-spike discharges and motor imbalance in rats. *Epilepsia* 1979;20:377–86.