

Case report
Cortical blindness

J.E. Dalman^a, W.I.M. Verhagen^{a,*}, P.L.M. Huygen^b

^a Department of Neurology, Canisius-Wilhelmina Hospital, PO Box 9015, 6500 GS Nijmegen, Netherlands

^b Department of Otolaryngology, University Hospital Nijmegen, Nijmegen, Netherlands

Received 1 May 1997; received in revised form 1 September 1997; accepted 11 September 1997

Abstract

A 79-year-old woman with persistent cortical blindness caused by bilateral temporo-occipital infarctions was followed for 8 months. She had no light or visual motion perception. Our patient's visual imagery was intact, which was demonstrated when drawing elementary shapes; however, her drawing of objects was poor. Optokinetic nystagmus could not be elicited, but the vestibulo-ocular reflex (VOR) seemed intact. Although she was able to suppress her VOR by 'fixating' her outstretched hand which moved in phase with her head and body, she showed saccadic tracking eye movements in an attempt to visually 'follow' the self-generated movements of her outstretched hand, while her body and head were stationary. Such saccadic tracking seemed to be different from the previously described smooth tracking of self-moved targets by patients with acquired blindness caused by anterior visual pathway dysfunction. © 1997 Elsevier Science B.V.

Keywords: Posterior cerebral artery; Optokinetic nystagmus; Fixation suppression; Brain infarction; Visual imagery

1. Introduction

Complete cortical blindness, which is caused by lesions affecting the geniculostriate pathways, is an uncommon neurological disorder and is rarely persistent. We had the opportunity to examine a patient with complete cortical blindness that proved to be persistent.

2. Case report (patient, methods and results)

A 79-year-old right-handed woman was admitted to our hospital with acute complete loss of vision. She had no headaches, nausea or other complaints. Her medical history included successful cataract extraction from the right eye 2 years previously, diabetes mellitus, hypertension and recurrent cerebral infarctions. Twenty-one

years previously, she had suffered an ischaemic stroke in the right temporal and occipital lobes, which caused left homonymous hemianopsia. She had a second ischaemic stroke 14 years later. Left temporo-central cerebral infarction resulted in right-sided hemiparesis and dysarthria, but she recovered almost completely. Four years later she had another stroke in the right cerebral hemisphere. A cerebral CT scan at that time showed infarctions in the right cerebral hemisphere in the territories of the anterior, middle and posterior cerebral arteries.

On admission, our patient was confused, restless and disorientated in time. There was a conjugate deviation of the eyes to the left. Vision seemed to be absent, although she denied being blind and had visual confabulations. Her pupillary light reflexes were normal, but pursuit eye movements could not be elicited. Cranial nerve functions were otherwise normal. On the left side she had moderate spastic hemiparesis, exaggerated muscle tendon reflexes and an extensor plantar reflex. Our

* Corresponding author. Tel.: +31 24 3658765; fax: +31 24 3658902.

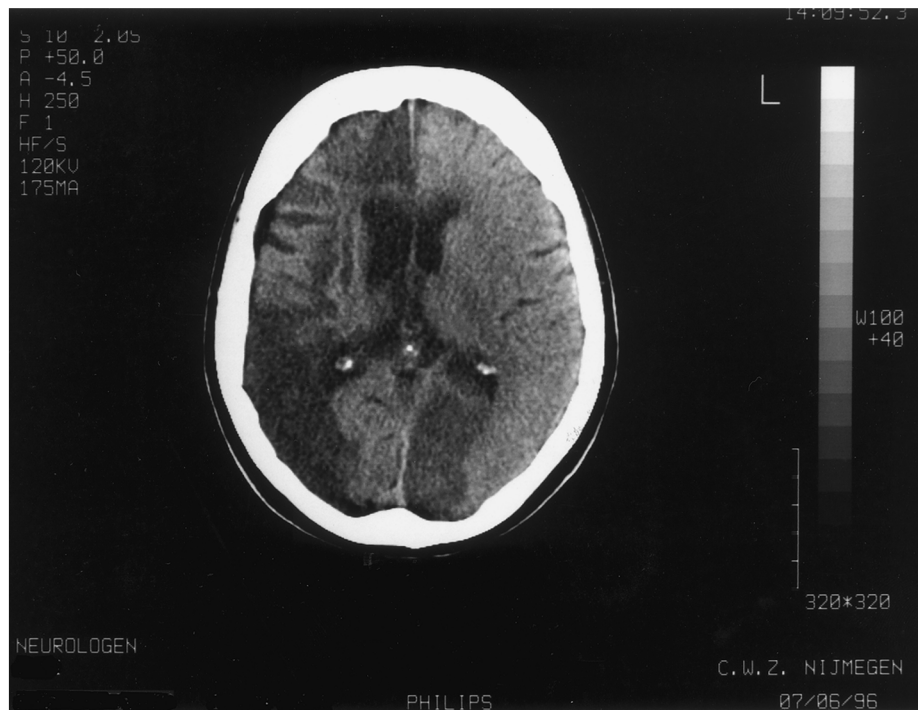
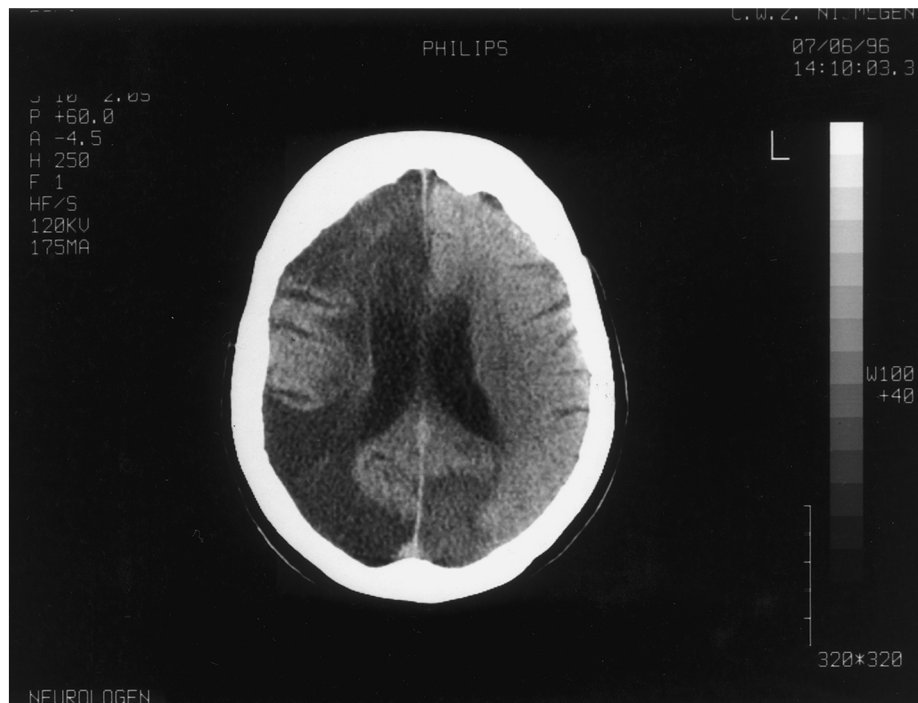
**A****B**

Fig. 1. Brain CT revealed infarctions in the right frontal lobe and in both temporo-occipital lobes.

clinical diagnosis was cortical blindness, probably caused by several, successive cerebral infarctions.

Electro-encephalography showed severe abnormalities over the right cerebral hemisphere. The posterior dominant rhythm was 5–7 Hz on both sides. There was no reaction to photostimulation.

Cerebral CT scans showed bilateral brain infarctions that involved the cuneus on both sides and precuneus on the left side, the lateral occipital gyrus on the right side, the medial and lateral occipitotemporal gyrus, hippocampus and parahippocampal gyrus on the left side, as well as the superior frontal gyrus, cingulum

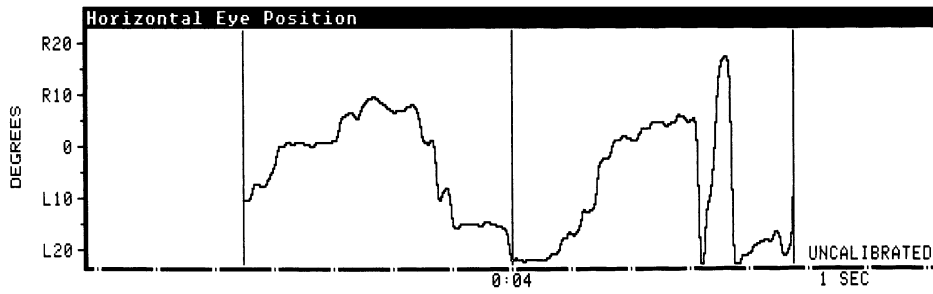


Fig. 2. Eye movement recording of the patient attempting to smoothly track the thumb of her sinusoidally moving outstretched right arm; note the saccades.

gyrus, medial and superior temporal gyrus, supramarginal gyrus, inferior frontal gyrus and angular gyrus occipital on the right side (Fig. 1). Brain MRI was inconclusive because of movement artifacts.

Her optokinetic and vestibular responses were evaluated 6 weeks and 4 months after the onset of cortical blindness. We attempted to calibrate eye movements by letting the patient direct her eyes towards her outstretched hands, while the examiner held her hands so that these subtended an angle of about 20° and touched her index fingers in alternation. She made fairly reproducible saccades, but these overshoot the target, which rendered exact measurements impracticable. We attempted to elicit optokinetic nystagmus (OKN) responses, using monocular or binocular stimulation (stimulus shadow stripes on a video monitor screen covering 32 × 24° in front of the patient) at a velocity of 30°/s (left/right or upward/downward), or during whole body rotation at a constant speed of 40°/s in full light with the eyes open. No OKN could be elicited in either direction and the patient denied seeing any movement.

Although she was able to suppress her VOR by ‘fixating’ her outstretched hand, which moved in phase with her head and body, [1] she showed saccadic tracking eye movements in an attempt to visually ‘follow’ the self-generated movements of her outstretched hand while her body and head were stationary (Fig. 2). Such saccadic tracking seemed to be different from the previously described smooth tracking of self-moved targets in patients with acquired blindness caused by anterior visual pathway dysfunction [1].

The vestibulo-ocular reflex (VOR) was tested with voluntary head shaking, 90°/s velocity step tests and sinusoidal stimulation (frequency 0.05 Hz, peak velocity 50°/s) in the dark and in the light with the eyes open. Each of these tests elicited lively nystagmic responses, but there were no tangible differences between those obtained in full light or complete darkness. We were unable to reliably measure the gain of the VOR, but the responses seemed normal and the decay in nystagmus slow phase velocity after velocity steps indicated a normal time constant [2].

In order to assess different aspects of visual imagery, we tested our patient on different imagery tasks including her drawing capacity, using Dutch test material fairly similar to that described by Chatterjee et al. ([3] for examples of the categories and the type of questions). She performed reasonably well on most items, except for those requiring imagery of directions, angle judgement and ‘colour odd-man-out’ (e.g. the question ‘Which of these three objects are similar in colour: sunflower, cherry and blood?’). Drawing of objects (car, butterfly, clock, house, flower) was very poor (Fig. 3). Drawing of elementary shapes (square, rhomb, triangle and circle) was fairly accurate.

During her period of hospitalization, the patient showed clear immediate and recent memory dysfunction. She had left-right disorientation and remained disorientated in time. Her restlessness improved with




Fig. 3. Drawings by the patient: (A) rhomb; (B) circle; (C) square; (D) house; and (E) tree.

time, but she lacked initiative. Learning abilities were disturbed. Perseveration was evident during a drawing assignment. She was able to perform various activities of daily living, such as washing and dressing herself, eating and drinking. Her vision did not improve during the 4 months in hospital. She was subsequently transferred to a nursing home. There were no signs of improvement 4 months later.

3. Discussion

3.1. General clinical features and prognosis

Cortical blindness (CB) refers to visual loss in the presence of normal pupillary light reflexes, which is caused by bilateral lesions of the visual pathways in the temporo-occipital lobes. The most frequent cause of CB is cerebral vascular disease. In the series described by Aldrich et al. [4], CB had been caused by spontaneous ischaemic stroke in 32%, while Symonds et al. mentioned 25% [5]. Other frequent causes are cardiac surgery and cerebral angiography [4]. In addition to blindness, patients usually show confusion, disorientation and they may have visual hallucinations. They may deny their blindness (Anton's symptom), especially if they have complete visual loss and memory impairment [4], are unable to acquire new knowledge and show some degree of retrograde amnesia. Such memory impairments commonly result from bilateral hippocampal damage. The posterior cerebral artery supplies the medial and basal parts of the temporal lobe including the hippocampus. Usually, the memory disturbances are caused by bilateral lesions, although Brierley mentioned amnesia in unilateral basal temporal lesions [6].

Aldrich et al. found that the prognosis was poor in patients with diabetes mellitus, hypertension, or associated cognitive, language or memory impairments. Patients with bi-occipital CT lesions never showed complete recovery of vision. Prognosis also depended on the cause of CB and proved to be much better in patients with CB following surgery or cerebral angiography, than following a stroke [4].

3.2. Optokinetic nystagmus

Most patients with persistent complete CB have a persistent lack of OKN responses [4,7–12]. As far as we know, only Ter Braak et al. [12] mentioned partial recovery of OKN owing to the possible re-appearance of (diminished) stare OKN in one direction, with a slow build-up of OKN response velocity and (shortlasting) optokinetic after-nystagmus in the same direction. However, although their patient had no spontaneous nystagmus at the time of examination, he had shown spontaneous left-beating nystagmus 1 month previously

and therefore, the possibility of 'arousal' of spontaneous nystagmus cannot be excluded.

3.3. 'Tracking'/'fixating' the outstretched hand

Patients with acquired complete blindness caused by a variety of anterior visual pathway lesions retain the ability to generate smooth eye movements and suppress the VOR by 'tracking' or 'fixating' their outstretched hand [1]. Our patient was also able to suppress the VOR, but unable to smoothly track the self-generated movements of her outstretched hand; she showed saccadic tracking instead. The suppression of the VOR seemed to be in line with good visual imagery and/or a normal somatosensory system; normal subjects are also able to suppress the VOR to a certain extent, probably by the same mechanism. The self-generated saccadic tracking movements demonstrated an intact somatotopic map and intact visual imagery. Steinbach [13] mentioned similar responses with a prominent saccadic component in normal subjects 'tracking' their own moving hand in the dark. Our group observed fairly similar responses in normal subjects who attempted to 'track' one of their knees during cervico-ocular reflex (COR) stimulation, i.e. sinusoidal movement of the body under the fixed head, eyes open in the dark [14]. Although in this respect, our patient behaved in a similar way to normal subjects, it seems difficult to explain why she apparently succeeded in suppressing the VOR but failed to smoothly track her moving hand. There would be no discrepancy if her VOR suppression utilized a similar position-controlling system to her tracking system and did not invoke any velocity control. The limited resolution of electronystagmography, however, does not allow any clear distinction between velocity-controlled and position-controlled VOR cancelling. The apparent discrepancy that a patient with acquired complete blindness caused by anterior pathway pathology was able to smoothly track his outstretched hand [1], while normal subjects [13] and our patient were unable to do so, may be explained by the possibility that the blind patient with longstanding anterior pathway impairment, but intact cortical function and visual imagery, had developed velocity-controlled, i.e. smooth 'tracking' by utilizing somatosensory information, similarly to the development of a smooth COR in monkeys [15] and labyrinthine-defective subjects [14].

3.4. Visual imagery

Our patient's performance on visual imagery tasks seemed to confirm the conclusion of Chatterjee et al. [3] and Goldenberg et al. [16] that the primary visual cortex is not essential for visual imagery. Our data do not support the suggestion made by Farah [17], that the

posterior left quadrant of the brain in particular, is implicated in the ability to generate images because our patient had a clear lesion in that area, but performed reasonably well on visual imagery tasks.

References

- [1] Leigh RJ, Zee DS. Eye movements of the blind. *Invest Ophthalmol Vis Sci* 1980;19:328–31.
- [2] Huygen PLM, Verhagen WIM, Renier WO. Oculomotor and vestibular anomalies in Pelizaeus-Merzbacher disease: A study on a kindred with 2 affected and 3 normal males, 3 obligate and 8 possible carriers. *J Neurol Sci* 1992;113:17–25.
- [3] Chatterjee A, Southwood MH. Cortical blindness and visual imagery. *Neurology* 1995;45:2189–95.
- [4] Aldrich MS, Alessi AG, Beck RW, Gilman S. Cortical blindness: Etiology, diagnosis and prognosis. *Ann Neurol* 1987;21:149–58.
- [5] Symonds C, Mackenzie I. Bilateral loss of vision from cerebral infarction. *Brain* 1957;80:415–55.
- [6] Brierley JB. The neuropathology of amnesic states. In: Whitty CWM, Zangwill OL, editors. *Amnesia*. London: Butterworths, 1966:150–180.
- [7] Sadeh M, Goldhammer Y, Kuritsky A. Postictal blindness in adults. *J Neurol Neurosurg Psychiatry* 1983;46:566–9.
- [8] Celesia GG, Bushnell D, Toleikis SC, Brigell MG. Cortical blindness and residual vision: Is the 'second' visual system in humans capable of more than rudimentary visual perception? *Neurology* 1991;41:862–9.
- [9] Brindley GS, Gautier-Smith PC, Lewin W. Cortical blindness and the functions of the non-geniculate fibres of the optic tracts. *J Neurol Neurosurg Psychiatry* 1969;32:259–64.
- [10] Veizeboer CMJ. Bilateral cortical hemianopsia and optokinetic nystagmus. *Ophthalmologica*, (Basel) 1952;123:187–8.
- [11] Kurtz D, Waydelich-Fletto R, North P, Rohmer F. Étude clinique et E.E.G. de 9 cas de cécité corticale. *Rev Electroencephalogr Neurophysiol* 1977;7:133–8.
- [12] Ter Braak JWG, Schenk VWD, Van Vliet AGM. Visual reactions in a case of long-lasting cortical blindness. *J Neurol Neurosurg Psychiatry* 1971;34:140–7.
- [13] Steinbach MJ. Pursuing the perceptual rather than the retinal stimulus. *Vis Res* 1976;16:1371–6.
- [14] Huygen PLM, Verhagen WIM, Nicolassen MGM. Cervico-ocular reflex enhancement in labyrinthine defective and normal subjects. *Exp Brain Res* 1991;87:457–64.
- [15] Dichgans J, Bizzi E, Morasso P, Tagliasco V. Mechanisms underlying recovery of eye-head coordination following bilateral labyrinthectomy in monkeys. *Exp Brain Res* 1973;18:548–62.
- [16] Goldenberg G, Müllbacher W, Nowak A. Imagery without perception. A case study of anosognosia for cortical blindness. *Neuropsychologia* 1995;33:1373–82.
- [17] Farah MJ. The neurological basis of mental imagery: A componential analysis. *Cognition* 1984;18:245–72.