

C. L. Merten
H. O. Knitelius
J.-P. Hedde
J. Assheuer
H. Bewermeyer

Intracerebral haemorrhage from a venous angioma following thrombosis of a draining vein

Received: 17 October 1996
Accepted: 14 May 1997

C. L. Merten · J. Assheuer ·
H. Bewermeyer (✉)
Krankenhaus Merheim,
Department of Neurology,
Ostmerheimerstrasse 200,
D-51109 Cologne, Germany
Tel. 02 21/89 07-27 75; fax 02 21/89 07-27 72

H. O. Knitelius · J.-P. Hedde
Krankenhaus Merheim,
Department of Radiology,
Ostmerheimerstrasse 200,
D-51109 Cologne, Germany

Abstract We report a case of putaminal haemorrhage from a venous cerebral angioma following thrombosis in a draining vein. The patient complained of numbness of the right side, followed by headache and aphasia. CT demonstrated an intracerebral haemorrhage due to thrombotic occlusion of a draining vein of the venous angioma. Carotid angiography showed the venous angioma. MRI studies confirmed the diagnosis and demonstrated recanalisation of the draining vein following therapy with phenprocoumon.

Key words Venous cerebral angioma · Intracerebral haemorrhage

Introduction

In a series of autopsies, venous angiomas in the brain were found in 0.25 %. These developmental anomalies (DVA) make up 42 %–63 % of cerebral vascular malformations [1, 2]. Unlike arteriovenous malformations and to a lesser extent cavernomas, DVA rarely produce symptoms and in most cases are therefore diagnosed by chance.

Case report

A 50-year-old woman suddenly developed a feeling of numbness in her right foot that extended within minutes to the entire right side of her body. The next day, she complained of headache and became aphasic. On examination 3 days after the onset of symptoms she was found to have hypoaesthesia of the right side and a Broca's aphasia.

CT revealed a haematoma in the left putamen and dense, dilated transcerebral veins draining into an enlarged Sylvian vein (Fig. 1 a, b). Alongside the cella media of the left lateral ventricle

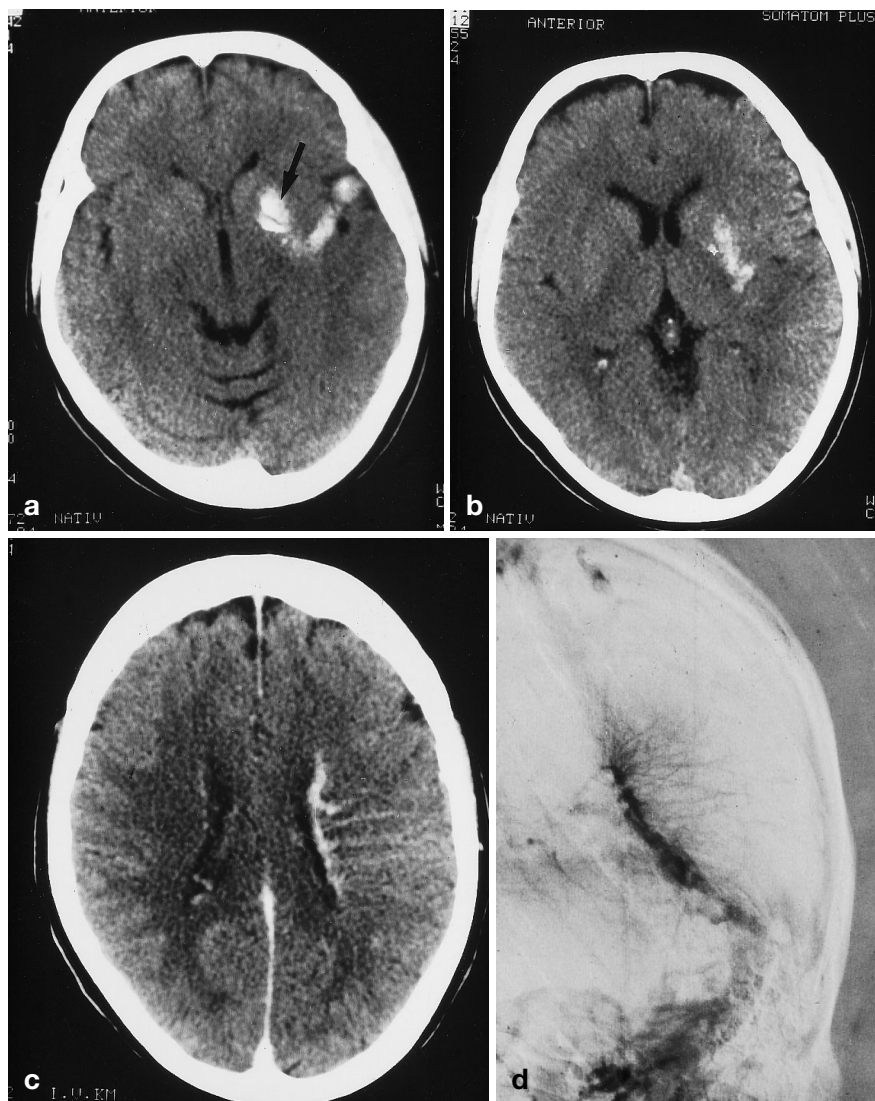
atypical vessels and dense vascular structures running through the white matter and basal ganglia to the sylvian fissure were identified. After contrast medium, these dilated medullary veins appeared as a "Caput Medusae" (Fig. 1 c). At carotid angiography, the arterial phase revealed no abnormality. In the late venous phase, dilated medullary veins were seen in the left paraventricular region, draining into a large atypical vein. The contrast medium had not drained away 30 s after injection (Fig. 1 d).

MRI showed a draining vein which gave high signal on T1-, proton density- and T2-weighted sequences, indicating a thrombosed vessel (Fig. 2). It was therefore concluded that the haematoma in the left putamen had been caused by haemorrhage from the venous angioma following thrombosis in a large draining vein. No associated cavernoma was found.

The patient's neurological disorder resolved within 4 weeks. After initial treatment with intravenous heparin, she was given anticoagulant therapy with phenprocoumon. CT showed complete resorption of the haematoma.

MRI was repeated 8 months later. The dilated veins identified in the earlier studies had significantly decreased in size. The draining vein gave low signal on the T1-weighted spin-echo images, demonstrating recanalisation (Fig. 3). Residual haemosiderin was identified in the left putamen.

Fig. 1 **a, b** CT demonstrates a small haematoma in the putamen (*arrow*) and dense, dilated transcerebral veins draining into an enlarged sylvian vein. **c** Contrast-enhanced CT shows dilated medullary veins in the left cerebral hemisphere converging towards a subependymal vein. **d** Frontal projection of late venous phase of left carotid arteriography demonstrates persistent filling of dilated medullary, subependymal and transparenchymal veins with a typical “caput Medusae” appearance



Two years after the cerebral haemorrhage, the patient had recovered completely and treatment with phenprocoumon was discontinued.

Discussion

Cerebral venous angiomas differ from malformations such as arteriovenous malformations and from cavernomas. They have a tuft- or featherlike structure (“Caput Medusae”) and can be considered as a developmental variation of the normal cerebral venous system [3]. The main diagnostic criterion is large transparenchymal veins draining into large subependymal or subarachnoid vessels.

DVA may be shown in patients being investigated for epileptic seizures, and signs of cerebral ischaemia may be

shown on imaging [4–7]. It used to be assumed that cerebral haemorrhage was not infrequently caused by venous angiomas [8, 9]. At the present there is controversy as to whether DVA can in fact be incriminated for cerebral haemorrhage. Cerebral haemorrhage is often ascribed to be due to cerebral cavernomas, present in 33–48% of cases of DVA [4, 10]. Cerebral cavernomas are often not seen on CT or angiography, but can be reliably detected by MRI [4, 11]. Thus, attribution of cerebral haemorrhage to a DVA may have been mistaken if the diagnosis had been made exclusively by angiography or CT [9].

In this case, no cavernoma was shown by MRI. Therefore, the haemorrhage was probably due to haemorrhage from the DVA following thrombosis of its principal vein and a resultant increase in pressure within it. The progression of symptoms could be interpreted in the light of a slowly developing thrombus in the draining

Fig. 2 **a** Unenhanced T1-weighted coronal spin-echo MRI confirms thrombosis of the superficial draining vein. **b** Gadolinium-enhanced coronal MRI demonstrates the entire DVA

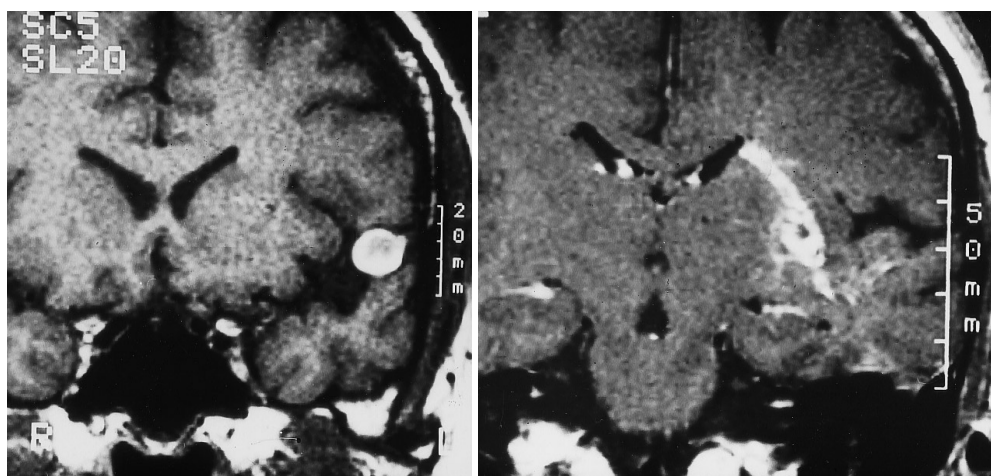
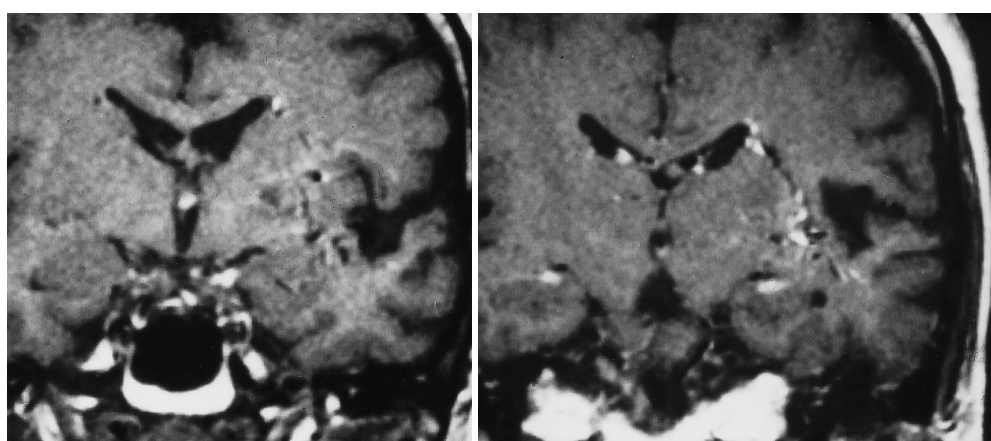


Fig. 3 MRI 8 months after Fig. 2. **a** Coronal T1-weighted image: there has been a decrease in signal intensity in the draining vein, indicating recanalisation. **b** Contrast-enhanced image demonstrates reduction in size of the lumina of all the atypical veins, compatible with recanalisation of the draining vein



vein and haemorrhage from the DVA when this vein was almost totally occluded; the patient did not suffer from a coagulopathy which could have induced venous thrombosis. DVA consist of thickened, hyalinised veins whose walls contain hardly any smooth muscle cells or elastic connective tissue [12]. This abnormal structure and the slow drainage of blood are perhaps the reasons for an increased risk of thrombosis, even in the absence of a coagulopathy.

There is no formally established therapy for DVA. It is generally acknowledged that asymptomatic DVA

need not be treated. Some workers recommend surgical removal if haemorrhage has occurred [9], but extirpation of a DVA will interfere with the draining of blood from the adjacent cerebral parenchyma. We therefore consider surgical treatment dangerous, as fatal post-operative cerebral infarction has been reported [13, 14]. Our patient's clinical progress was satisfactory. CT and MRI showed resorption of the intracerebral haematoma, and MRI showed recanalisation of the draining veins.

References

1. Jellinger K (1986) Vascular malformations of the central nervous system: a morphological overview. *Neurosurg Rev* 9: 177–216
2. Sarwar M, McCormick WF (1978) Intracerebral venous angioma. Case report and review. *Arch Neurol* 35: 323–325
3. Lasjaunias P, Burrows P, Planet C (1986) Developmental venous anomalies (D. V. A): the so-called venous angioma. *Neurosurg Rev* 9: 233–244
4. Huber G, Piepgras U, Henkens H, Faubert C (1991) Venenanomalien des Gehirns. *Radiologie* 31: 274–282
5. Bouchacourt E, Carpena JP, Bories J, Koussa A, Chiras J (1986) Accident ischémique par thrombose d'un angiome veineux. A propos d'un cas. *J Radiol* 67: 631–635
6. Burke L, Berenberg RA, Kim KS (1984) Choreoballismus: a nonhemorrhagic complication of venous anomalies. *Surg Neurol* 21: 245–248

7. Pelz DM, Viñuela F, Fox AJ (1983) Unusual radiologic and clinical presentations of posterior fossa venous angiomas. *AJNR* 4: 81–84
8. Handa H, Morikake K (1985) Venous angiomas of the brain. In: Fein JM, Flamm ES (eds) *Cerebrovascular surgery*, vol 4 Springer, New York, pp 1139–1149
9. Malik GM, Morgan JK, Boulos RS (1988) Venous angiomas: an underestimated cause of intracranial hemorrhage. *Surg Neurol* 30: 350–358
10. Ostertun B, Solymosi L (1993) Magnetic resonance angiography of cerebral developmental venous anomalies: its role in differential diagnosis. *Neuroradiology* 35: 97–104
11. Lasaunias P, Terbrugge K, Rodesch G, Willinsk R, Burrows P, Pruvost PH, Piske R (1989) Vrais et fausses lésions veineuses cérébrales: pseudoangiomes veineux et hémangiomes caverneux. *Neurochirurgie* 53: 132–139
12. McCormick WF (1966) The pathology of vascular (“arteriovenous”) malformations. *J Neurosurg* 24: 807–816
13. Biller J, Toffol GJ, Shea JF, Fine M, Behrooz AK (1985) Cerebellar venous angiomas: a continuing controversy. *Arch Neurol* 42: 367–370
14. Senegor M, Dohrmann GJ, Wollmann RL (1983) Venous angiomas of the posterior fossa should be considered anomalous venous drainage. *Surg Neurol* 19: 26–32

BOOK REVIEW

Stroke: A practical guide to management. Eds: C. P. Warlow, M. S. Dennis, J. van Gijn, et al. 1996, Blackwell Science, ISBN 0-86542-874-3 HB, £ 99.50

It was a pleasure for me to read and review this book. This is a very important book. The editors state that the purpose was to write a problem-orientated book about stroke. As pointed out in the foreword by HJM Barnett, the authors (all innovative in the stroke field) have written this book to assist us at the bedside or in the clinic “in

sorting out what is truly valuable, to point out what is likely to become valuable and to caution about therapeutic strategies which remain in the realm of speculation”. I am convinced that the authors have succeeded in this goal.

Instead in the typical manner of a multi-author book with the common custom of collecting a series of chapters written in many different individual styles the authors have together written a book in such a way, that each chapter is influenced by the knowledge and ideas of every author.

In order to enable the reader to manage stroke patients at different stages of their disease this book covers every facet of care in stroke patients. The text is written

well formulated and succinct. It is very useful, that the contents are listed at the beginning of every chapter. The bibliography offers a broad selection of current references. CT and MR-images are well integrated in the text, the image-quality is good to excellent. Most of the sketches are very helpful to make images understandable.

The authors deserve congratulations for their impressive achievement. I am convinced that this will be a standard textbook for neurologists, neuroradiologists, neurosurgeons and for anyone else who wants practical guidance about all and any of the problems to do with stroke.

H. Brückmann, Munich