

Coexistence of Primary Antiphospholipid Syndrome and Protein S Deficiency in a Hispanic Man With Ischemic Stroke

YOLANDA REYES-IGLESIAS, MD, ARTURO A. ORTIZ, MD, DARÍO M. GOITÍA, MD, and RAFAEL MELÉNDEZ, MD, San Juan, Puerto Rico

ABSTRACT: The primary antiphospholipid syndrome and protein S deficiency are known hypercoagulable states predisposing to ischemic strokes. The pathogenesis of those hypercoagulable states has been independently studied and, recently, interaction between them has been proposed. A 48-year-old Hispanic man had generalized seizures 5 months after the acute onset of a left middle cerebral artery infarct. He had a strong family history of strokes. After evaluation for cardiologic, rheumatologic, hematologic and metabolic etiologies for stroke, anticardiolipin antibodies and protein S deficiency were detected. Cerebral angiography was normal. First degree relatives were evaluated and screened for these conditions. Lupus anticoagulant was detected in a sister who reported a transient hemisensory deficit. None of the relatives studied had clinical or laboratory criteria for collagen vascular diseases. Coexistence of the primary antiphospholipid syndrome and protein S deficiency, two known prothrombotic states, has rarely been reported in Hispanic adults in association with ischemic stroke.

ANTIPHOSPHOLIPID ANTIBODIES currently recognized are the lupus anticoagulant and anticardiolipin antibodies.¹⁻³ These are circulating immunoglobulins associated with a prothrombotic state. These antibodies were initially described in association with collagen vascular diseases.⁴ The primary antiphospholipid syndrome (PAS) is a hypercoagulable state due to the presence of lupus anticoagulant and/or anticardiolipin antibodies without an underlying collagen vascular disease or other autoimmune diseases. This entity has been established as an independent risk factor for ischemic stroke and is an important etiology of stroke in young adults.⁵ Several cases of familial occurrence of the PAS have been reported. Despite extensive studies on these antibodies, their exact pathogenesis has not been established. Several mechanisms have been proposed including interference with the protein C-S anticoagulation system.⁶ An association between free protein S deficiency (PSD) and antiphospholipid antibodies has

been documented recently in patients with systemic lupus erythematosus, human immunodeficiency virus (HIV-1) and early childhood.⁷⁻⁹

We describe a family with ischemic strokes, not associated to collagen vascular diseases or HIV-1, where the possible interaction between the PAS and PSD may be illustrated.

CASE REPORT

A 48-year-old right-handed Hispanic man with recently diagnosed hypertension and no toxic habits was admitted to our service, due to the acute onset of generalized seizures, 5 months after a left middle cerebral artery infarct was diagnosed in a previous hospitalization. The general physical examination was normal. The neurologic examination revealed an alert mental status, a mild right hemiparesis (grade 4/5), an expressive aphasia, and a right Babinski sign. Cardiac evaluations including electrocardiogram and 2D-transthoracic echocardiography were normal. Brain computed tomography (CT) scan and magnetic resonance imaging (MRI) revealed an old left middle cerebral artery territory ischemic infarct (Fig 1). Cerebral arteriography was normal. Complete blood count, routine serum chemistries, prothrombin time, and partial thromboplastin time were within normal limits. Sedimentation rate was at 61 mm/hr (Westergren method). Electroencephalogram revealed focal slowing over the left frontoparietal region, without epileptogenic discharges. The family history revealed several members affected by ischemic strokes, which prompted a thorough evaluation for inherited etiologies of stroke in our patient. Gamma G immunoglobulin (IgG) anticardiolipin antibodies were detected at 20.1 g-phospholipid levels (GPL) units

From the Department of Medicine, Neurology Section, Veterans Administration Medical Center and University of Puerto Rico School of Medicine, San Juan.

Reprint requests to Yolanda Reyes-Iglesias, MD, Department of Medicine, Neurology Section, One Veterans Plaza, San Juan, Puerto Rico 00927-5800.

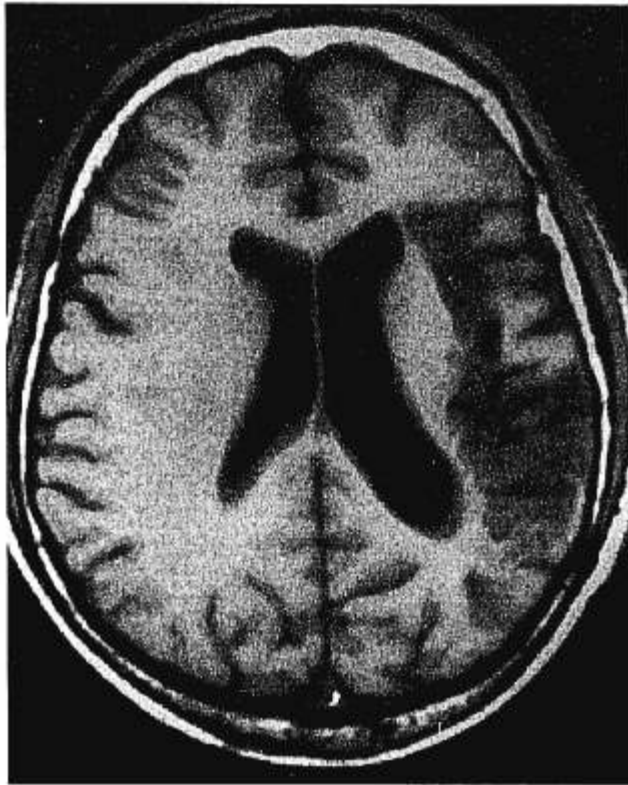

FIGURE 1. Axial T1- and T2-weighted magnetic resonance images show left middle cerebral artery territory infarction. No significant periventricular hyperdensities were noted.

(normal, 0 to 11.9, Roche Laboratories, NC) and free protein S level was decreased at 53% (normal, >78%, Roche). Total protein S was >100% (normal, >79%, Roche). Lupus anticoagulant was negative (Roche). Serum venereal disease research laboratories (VDRL) and antinuclear antibodies (ANA) titers were negative. Protein C antigen and antithrombin III levels were normal. Hemoglobin electrophoresis, lactate levels, lipid profile, and a 24-hour urinary cysteine collection were within normal limits. Liver function tests, renal function, and human immunodeficiency virus (HIV) testing were negative. Serum α -galactosidase levels were normal. Routine cerebrospinal fluid values were within normal limits and no oligoclonal bands were detected. The patient was treated with enalapril, ticlopidine and phenytoin. IgG anticardiolipin antibodies and free protein S deficiency were still present 6 months after the initial testing at 58.4 GPL units and 56%, respectively. At this time, total protein S level was at 90%.

After diagnosis of the PAS and PSD in our index case, we screened several first-degree relatives for these conditions (Fig 2). Other tests included complete blood count, serum chemistries, lipid profile, ANA and VDRL titers, sedimentation rate, sickle cell preparation, and antithrombin III levels. Neurologic examinations were done and no neurologic deficits were found in any of the members examined. One sister reported a transient right-sided numbness lasting a few minutes, several months before our evaluation. She was found with a positive lupus anticoagulant test (Nichols Institute, Calif). She had no history of miscarriages or thromboses. All members tested had a brain CT scan to evaluate for subclinical cerebrovascular disease and all scans were unremarkable. None of the members tested was found with clinical or laboratory features of collagen vascular diseases.

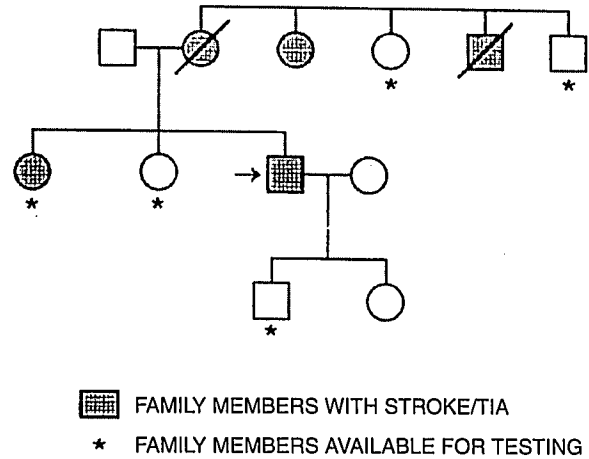


FIGURE 2. Pedigree of family.

DISCUSSION

Antiphospholipid antibodies are known to induce a prothrombotic state through a still undefined mechanism. Several possibilities have been proposed. Interference with activation of coagulation factors X, XI, and XII at phospholipid dependent steps has been suggested. Inhibition of prothrombinase complex¹⁰, inhibition of endothelial prostaglandin I_2 ,¹⁰ and binding of the lupus anticoagulant to β_2 -glycoprotein 1 (apoprotein H) are other proposed mechanisms. Finally, an association between the protein C-S pathway and the presence of antiphospholipid antibodies in patients with systemic lupus erythematosus has been reported.⁴ In our case, it would be unlikely that the anticardiolipin antibodies were an epiphenomenon of stroke since they were first detected 5 months after the initial ischemic infarct and before the patient was started on phenytoin.

The protein C-S pathway is a vitamin K-dependent anticoagulant system.¹⁰⁻¹² Intravascular thrombosis is prevented through this system, together with antithrombin III and the fibrinolytic system. The active protein C inactivates coagulation factors Va and VIIIa, in the presence of the cofactor protein S and phospholipid membranes. Protein S exists in an active free fraction, and in an inactive fraction bound to complement C4b binding protein.¹³ Familial and acquired forms of protein S deficiency have been described. Acquired forms have been described in patients receiving warfarin therapy, and in those with the nephrotic syndrome, severe liver disease, disseminated intravascular coagulation, and HIV infection,^{5,14} among others. Several studies have reported reduced free protein S levels in

patients with collagen vascular diseases and antiphospholipid antibodies.^{2,4,7,15} In our patient, the decrement in free protein S level was consistent and persisted up to 11 months after the stroke. Family screening favored an acquired pattern of protein S deficiency in our patient, although an autosomal recessive inheritance cannot be totally excluded.

Our patient was an adult Hispanic man with an ischemic stroke and coexistence of the primary antiphospholipid syndrome and protein S deficiency. Protein S deficiency has been described in a woman with human T-cell lymphotropic virus type I (HTLV-I) without antiphospholipid antibodies.¹⁶ The possibility of interaction between these two prothrombotic states in the setting of systemic lupus erythematosus (SLE) and HIV-infected patients as a mechanism of thrombosis has already been suggested. In patients with SLE, a blood component binding to protein S and inactivating it has been proposed.⁴ In HIV-1 infected patients, there is an increased incidence of anti-protein S autoantibodies.¹⁷ Our patient did not have any autoimmune process making the coexistence of antiphospholipid antibodies and protein S deficiency more relevant. The binding of antiphospholipid antibodies to protein S interfering with its function is a possibility that requires further testing. In an earlier study, the presence of anticardiolipin antibodies seemed to be related to acquired deficiencies of total protein S, free protein S, and C4b binding protein.¹⁸ Further studies on these coexistent prothrombotic states are needed to establish whether the free protein S deficiency is independent, acts synergistically, or occurs due to the presence of antiphospholipid antibodies.

References

1. Levine SR: Antiphospholipid syndromes and the nervous system: clinical features, mechanisms, and treatment. *Semin Neurol* 1994; 14:168-178
2. Nigel-Harris E: Annotation: antiphospholipid antibodies. *Br J Haematol* 1990; 74:1-9
3. Cevera R, Asherson RA, Lie JT: Clinicopathologic correlations of the antiphospholipid syndrome. *Semin Arthritis Rheum* 1995; 24:262-272
4. Love PE, Santoro SA: Antiphospholipid antibodies: anticardiolipin and the lupus anticoagulant in systemic lupus erythematosus (SLE) and in non-SLE disorders. *Ann Intern Med* 1990; 112:682-698
5. Antiphospholipid Antibodies in Stroke Study Group: Clinical and laboratory findings in patients with antiphospholipid antibodies and cerebral ischemia. *Stroke* 1990; 21:1268-1273
6. Parke AL, Weinstein RE, Bona RD, et al: The thrombotic diathesis associated with the presence of phospholipid antibodies may be due to low levels of free protein S. *Am J Med* 1992; 93:49-56
7. Ginsberg JS, Demers C, Brill-Edwards P, et al: Acquired free protein S deficiency is associated with antiphospholipid antibodies and increased thrombin generation in patients with systemic lupus erythematosus. *Am J Med* 1995; 98:379-383
8. Hassell KL, Kressin DC, Newmann A, et al: Correlation of antiphospholipid antibodies and protein S deficiency with thrombosis in HIV-infected men. *Blood Coagul Fibrinolysis* 1994; 5:455-462
9. Couper RTZ, Maxwell FC: Anticardiolipin and acquired protein S deficiency in early childhood. *J Pediatr Child Health* 1994; 30:363-365
10. Nachman RL, Silverstein R: Hypercoagulable states. *Ann Intern Med* 1993; 119:819-827
11. Hart RG, Kanter MC: Hematologic disorders and ischemic stroke: a selective review. *Stroke* 1990; 21:1111-1121
12. High KA: Antithrombin III, protein C, and protein S: naturally occurring anticoagulant proteins. *Arch Pathol Lab Med* 1988; 112:28-36
13. Ruíz-Argüelles GJ, Ruíz-Argüelles A, Alarcón-Segovia D, et al: Natural anticoagulants in systemic lupus erythematosus: deficiency of protein S bound to C4bp associates with recent history of venous thromboses, antiphospholipid antibodies, and the antiphospholipid syndrome. *Rheumatology* 1991; 18:552-558
14. Sacco RL, Owen J, Mohr JP, et al: Free protein S deficiency: a possible association with cerebrovascular occlusion. *Stroke* 1989; 20:1657-1661
15. Malia RG, Kitchen S, Greaves M, et al: Inhibition of activated protein C and its cofactor protein S by antiphospholipid antibodies. *Br J Haematol* 1990; 76:101-107
16. Schwartz J, González J, Rosenberg R, et al: Cutaneous T-cell lymphoma, tropical spastic paraparesis, cerebral vasculitis and protein S deficiency in a patient with HTLV-I. *South Med J* 1996; 89:999-1000
17. Lafeuillade A, Sorice M, Griggi T, et al: Role of autoimmunity in protein S deficiency during HIV-1 infection. *Infection* 1994; 22:201-203
18. Forastiero RR, Kordich L, Basilotta E, et al: Differences in protein S and C4b-binding protein levels in different groups of patients with antiphospholipid antibodies. *Blood Coagul Fibrinolysis* 1994; 5:609-616