

this laboratory succeeded in preparing a monoclonal antibody (BC-1) specific for oncofetal FN, an isoform characterised by a peculiar sequence (ED-B) in the central part of its molecule. On the other side, different monoclonal antibodies were prepared, which are either able to recognise all FN isoforms (IST-4), or are specific for FNs that do not contain oncofetal sequence (IST-6).¹ A previous study, in which all these monoclonal antibodies were employed showed that, whereas FNs are widely distributed in the endothelia of human gliomas, the occurrence of the oncofetal isoform correlates with the degree of malignancy. Similarly, the expression of the oncofetal FN in the vascular endothelium of benign meningiomas was found to be restricted,² by contrast with the findings reported here.

Preliminary findings by using the Tc-99m-labelled anti-oncofetal FN monoclonal antibody BC-1, that was administered intravenously, showed that this monoclonal antibody does reach malignant meningiomas in vivo, as well as malignant gliomas, allowing scintigraphic evidence of the tumour and providing a possible basis for vascular targeting.¹ In this regard, it can be speculated that administration of tumoricidal radionuclides linked to monoclonal antibody BC-1 might prove to be able to selectively destroy endothelia of meningeal malignancies, while sparing the normal vessels of the brain, and to favourably affect the course of the illness in terms of recurrence rate.

This study was partially supported by the National Research Council (CNR), AIRC, and the Ministry of University and Scientific Research (MURST). We thank Mr Sergio Deseri for his technical help in the preparation of the manuscript.

ANTONIO PAU
LUCA BRUZZONE
ALESSANDRA DORCARATTO
GIUSEPPE VIALE

Division of Neurosurgery, University of Genoa Medical School, Genoa, Italy

GIULIANO MARIANI
Department of Internal Medicine, Nuclear Medicine Service, University of Genoa Medical School, Genoa, Italy

PATRIZIA CASTELLANI
ANNALISA SIRI
LUCIANO ZARDI
Laboratory of Cell Biology, Istituto per la Ricerca sul Cancro, Genoa, Italy

Correspondence to: Dr Antonio Pau, Clinica Neurochirurgica dell'Università degli Studi Ospedale S. Martino Largo Rosanna Benzi, 10 16132 Genova, Italia. Telephone 039 10 3537610; fax 039 10 352104.

- 1 Carnemolla B, Balza E, Siri A, *et al.* A tumor associated fibronectin isoform generated by alternative splicing of messenger-RNA precursors. *J Cell Biol* 1989;108:1139-48.
- 2 Castellani P, Viale GL, Dorcaratto A, *et al.* The fibronectin isoform containing the ED-B oncofetal domain: a marker of angiogenesis. *Int J Cancer* 1994;59:612-8.
- 3 Chamberlain MC. Adjuvant combined modality therapy for malignant meningiomas. *J Neurosurg* 1996;84:733-6.
- 4 Mariani G, Lasku A, Villa G, *et al.* A pilot pharmacokinetic and immunoscintigraphic study with the 99m Tc- labeled monoclonal antibody BC-1 in patients with brain tumors. *J Nuclear Medicine* 1996;37:238.
- 5 Sternberger LA, Shirley AJ. The unlabeled-antibody method. *J Histochem Cytochem* 1979; 27:1424-9.

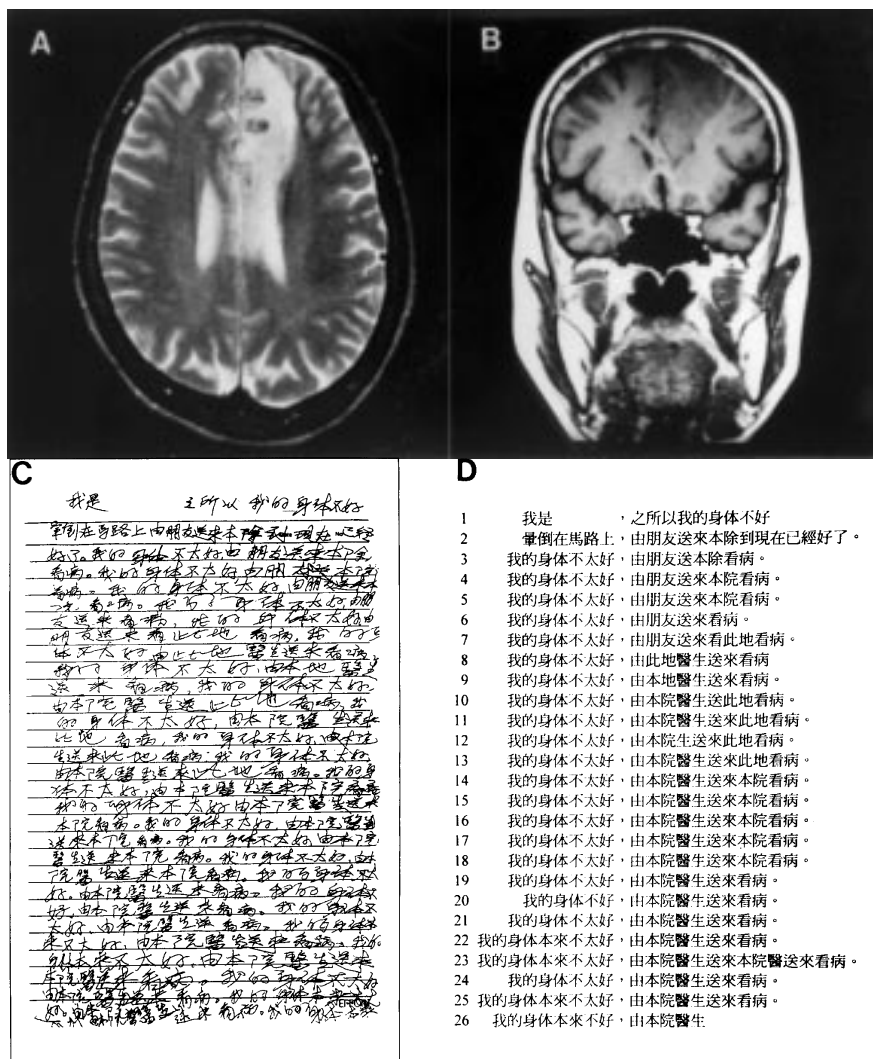
Repetitive sentence writing after a left anterior cerebral artery infarct

Patients with cerebral lesions out of motor and sensory strips are often overlooked, especially those with frontal lobe symptoms, which are subtle and elusive. We report on a patient with a left anterior cerebral artery infarct, who had an unusual manifestation—namely, repetitive sentence writing.

A 58 year old right handed woman had a transient lapse of consciousness when riding a bicycle on 3 June 1995. She had no vomiting, convulsion, or sphincter problems, and walked home after having taken a rest. Brain CT performed at a local hospital was normal. Next day, she visited our hospital because of right leg weakness, urinary urgency, persistent mutism, and slow mentality. On admission, the patient seemed alert and had normal vital signs, but was mute and responded slowly to oral commands. Neurological examination disclosed a grasp reflex on both hands, being stronger on the right, gegenhalten rigidity, right leg weakness, and clonic motor perseveration of the right hand. With the right hand, she would hit the bed, her own body, cutlery, and nearby objects before her. She knocked herself on the head if we asked her: "Do you have a headache?", and on the leg if we asked her: "Do you have leg pain?". The clonic motor perseveration stopped when she held objects, made a fist, changed posture, or restrained the right hand with the

left one, but would recur several seconds later. It never ceased for long unless she fell asleep. On her second day in hospital, she was still abulic, mute, and indifferent. She used a toothbrush, chopsticks, towels, and fastened and undid buttons normally. On the fourth day, the frequency and the amplitude of the clonic motor perseveration decreased. She laughed, displayed more facial expressions, and pronounced an "e" sound. On the 11th day, she began to communicate with her family by writing. Next day, she spoke a complete sentence to complain about the noise made by the neighbouring patient, which was the only one sentence she had spoken since her admission. Brain MRI on the 13th day showed a left anterior cerebral artery infarct (figure A, B).

Neuropsychological tests were done from day 6 to 11. The patient had had a high school education. She had no spontaneous speech and could not repeat even simple words, but her verbal comprehension was intact and she could correctly name real objects and photographs of them. She performed line bisection and cancellation tasks very well. On day 11, the patient wrote about her illness on request (figure C), although she was still mute. The handwriting was legible and we easily transcribed it to a printed form (figure D). Initially, she wrote quite normally, "I am....My physical condition is not good and (I had) a syncope on the road, and was sent to this hospital by a friend.



Cerebral MRI; (A) axial T2 weighted, TR 2500, TE 90 ms; (B) coronal T1 weighted, TR 600, TE 15 ms showing a left mesial frontal lesion; (C) patient's original penmanship; (D) transcription of (C).

Now I am well" (figure D, the first and second lines). In figure D, the seventh character right of the comma on the second line (we defined as L2R7) and L3R6 should be L4R7, which is an orthographic paraphria. Then, she began to rewrite sentences from L3, although not exactly identical. These repetitive sentences were divided into two clauses by a comma. The first clause said, "My physical condition is not very good", which she repeated 17 times (L3 to L19). The second clause said, "(I) was sent to this hospital by a doctor of this hospital". There were several minor errors in the second clauses, including character omissions (between L3R4 and L3R5, L10R6 and L10R7, and L12R3 and L12R4) and redundant characters (at L7R6 and L23R10 to R12). She changed "friend" (L3R2 and L3R3) to "doctor" (L8R4 and L8R5) and unnecessarily repeated the modifier "this hospital" twice (L14R2 and L14R3 as well as L14R8 and L14R9). She wrote five identical copies of a long sentence (L14 to L18 of figure D). She stopped writing when the space on the paper was used up.

Our patient was discharged on the 14th day. Her husband reported that on the 17th day she watered flowers, but played with the water at the same time. She rapped kitchen utensils with a spatula when cooking, and rapped bowls with a spoon when eating. Three days later, she began to repeat phrases, and followed events in the stock market on television. However, she became angry with her husband without reason on the 21st day, which was unprecedented. On the 26th day, her verbal output seemed normal. The clonic motor perseveration subsided gradually and eventually stopped.

Most of this patient's symptoms had been described elsewhere.¹ The repetitive writing had been reported only for letters, characters, and phrases.² To our knowledge, repetition of a long meaningful sentence has never been reported. Our patient seemed totally involved when writing the sentences, and would not be distracted. Furthermore, the clonic motor perseveration and the repetitive sentence writing showed similarities in that both were repetitive and elicited by a stimulus. The clonic motor perseveration was elicited by nearby objects attracting her, and the repetitive sentence writing by an idea to describe her illness.

Regarding our patient's ability to write while she was mute, we suggest two points. Firstly, her inner language was intact. This resembles "dynamic aphasia" with which patients seem almost mute in conversational speech, but show a dramatic preservation of the ability to name objects, to read, and to repeat sentences.³ Kleist thought that patients with dynamic aphasia had intact verbal propositional thought and intact "sentence schema" but these were disconnected.⁴ Our patient wrote sentences with correct grammar and word selection to describe a meaningful idea, which supports this notion. Secondly, the mechanism for writing was intact. The neural substrates accounting for writing were unaffected in our patient, as shown by the proper sentence syntax and legible ideograms.

Dominant mesial frontal lesion may impair the processes of modification and monitoring of the motoric components of writing, resulting in disinhibition and loss of monitoring. Moreover, Shallice⁵ proposed an idea of "supervisory attentional system" which controls and modulates the lower level processes.

This system is activated when a person is dealing with a non-habitual condition and is thought to be a frontal lobe function. This explains why our patient rewrote the sentences so many times, yet did not detect the errors in the writing.

We thank Professor Atsushi Yamadori of Tohoku University, Japan for his helpful comments in the preparation of this manuscript.

MING-CHYI PAI
ING-JER HUANG

Division of Behavioral Neurology, Department of
Neurology, National Cheng Kung University Hospital,
Tainan, Taiwan

Correspondence to: Dr Ming-Chyi Pai, Division of Behavioral Neurology, Department of Neurology, National Cheng Kung University Hospital, 138, Sheng Li Road, Tainan 704, Taiwan. Telephone 886 6 2353535 ext 3579; fax 886 6 2759036; email: pair@mail.ncku.edu.tw

- 1 Bogousslavsky J, Regli F. Anterior cerebral artery territory infarction in the Lausanne Stroke Registry. Clinical and etiological patterns. *Arch Neurol* 1990;47:144-50.
- 2 Yamadori A. Perseveration in aphasia. *Aphasia Research* 1987;7:25-9. (In Japanese.)
- 3 Luria AR, Tsvetkova LS. Towards the mechanism of "dynamic aphasia". *Acta Neurol Belg* 1967;67:1045.
- 4 Kleist K. *Gehirnpathologie*. Leipzig: Barth, 1934. Cited by: McCarthy RA, Warrington EK, eds. *Cognitive neuropsychology*. San Diego: Academic Press, 1990:191.
- 5 Shallice T. *From neuropsychology to mental structure*. Cambridge: Cambridge University Press, 1988.

Peripheral neuropathies among patients with HIV infection

Peripheral neuropathies often affect patients with HIV disease,¹ and various peripheral neuropathies have been described at different stages of HIV infection, from seroconversion to AIDS. Acute inflammatory demyelinating polyneuropathies have been found in association with primary HIV infection; chronic inflammatory demyelinating polyneuropathies, isolated mononeuritis, and multiplex mononeuritis have more commonly been described in those in advanced stages of HIV disease, and distal symmetric polyneuropathy has been found to be the most common neuropathy among persons with AIDS. In most cases, the aetiopathogenesis of these neuropathies is still unclear, although various factors have been implicated (infectious, metabolic, immunological, inflammatory, nutritional, and toxic).² To date, relatively few studies have estimated the incidence of peripheral neuropathies among HIV infected patients belonging to different population groups. Data derived from the Multicenter AIDS Cohort Study showed annual rates slightly higher than 1.5/100 person-years for sensory neuropathy.³ Another study found a roughly 1% annual incidence of neuropathies in symptomatic patients without AIDS.⁴ To estimate the incidence of peripheral neuropathies during the different stages of HIV disease, we analysed data from a cohort study of patients with known dates of seroconversion (a documented HIV seronegative test followed by a confirmed positive test within two years). The seroconversion date was estimated as the midpoint in time between the last negative and the first positive HIV test. After seroconversion, patients were followed up to obtain clinical information and data on laboratory indices about every six months. The study design and methodology have been described in detail elsewhere.⁵ The present analysis included four clinical centres, which

performed a detailed neurological examination of the participants of the study. These centres were contacted to provide complete information on peripheral neuropathies by completing a standardised data collection form for each episode, providing detailed information on diagnostic criteria (neurological signs and symptoms, instrumental diagnosis), AIDS prophylaxis, and antiretroviral drug therapy. The study population consisted of 621 HIV seroconverters. The median age of the participants was 27 (range 14-66) years, 29 for males and 24 for females. Of these patients; 267 (42.9%) were intravenous drug users, 217 (34.9%) were homosexual men, and 127 (20.5%) were heterosexual contacts; 10 (1.6%) patients had unknown or undetermined risk factors. During a median follow up time of 5.7 years, 19 (3.1%) patients developed symptoms suggestive of peripheral neuropathies. The estimated incidence of peripheral neuropathies was 5.5/1000 person-years of follow up. The median age at the time of diagnosis was 35.2 years (range 24.8-53.6 years). Thirteen events (68.4%) occurred among males and six (31.6%) among females. For the exposure category, peripheral neuropathy was found among seven (2.6%) intravenous drug users, five (2.3%) homosexual men, and seven (5.5%) heterosexual contacts. The incidence rate of peripheral neuropathies was 4.4/1000 person-years in intravenous drug users, 4.3/1000 person-years in homosexual men, and 11.4/1000 person-years in heterosexual contacts. Acute infection was observed in 43 of 621 (7%) patients. One episode of peripheral neuropathy occurred during acute infection (the incidence rate of peripheral neuropathies was 42.4/100 person-years), six episodes during the asymptomatic phase (0.2/100 person-years), eight in the pre-AIDS symptomatic phase (2.4/100 person-years), and four episodes in patients who had already presented with diseases indicative of AIDS (3.8/100 person-years). The CD4 cell count at diagnosis of peripheral neuropathies was 266.2 for the patients with acute infection; the median was 324.6 (range 149.7-655.2) for those in the asymptomatic phase, 216.5 (range 14.9-1440.0) among those with pre-AIDS symptoms, and 38.0 (range 7.2-124.8) among persons with AIDS. Of the 19 patients with peripheral neuropathies, 15 (78.9%) had distal symmetric polyneuropathy, two (10.5%) had multiplex mononeuritis, and two (10.5%) acute inflammatory demyelinating polyneuropathies. The median CD4 cell count at diagnosis of peripheral neuropathy was 31.2 (range 16.3-47.0) for persons with multiplex mononeuritis, 184.1 (range 7.5-655.4) for those with distal symmetric polyneuropathy, and 304.3 (range 342.1-266.3) for those with multiplex mononeuritis. All 19 patients had sensory neuropathy, and 14 (73.7%) also had motor impairment. Of these 19 patients, 13 (68.4%) underwent electrophysiological investigations, showing abnormalities of nerve conduction. Another patient presenting with a mononucleosis-like syndrome and meningo-radicular neuritis had a raised number of cells (184/ μ l) in the CSF. The CSF of the other participants was normal. No participant reported the use of known neurotoxic drugs such as DDC; 10 patients had received AZT and two had received DDI (both patients who were treated with DDI had discontinued treatment six months before the onset of peripheral neuropathies; one had multiplex mononeuritis and one distal sym-