

Case Reports

Masturbatory-Orgasmic Extracephalic Pain

Daniel E. Jacome, MD

Two single men, one with compressive spondylitic cervical myelopathy and another with tethered cord and intraspinal lipoma, experienced severe paroxysmal ice picklike pains, solely referred to the neck in the first and to the groin and genitalia in the second, that were precipitated by masturbation and masturbatory orgasms. Continuous, but less intense, background pain was reported by both patients over the same anatomic areas. Neither had intracranial lesions, epilepsy, or suffered from migraine. Recently, extratrigeminal ice pick status was reported in this journal. These two unusual cases represent examples of extracephalic ice picklike pain triggered by sexual activity, in the absence of orgasmic cephalgia.

Key words: ice picklike pain, extracephalic ice picklike pain (*Headache* 1998;38:138-141)

Masturbation constitutes normal human behavior unless it is compulsive, resulting from psychiatric illness or severe personality disorder. Neurologic conditions precipitated by sexual activity (intercourse, masturbation, and orgasm) include transient global amnesia, monocular blindness, syncope, subarachnoid hemorrhage, intracranial hematoma, embolic strokes, and severe headaches.¹ Exceptionally, compulsive masturbation may be an ictal manifestation of absence status.²

Two patients are described with extracephalic ice picklike pain triggered by masturbation or orgasm. Both had spinal cord pathology accounting for their symptoms; neither had migraine headaches or headaches with sexual activity.

CASE HISTORIES

Case 1.—A 56-year-old single man was referred for neurologic evaluation because of neck pain of several months' duration. The pain was constant, dull, located in the middle of his neck, and radiated to the left arm. He had occasional numbness and tingling of his left arm. He experienced severe, lancinating, brief duration pain over the

same area of the neck where he experienced background pain during masturbatory orgasms. The pain related to sexual activity did not radiate to the arms, and was not associated with loss of consciousness or headache. He had no sexual partners. He gave a history of difficulty walking for the same period of time that he had neck pain, and his legs fatigued easily when walking short distances. He also had a history of chronic depression and hypercholesterolemia, but no history of migraine.

His general physical examination was unremarkable. On neurologic examination, there was no limitation of neck motion and no pain with head movements. His knee and ankle deep tendon reflexes were increased, and he had a left Babinski sign. His gait was unsteady and hesitant. Electromyogram and nerve conduction studies (EMG-NCV) of the left arm were normal. Cervical spine x-rays showed spondylosis, and cervical magnetic resonance imaging (MRI) revealed spondylosis at C4-5 and C5-6, with moderate reduction in the anteroposterior (AP) diameter of the cervical spine, at the same levels (Figure 1). Additional spondylitic spurs were present at C6-7. Computerized tomography (CT) of the head and electroencephalogram (EEG) were normal.

The patient was prescribed ibuprofen for symptomatic relief. He chose not to have neurosurgical intervention. No progression of his symptoms was noticed in follow-up.

Case 2.—A 47-year-old single man was referred to a neurologist because of right groin and testicular pain. There was rectal pain of lesser intensity. He had occasional numbness of the right foot. His groin and testicular pain was greatly intensified during masturbation and became excruciating and stabbinglike during masturbatory orgasms. There were no headaches with masturbation, however. He had no sexual partners. His past medical history was positive for bipolar affective illness, well controlled with lithium carbonate and trifluoperazine. He also took alprazolam for anxiety on a regular basis. He had irritable bowel syndrome and a remote history of alcohol abuse. He had no history of migraine.

From the Department of Medicine, Franklin Medical Center, Greenfield, Mass and the Division of Neurology, Dartmouth Medical School, Hanover, NH.

Address all correspondence to Dr. Daniel E. Jacome, One Burnham Street, Suite 2, Turners Falls, MA 01376.

Accepted for publication May 4, 1997.

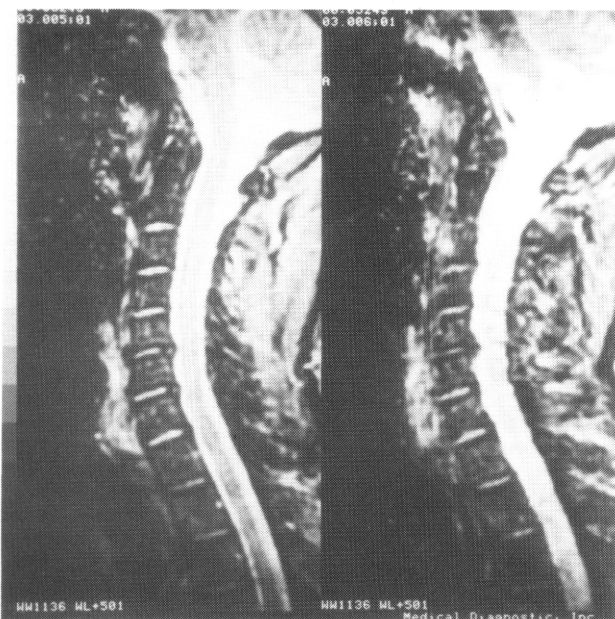


Fig 1.—Case 1, MRI of the cervical spine with T2 weighted images demonstrates spondylosis and disk bulging with diminished AP diameter of the spinal canal at C5-6 levels. Some indentation on the spinal cord is evident.

His general physical and neurological examinations, CT of the head, and EEG were normal. A complete blood count, blood chemistries, sedimentation rate, and thyroid function studies were normal, and his antinuclear

antibody testing was negative. His lumbosacral CT revealed spinal stenosis at L3-4 and L4-5, and congenitally abnormal posterior elements of S1. His lumbosacral MRI revealed a lipoma of the filum terminale and an incomplete fusion of L5 and the sacrum on the right (Figures 2A and 2B). The conus medullaris terminated at a lower level than normal (L2-3), indicative of a tethered cord.

Discontinuation of lithium did not improve his symptoms, nor did eventual transection of his filum terminale lipoma and a right L5-S1 laminectomy. Masturbatory pain continued unchanged. The patient was prescribed nonsteroidal anti-inflammatory agents (NSAIDs), but obtained no significant relief. No new symptoms have developed in follow-up.

COMMENTS

Sexual, coital, or orgasmic headaches have been recognized since the time of Hippocrates.³ The unexpected appearance of a severe headache during intercourse, and especially during orgasm, is a natural source of concern to the patient who fears a neurologic catastrophe. When recurrent, it is a frequent cause of psychologic impairment, secondary impotence, and even marital discord. The common experience of most neurologists, however, is that no underlying disorder is present, and that the patients have a normal neurologic examination when first evaluated. Most cases have negative

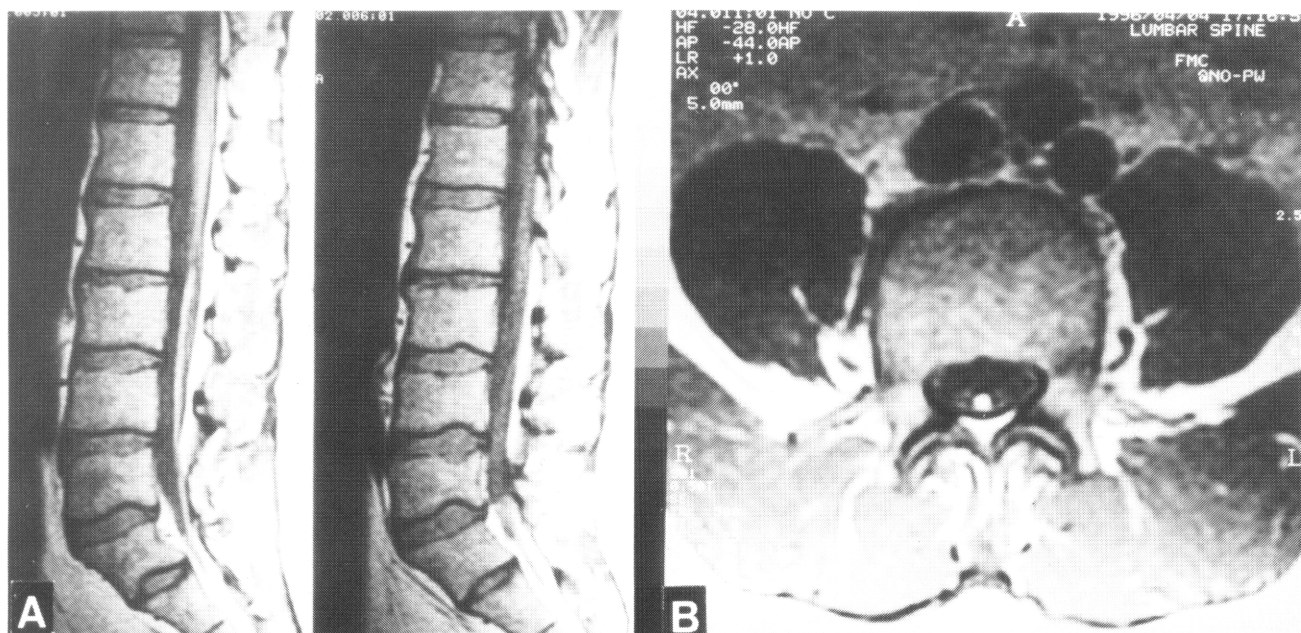


Fig 2.—Case 2, MRI of the lumbosacral spine with T1 weighted images. A shows a lipoma of the filum terminale and descended conus medullaris; B, the thickened filum terminale is visible in the transverse views of the lower lumbosacral spine (white circular structure placed dorsally in the spinal canal).

imaging studies and the EEGs are normal. Nevertheless, because of the exceptional complications listed above, physicians often feel compelled to recommend those additional testings. Sexual headaches are most often bilateral, precipitated by coitus and/or masturbation.³ Three types of sexual headaches are recognized: type 1 is a dull headache or neck discomfort that augments as sexual excitement increases, type 2 is a sudden explosive headache during orgasm, and type 3 is a chronic postcoital headache exacerbated by the upright position and Valsalva's maneuver. Type 3 headaches are possibly due to a meningeal tear that occurs during intercourse, resulting in low cerebrospinal fluid (CSF) pressure.^{4,5} Type 2 sexual headaches are naturally the ones that elicit greater concern for their intensity and paroxysmal nature. Headaches associated with sexual activity are classified as "exertional headaches," along with cough (straining)-induced headaches.⁶ Although exertional headaches exceptionally are caused by intermittent craniospinal pressure dissociation and subdural hematoma, they are considered a benign variant.^{2,6-9} Sexual headaches may affect several family members and be associated with hypertension.⁹ Vincent, in 1982, gave the name of "benign masturbatory cephalalgia" to headaches developing during masturbation, although they had been recognized previously.¹⁰ The subjects of this report had no concomitant masturbatory headaches. Finally, sexual headaches may respond to the administration of propranolol and calcium-channel blockers.^{9,11}

Ice picklike pain is characterized by brief, intense, sharp, shooting head pain, often localized along the distribution of the first branch of the trigeminal nerve.¹² It is benign and probably more common in migraineurs. Infrequently, it is reported by patients with cluster headaches and by patients with giant cell arteritis.¹² Ice picklike pain can be unilateral or multifocal and consist of single or multiple jabs that resemble trigeminal neuralgia, cluster tic, or epileptic pain (see below). Ice pick status refers to continuous stabbing pain, usually multifocal.¹³ In children, contrary to the adult form, ice pick pain appears in isolation.¹³ Martins et al reported in this journal six patients with frequent, multifocal, severe, ice picklike pain, perceived in areas of the head outside the cutaneous areas of the scalp innervated by the trigeminal nerve.¹⁴ These patients had normal neurologic examinations, no history of migraine, and no complications in long-term follow-up.¹⁴ They responded promptly to the administration of indomethacin.¹⁴

Cervicogenic headaches refers to headaches that are secondary to conditions that affect the cervical spine.¹⁵ The typical patient complains of

long-lasting unilateral headaches of moderate severity.^{15,16} Associated symptoms are nausea, vomiting, dizziness, visual disturbance, excessive lacrimation, and sound and light intolerance.^{15,16} Surgical decompression of the second cervical root may be curative.¹⁷ Cervicogenic headaches constitute a valid diagnosis in the presence of rheumatoid arthritis, ankylosing spondylitis, and anomalies of the craniovertebral junction. Their association with head trauma, cervical osteoarthritis, and degenerative disc disease is less certain.¹⁶ The neck pain of case 1 did not resemble the typical pain of cervicogenic headaches, nor of degenerative joint and disc disease. The latter pain tends to be worsened by head motion; is associated with stiffness of the neck; and is of articular, periosteal, and soft tissue origin. It radiates to the arms if coexistent radicular symptoms are present, and rarely, radiates to the ear.¹⁸ Conversely, the neck pain of cervical (spondylitic) myelopathy described by the first patient probably arises from dural arthritic cord encroachment, concomitant root entrapment, or irritation of the intraspinal vasa nervorum. The accompanying neurologic deficits (ie, spastic paraparesis, arm weakness) are the result of compression of the lateral columns, or the result of central ischemic myelomalacia.¹⁹ In the first patient, it is unknown if his paroxysmal orgasmic pain was secondary to neck hyperextension or to transient circulatory changes taking place during his sexual climax. He had no coexistent lumbosacral symptoms.

Tethered cord is a congenital developmental disorder due to an abnormal retrograde differentiation of the distal spinal cord.^{20,21} The conus medullaris fails to ascend into the spinal canal and remains positioned at the lower level, fixed in place by a thickened filum terminale. Tethered cords are often associated with intraspinal lipomas.²⁰ They are clinically manifested by bladder and bowel dysfunction, back pain, radicular pain, and sensorimotor deficits in the legs. Case 2 did not obtain relief of his spontaneous pain nor of his masturbatory orgasmic pain after transection of his spinal lipoma; it is uncertain if positional changes, muscle spasms, dural stretching, or transient disturbance of the intraspinal circulation during the act of masturbation caused his symptoms. Since the ultimate pathophysiology of tethered cord syndrome is based on impairment of the oxidative metabolism of the lumbosacral cord and simultaneous alterations in the spinal blood flow, it is reasonable to assume that in the second patient, ischemia and metabolic derangement of the spinal cord were present with masturbation, resulting in paroxysmal pain.²² Because sexual sensations of pleasure are perceived in the lower abdomen,

perineum, and genitalia, it may be stated that the two individuals herein discussed had referred pain; despite that the original precipitating sensations were not painful, the pain was perceived in an area distant to the site of the lesion and it was mediated, at least in part, by the autonomic nervous system.²³ Visceral-referred pain is a well-known clinical phenomenon. Less recognized is somato-somatic referred pain, in which distal stimulation applied to dermatomes remote to a spinal cord lesion triggers pain, either at the lesional site, or elsewhere. Yet, the putative underlying pathophysiology of somato-somatic referred pain is based on ephaptic transmission of sensory tract fibers at the lesion site or surrounding areas, perhaps due to mechanical displacement of nerve fibers, spinal cord edema, or both.²³ The anatomically remote symptoms reported by patients with foramen magnum tumors serves to illustrate the case in point.²⁴

Epileptic pain must be distinguished from paroxysmal referred pain because it is also intense, of brief duration, and may be understood as a form of referred pain.²⁵ Epileptic pain can manifest as headaches or experienced as paroxysmal genital pain.^{26,27} It is confirmed on the basis of an abnormal EEG showing epileptic discharges during the painful episodes. The normal EEGs found in the subjects of this report ruled out epilepsy as a source for their pain triggered by masturbation.

REFERENCES

1. Finelli PF. Coital cerebral hemorrhage. *Neurology*. 1993;43:2683-2685.
2. Jacome DE, Risko MS. Absence status manifested by compulsive masturbation. *Arch Neurol*. 1983;40:523-524.
3. Lance JW. Headaches related to sexual activity. *J Neurol Neurosurg Psychiatry*. 1976;39:1226-1230.
4. Lance JW. Benign masturbatory cephalgia. *Arch Neurol*. 1983;40:393.
5. Paulson GW, Klawans HL Jr. Benign orgasmic cephalgia. *Headache*. 1974;13:181-187.
6. Pascual J, Iglesias F, Oterino A, Vazquez-Barquero A, Berciano J. Cough, exertional, and sexual headaches: an analysis of 72 benign and symptomatic cases. *Neurology*. 1996;46:1520-1524.
7. Williams B. Cough headache due to craniospinal pressure dissociation. *Arch Neurol*. 1980;37:226-230.
8. Jacome DE, Yanez GF. Subdural haematoma upon straining. *J Neurol Neurosurg Psychiatry*. 1989;52:134.
9. Johns DR. Benign sexual headache within a family. *Arch Neurol*. 1986;43:1158-1160.
10. Vincent FM. Benign masturbatory cephalgia. *Arch Neurol*. 1982;39:673.
11. Akpunonu BE, Ahrens J. Sexual headaches: case report, review, and treatment with calcium blocker. *Headache*. 1991;31:141-145.
12. Raskin NH, Schwartz RK. Icepick-like pain. *Neurology*. 1980;30:203-205.
13. Soriani S, Battistella PA, Arnaldi C, et al. Juvenile idiopathic stabbing headache. *Headache*. 1996;36:565-567.
14. Martins IP, Parreira E, Costa I. Extratrigeminal ice-pick status. *Headache*. 1995;35:107-110.
15. Sjaastad O, Saunte C, Hovdahl H, Breivik H, Gronbaek E. "Cervicogenic" headache. An hypothesis. *Cephalalgia*. 1983;3:249-256.
16. Edmeads J. The cervical spine and headache. *Neurology*. 1988;38:1874-1878.
17. Pikus HJ, Phillips JM. Characteristics of patients successfully treated for cervicogenic headache by surgical decompression of the second cervical root. *Headache*. 1995;35:621-629.
18. Lamer TJ. Ear pain due to cervical spine arthritis: treatment with cervical facet injection. *Headache*. 1991;31:682-683.
19. al-Mefty O, Harkey HL, Marawi I, et al. Experimental chronic compressive cervical myelopathy. *J Neurosurg*. 1993;79:550-561.
20. James HE, Chesnut R, Krous H, Billman G, Jones KL, Jones M. Distal spinal cord pathology in the VATER association. *J Pediatr Surg*. 1994;29:1501-1503.
21. Gokay H, Barlas O, Heggul KT, Hicdonmez T. Tethered cord in the adult mimicking the lumbar disc syndrome: report of two cases. *Surg Neurol*. 1993;39:440-442.
22. Yamada S, Iacono RP, Andrade T, Mandybur G, Yamada BS. Pathophysiology of tethered cord syndrome. *Neurosurg Clin N Am*. 1995;6:311-323.
23. Lee SI, Phillips LH II, Jane JA. Somato-somatic referred pain caused by suprasegmental spinal cord tumor. *Neurology*. 1991;41:928-930.
24. Yasuoka S, Okazaki H, Daube JR, MacCarty CS. Foramen magnum tumors. Analysis of 57 cases of benign extramedullary tumors. *J Neurosurg*. 1978;49:828-838.
25. Wilkinson HA. Epileptic pain. An uncommon manifestation with localizing value. *Neurology*. 1973;23:518-520.
26. Laplante P, Saint-Hilaire JM, Bouvier G. Headache as an epileptic manifestation. *Neurology*. 1983;33:1493-1495.
27. York GK, Gabor AJ, Dreyfus PM. Paroxysmal genital pain: an unusual manifestation of epilepsy. *Neurology*. 1979;29:516-519.