

NOTE

SEEING OBJECTS SMALLER THAN THEY ARE: MICROPSIA FOLLOWING RIGHT TEMPORO-PARIETAL INFARCTION

Fiorenzo Ceriani, Valentina Gentileschi, Silvia Muggia and Hans Spinnler*

(Third Neurological Department of the University of Milan)

ABSTRACT

We report the case of an 84-year-old lady who, after a right temporo-parietal infarction, complained of seeing things smaller than she expected. She also related that straight lines appeared distorted and described seeing colours as if they were a badly mixed assemblage of hues. Her visual field was normal except for a transient left field extinction. No spatial neglect emerged. The patient's micropsia remained unchanged during the course of the six month follow-up.

Key words: micropsia, metamorphopsias, temporo-parietal visual disorders

INTRODUCTION

Vision disorders may arise from extremely selective impairments of cortical functions. They encompass a number of vision defects traceable back to the isolated impairment of processes which start automatically at the cortical entrance of stimuli (Kleist, 1934; Critchley, 1971; Poetzl, 1928). Metamorphopsias belong to this type of disorder (Glonig, Glonig and Hoff, 1968; Critchley, 1971; Joynt, Honch, Rubin et al., 1985). As a rule, these defects of visual function do not result in an agnosic defect (but see Gelb and Goldstein's lengthy discussion, 1918, of their patient Schn who showed both metamorphopsic and agnosic defects) as shown by the fact that metamorphopsic patients are able to carry out a normal analysis of the visual features of objects and demonstrate an understanding of their function. Metamorphopsic patients often show transient or permanent field defects, sometimes vertigo, but never impaired visual acuity. Examples of metamorphopsias are the defects in the normally occurring upside/down re-orientation of retinal patterns (Klopp, 1951), judging visual distance and zoom vision, stereopsis (Riddoch, 1917; Faust, 1947), the ability to precisely localize stimuli in the field of vision, and re-adjusting the size of objects according to the viewing distance. The foregoing disorders are often associated with systematic distortions of the perception of visual stimuli, such as misalignment, bending, tilting (Henschen, 1927; Lenz, 1944) and blurring of architectural straight lines, different types of dyschromatopsias, detachment of colours from the surface they belong to and their fluctuation between the observer and the surface itself (Gelb, 1921), faulty appreciation of the luminosity of the object under observation, apparent movement of stationary objects (so-called "drifting images", Bender and Teuber, 1949a) or jerky movements of regularly moving objects. It is likely that the impaired functions that give rise to metamorphopsias are the same as those underlying normal fluctuations of the Necker's cube, flickering fusion and physiological optical illusions.

Metamorphopsias are often fleeting or episodic when the underlying dysfunction is transient (migraine, Todd, 1955; seizures, Russell and Whitty, 1955; psychotropic drugs

*Names are listed in alphabetical order, and this does not imply differential contribution to the study.

abuse). The much rarer long lasting or permanent metamorphopsias are associated with posterior cortical lesions, involving the temporal and parietal lobes (De Ajuriaguerra and Hécaen, 1964; Gloning et al, 1968). In their series of 384 patients with retro-rolandic damages Angelergues and Hécaen (reported in De Ajuriaguerra and Hécaen, 1964, pages 148-149) pointed out that right lesions are more likely than left lesions to give rise to metamorphopsias (respectively, 15% vs 9%). As far as we know, Angelergues and Hécaen are the only authors to claim that metamorphopsias are of non-exceptional occurrence. Mullan and Penfield (1959) suggested that right temporal lesions in particular tend to produce metamorphopsias.

The most common form of metamorphopsias is micropsia (Gelb and Goldstein, 1918), also referred to as “Lilliput sight”, in which the size of the normally recognized object is underestimated. Objects perceived as being smaller are sometimes also perceived as being further away than they really are (Bender and Krieger, 1951). The patients themselves, are aware that semantics and actual perception convey contradictory information. Bender and Teuber (1947) interpreted the disorder as the consequence of the breakdown of the “size constancy” phenomenon, i.e., of the ability to adjust the object size to the viewing distance.

Metamorphopsias belong to the realm of the entirely subjective disorders, together with the phantom limbs of amputees (review in Weinstein, 1969) and the kinetic hallucinations of paraplegics (Gasparini, Nichelli and Spinnler, 1976). Because of the bizarre features of their disturbance, patients are often loath to report them, unless explicitly encouraged to do so. It is possible that neurologists too are cautious about describing them. To the best of our knowledge, there has not been a single reported case of micropsia in the last two decades. We report the case of a patient, who was investigated over a period of about six months. GT gave us the opportunity to test Bender and Teuber’s (1947) hypothesis that micropsia is contingent upon the dysfunction of the mechanism that underlies the “size constancy” phenomenon.

CASE REPORT

GT was an 84-year-old woman who worked as a professional artist and poet. She was in good health until December 1995, when she was admitted to hospital and put on anticoagulant medication for deep venous thrombosis affecting her left leg. After recovering from this episode, she was referred to our department because she had been complaining of seeing things smaller than she expected them to be, for over a week. No clinical sign of CNS focal involvement was evident at the bedside examination, but a cerebral CT scan showed a small quadrangular hypodense area in the right temporo-parietal posterior region, which was interpreted as an infarction.

Clinical Data

Neurological examination was normal, specifically she had no deficit of her intrinsic or extrinsic eye muscle, and her auditive or vestibular functions were unimpaired. *Ophthalmological examination* revealed a mild degree of presbyopia, but this defect was successfully corrected by glasses. Although perimetry did not reveal visual field defects, GT showed consistent extinction of left stimuli presented on double simultaneous stimulation. It gradually disappeared and was never accompanied by tactile or auditory extinction. *Psychiatric assessment* was perfectly normal.

Visual pattern-reversal evoked potentials showed normal wave form but an increased P100 latency.

MRI (Figure 1) showed a small wedge-shaped softening in the region of the right temporo-parietal cortical junction which encroached upon the collateral gyrus and the posterior aspects of the trigonum. This lesion was mainly cortical. There were also tiny T2 hyper-intensities scattered bilaterally within the parietal and occipital white matter and the basal ganglia.

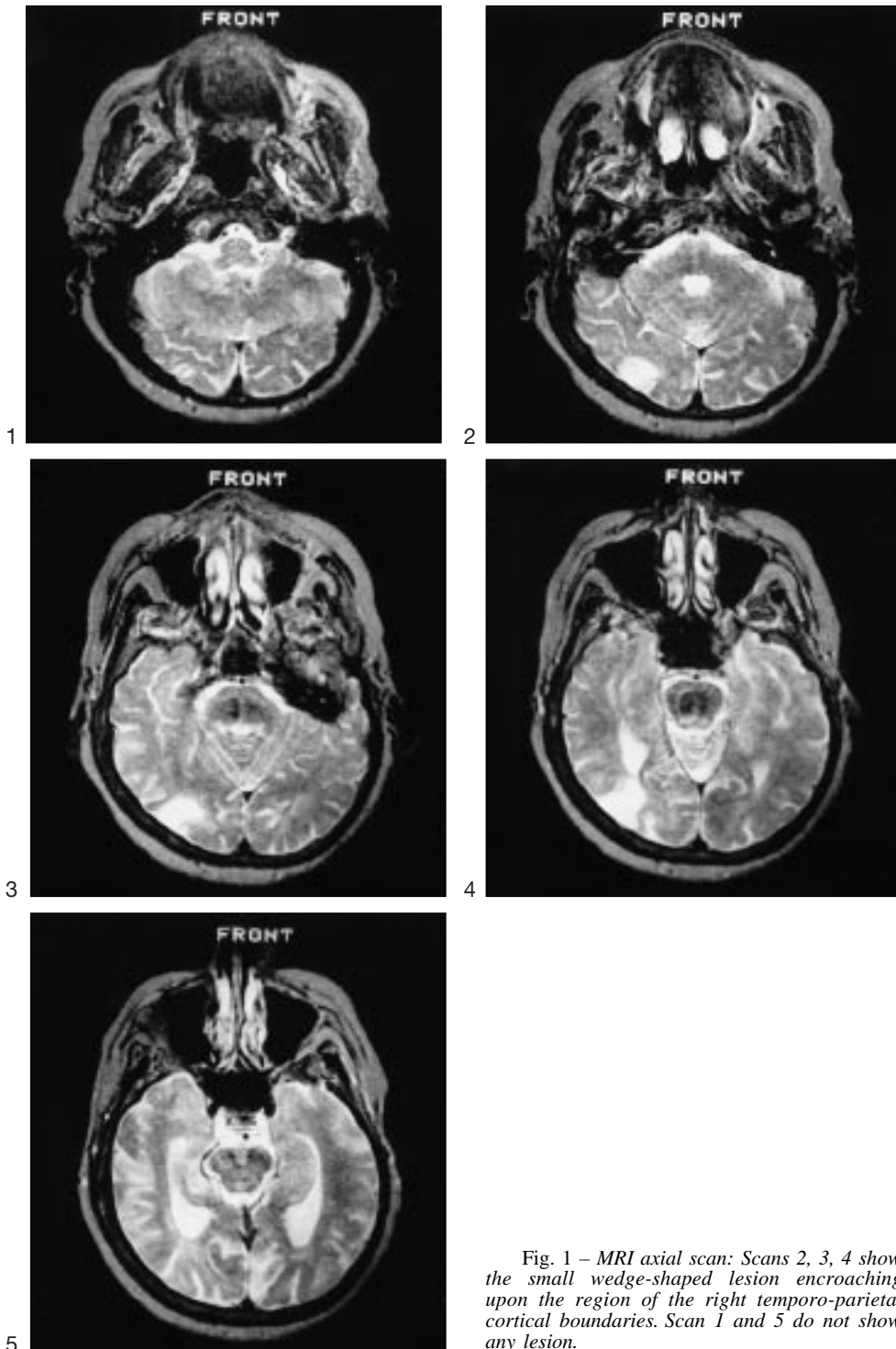


Fig. 1 – MRI axial scan: Scans 2, 3, 4 show the small wedge-shaped lesion encroaching upon the region of the right temporo-parietal cortical boundaries. Scan 1 and 5 do not show any lesion.

Behavioural Data

GT was very frustrated by her visual symptoms, which she related very accurately. Micropsia was described as a five-fold reduction of objects with respect to the expected real size. It was unaffected by head position, gaze direction, lighting variations or by closing one eye. It affected any object at a viewing distance of over one meter with the exception of her hands, which appeared smaller than she expected. Objects perceived as being smaller were not perceived as being further away. Her disturbance was described as being constant across hours or days. Apparently, GT imagined objects with their correct size, since, when asked to indicate the dimensions of various things she would promptly indicated appropriate sizes with her hands. She had no subjective difficulty in estimating the distance between two objects, or between the objects and herself. The size of GT's handwriting was unaffected whether performed with her eyes open or closed. Reading aloud (with glasses) was flawless. She was able to show the vertical, horizontal and 45° positions with a stick. GT reported no hallucinations, palinopsia, poliopsia, teleopsia or macropsia, and she had no difficulty in figure-ground discrimination (eg., searching for an object in a cluttered drawer). Micropsia was not accompanied by other sensory experiences such as auditory, olfactory or vertigo.

At onset the patient reported having the sensation that object contours were twisted: in particular, in the first few days it seemed to her that horizontal, vertical or inclined curved lines were squiggly. The disorder gradually subsided within a few days. She never had upside-down misperceptions, or saw flat surfaces as curved or uneven.

Besides micropsia, the patient also reported an altered perception of colour. To GT homogeneous coloured surfaces appeared as if the colour were the result of a badly mixed assemblage of different shades. She described her chromatic feelings as follows: "It seems as if even coloured things have unevenly washed out colours; I feel that my sensitivity to colours is enhanced, as if I could see true components of the coloured surface in a more fine-grained and disaggregated way".

Follow-up

The patient was subsequently seen as an outpatient three and six months after onset. On both occasions, her micropsia still involved any object located at a distance of more than about one meter, while colour perception had improved and squiggly perceiving of curved or straight lines was no longer evident. Six months after onset, GT reported that she perceived her hands correctly. She started painting (and writing) again without any disorder in the use of the rules of perspective and in representing dimensional features and colours of objects. She claimed to have no trouble painting as long as she stood within 40 cm from the canvas. However, if the same pictures were hung up on the wall, they appeared markedly smaller. GT became accustomed to her problem, but still often wondered about the real dimensions of the things she looked at.

In summary, GT presented a persistent micropsia and transient colour and contour misperception following a right temporo-parietal infarction.

Neuropsychological Assessment

The patient underwent neuropsychological examinations at one, three and six months from onset. She was cooperative and perfectly oriented in time and space, no language disturbance was ever apparent and the instructions of the tests proposed were always understood immediately.

In a preliminary test of colour perception GT was asked to point to the colour named by the examiner (10 items) and to name the colour shown by the examiner (10 items): her answers were 100% correct. Normal performance on Ishihara's (1960) test (see Table I) was in line with the preliminary colour test just described. The results of GT's performance on a number of visuo-spatial tests are shown in Table I.

All scores fell within the normal range, with the exception of the visual discrimination test score (same versus different length judgement; Bisiach, Nichelli and Spinnler, 1976).

TABLE I
CT' Performance at Neuropsychological Assessment
(Scores adjusted by age and education. Scores impaired when smaller than cut-off values)

Test	GT's score 1 month after onset	GT's score 3 months after onset	Cut-off score
Ishihara's test for colour blindness (range 0-21)	21	–	17 ^a
Colour-figure matching (range 0-16)	16	–	10 ^b
Judgement of line orientation (range 0-30)	20	–	17 ^c
Visual form discrimination (range 0-32)	25	32	22 ^c
Facial recognition (range 0-54)	43	–	37 ^c
Age estimation test (range 0-96, error score)	–0.788	–	2.88 ^d
Visual discrimination (same/different) (range 0-32)			
segments:	16	16	17 ^c
scrawls:	30	30	17 ^c
Poppelreuter - Ghent's overlapping figures test			
concrete (0-36):	36	35.6	27.75 ^e
abstract (0-35):	26.3	24.1	23 ^e
total (0-71):	62.3	59.7	51.25 ^e
Street's completion test (range 0-14)	–	8.5	2 ^f
Efron's visual discrimination test (range 0-20)	–	19 ^g	–
Visual neglect test (range 0-32)	–	32	17 ^g
Raven's PM (1947) (range 0-36)	30	–	17.5 ^h

^aIshihara, 1960.

^bDe Renzi, Faglioni, Scotti et al., 1972.

^cBenton, Hamsher, Varney et al., 1983.

^dFaglioni, Cremonini and De Renzi, 1991. Note: only in this test, performance is impaired if scores are *greater* than cut-off value.

^eDella Sala, Laiacona, Spinnler et al., 1995.

^fSpinnler and Tognoni, 1987.

^gWarrington and James, 1988.

^hBasso, Capitani and Laiacona, 1987.

On this task, GT correctly discriminated pairs of different length, but consistently judged pairs of identical lines as being different. Specifically, when GT was presented with vertical pairs, the lower line was always judged as being shorter and when she was presented with horizontal pairs, the line on the left was always perceived as being shorter.

Bender and Teuber (1947) suggested that micropsia follows a defect of visuo-perceptual size constancy. According to this view, the greater the viewing distance the smaller the perceived size of any stimulus.

Seven months from onset, we gave GT a test of visuo-perceptual consistency, designed to assess whether she was able to correctly estimate dimensions at changing distances. A black circle, 5 cm in diameter on a white background was hung on the wall and the patient was seated at a distance of 6, then 3 and finally 1 meter. The room was lit naturally and brightly. At each distance she had to turn over the pages of a booklet containing two series of 16 different circles each ordered by size (increasing from 3 to 5 cm and decreasing from 7 to 5 cm in diameter). She was requested to choose the circle of the same or the most similar size to the one on the wall. Nine controls of comparable age and education performed the same test (see Table II).

Contrary to Bender and Teuber's (1947) hypothesis that patients with micropsia perceive the most distant objects the smallest, GT made her worst guesses at the shortest distance (1 meter). Here, in the decreasing series, the 5 cm circle seemed too big to her and she claimed that she would have chosen a smaller circle had one been available. GT's estimates at six and three meters were in keeping with the controls' scores.

TABLE II
Perceptual Consistency Test
(measures given in centimetres)

Distance from target 5 cm circle	Series of circles to match (diameters)	GT's choices 1 month after onset	GT's choices 3 month after onset	Controls' choices mean (S.D.)	Controls choices range
6 m	growing from 3 to 5 cm	4.4	4.3	4.6 (0.251)	4.3-5.0
	decreasing from 7 to 5 cm	5.6	5.1	5.5 (0.276)	5.2-6.1
3 m	growing from 3 to 5 cm	4.6	4.5	4.7 (0.319)	4.3-5.0
	decreasing from 7 to 5 cm	5.4	5.2	5.6 (0.354)	5.2-6.3
1 m	growing from 3 to 5 cm	4.1	3.9	4.5 (0.24)	4.2-4.9
	decreasing from 7 to 5 cm	5*	5*	5.5 (0.224)	5.2-5.9

In summary, GT's subjective micropsia fails to tie in with findings on a visuoperceptual size consistency test. The only psychometric findings pointing to a visuoperceptual disorder are those obtained in a same/different task of segments.

DISCUSSION

After a right temporo-parietal posterior softening, GT presented micropsia and left-sided visual extinction on double simultaneous stimulation. She also complained that at times curved contour-lines appeared distorted and colour surfaces seemed to break up into different hues. These disorders were transient, whilst her micropsia persisted. All other visual and non-visual performances were normal.

The right hemisphere retro-rolandic location of GT's softening tallies with Angelergues and Hécaen's suggestion (De Ajuriaguerra and Hécaen, 1964) of a more frequent minor hemisphere involvement in the case of metamorphopsias. MRI evidence in GT lends some support to Critchely's suggestion (1971) that metamorphopsia points to a parietal lesion and to Mullan and Penfield's (1959) hypothesis of a link between the disorder and right temporal damage. Although Angelergues and Hécaen (De Ajuriaguerra and Hécaen, 1964) argued to the contrary, it is widely held that micropsia is extremely rare and it is not listed in modern reviews of the posterior cerebral artery syndromes (e.g., De Renzi, Zambolin and Crisi, 1987).

On testing, GT systematically underestimated the length of the left segment of horizontally presented pairs, and the lower segment of vertically presented pairs. This impairment tallies in with group-findings in right posterior focal hemisphere-damaged patients (Bisiach et al., 1976). However, this test failure has little to do with micropsia, but it merely points to the presence of a right parieto-temporal lesion.

Bender and Teuber's (1947) hypothesis that micropsia is a size constancy impairment was apparently in agreement with GT's claim that her micropsia disappeared at a viewing distance of less than one meter. The attempt to substantiate this subjective claim experimentally, was unsuccessful. In fact, GT's micropsia appeared to be a metamorphopsic disorder of size appreciation irrespective of the viewing distance, and we could not marshal experimental support for her claim that the disorder was only apparent for objects at a distance of over one meter. Indeed, the only condition under which she performed worse than controls was when the stimulus was at a distance of one meter.

Poetzl (1943) interpreted metamorphopsias as a disorder of fusion of images from the two homonymous halves of the retinae. Bender and Teuber (1949b) suggested that they result from a functional imbalance between intact and damaged visual cortical areas. The functional asymmetries of vision evidenced by the extinction phenomena could help to throw light on GT's predicament. It appears as if her damage right temporo-parietal cortex conveys size information to consciousness that does not fit in with that conveyed by the left cortex. This functional rivalry contributes to the contradiction with the semantically known "true" size of the object under scrutiny: right hemisphere perception does not match

semantic knowledge, whereas left perception does. For reasons unknown, there is a micropsic bias, though also macropsia has seldom been pointed out in the literature (Bender and Krieger, 1951; De Ajuriaguerra and Hécaen, 1964). When a dense hemianopia entirely prevents the processing of incoming stimuli by the damaged hemisphere, metamorphopsia never occurs. It has to be said that the supposed functional rivalry hinges upon the left extinction phenomena: however, extinction was transient, while micropsia was permanent.

It is likely that automatic visual processes, whose defects basically give rise to metamorphopsias, are subserved by extremely selective neuronal networks in each hemisphere, whose unbalanced rivalry might be capable of giving rise to the most bizarre visual disorders. In any case, the critical variable remains obscure and, given how exceptional metamorphopsias are, compared with temporo-parietal lesions, their occurrence could be linked to unusual individual arrangements of the relevant neuronal connectivity.

Acknowledgements. We thank our patient GT for her collaboration, Ennio De Renzi for assisting the work-up of our report, Frida Valsecchi for the MRI interpretation. Gillian Jarvis amended the English text.

This study was partly supported by Grant to H.S. n. 91.00441.PF40 of the Consiglio Nazionale delle Ricerche (CNR) and by "60%" Grant (1996) to H.S. of the Ministero dell'Università e della Ricerca e Scientifica (MURST).

REFERENCES

- BASSO, A., CAPITANI, E., and LAIACONA, M. Raven's Coloured Progressive Matrices: Normative values on 305 adult normal controls. *Functional Neurology*, 2: 189-194, 1987.
- BENDER, M.B., and TEUBER, H.L. Spatial organization visual perception following injury to the brain. *Archives of Neurology and Psychiatry*, 58: 721-784, 1947.
- BENDER, M.B., and TEUBER, H.L. Disturbances of visuoperception following cerebral lesions. *Journal of Psychiatry*, 28: 223-233, 1949a.
- BENDER, M.B., and TEUBER, H.L. Psychopathology of vision. In Spiegel (Ed.), *Progress in Neurology and Psychiatry*. New York: Grune and Stratton, 1949b.
- BENDER, M.B., and KRIEGER, H. Visual function in perimetrically blind fields. *Archives of Neurology and Psychiatry*, 65: 72-99, 1951.
- BENTON, A.L., HAMSHER, K., VARNEY, N.R., and SPREEN, O. *Contribution to Neuropsychological Assessment*. Oxford; Oxford University Press, 1983.
- BISIACH, E., NICHELLI, P., and SPINNLER, H. Hemispheric functional asymmetry in visual discrimination between univariate stimuli: an analysis of sensitivity and response criterion. *Neuropsychologia*, 14: 335-342, 1976.
- CRITCHLEY, M. *The Parietal Lobe*. New York: Hafner Publishing Company, 1971.
- DELLA SALA, S., LAIACONA, M., SPINNLER, H., and TRIVELLI, C. Poppelreuter - Ghent's Overlapping Figures test: Its sensitivity to age, and its clinical use. *Archives of Clinical Neuropsychology*, 6: 511-534, 1995.
- DE AJURIAGUERRA, J., and HÉCAEN, H. *Le Cortex Cérébral: Etude Neuropsychopathologique*. II edition. Paris: Masson, 1964.
- DE RENZI, E., FAGLIONI, P., SCOTTI, G., and SPINNLER, H. Impairment in associating colour to form concomitant with aphasia. *Brain*, 95: 293-304, 1972.
- DE RENZI, E., ZAMBOLIN, A., and CRISI, G. The pattern of neuropsychological impairment associated with left posterior cerebral artery infarcts. *Brain*, 110: 1099-1116, 1987.
- FAGLIONI, P., CREMONINI, A., DE RENZI, E. Taratura su soggetti normali di test di facce sconosciute e familiari. Un contributo allo studio della prosopagnosia. *Archivio di Psicologia, Neurologia e Psichiatria*, 52: 339-350, 1991.
- FAUST, W. Über Gestaltzerfall als Symptom des parieto-occipitalen Übergangsgebiet bei doppelseitiger Verletzung nach Hirnschuss. *Nervenarzt*, 18: 103-121, 1947.
- GASPARINI, M., NICHELLI, P., and SPINNLER, H. Kinetic misperceptions in spinal and root disease. *The New England Journal of Medicine*, 294: 167, 1976.
- GELB, A., and GOLDSTEIN, K. Zur Psychologie des optischen Wahrnehmung- und Erkennungsvorganges. *Zeitschrift für die gesamte Neurologie*, 41: Heft 1-3, 1918.
- GELB, A. Über den Wegfall der Wahrnehmung von Oberflächenfarben. *Zeitschrift für die gesamte Neurologie und Psychiatrie*, 84: 193-215, 1921.
- GLONING, I., GLONING, H., and HOFF, H. *Neuropsychological Symptoms and Syndromes in Lesions of the Occipital Lobe and the Adjacent Areas*. Paris: Gauthier-Villars, 1968.

- HENSCHEN, S. Über die Lokalisation einiger psychischer Prozesse. *Zeitschrift für Neurologie*, 45: 65-91, 1927.
- ISHIHARA, S. *Tests for Colour-Blindness*. Kanehara: Shuppan Co., LTD, 1960.
- JOYNT, R.J., HANCH, G.W., RUBIN, A.J., and TRUDEN, R.G. Occipital lobe syndromes. In J.A.M. Frederiks (Ed.), *Handbook of Clinical Neurology*, vol. 1. Chapter 5 Amsterdam: Elsevier, 1985.
- KLEIST, K. *Gehirnpathologie Vornehmlich auf Grund der Kriegserfahrungen*. Leipzig: Verlag Johannes Ambrosius Barth, 1934.
- KLOPP, H. Über Umgekehrt- und Verkehrtsehen. *Deutsche Zeitschrift für Neurologie*, 165: 58-99, 1951.
- LENZ, H. Raumsinnstörungen bei Hirnverletzungen. *Deutsche Zeitschrift für Nervenheilklinik*, 157: 27-64, 1944.
- MULLAN, S., and PENFIELD, W. Illusions of comparative interpretation and emotion. *Archives of Neurology and Psychiatry*, 81: 269-283, 1959.
- PÖTZL, O. *Die Aphasielehre vom Standpunkt der klinischen Psychiatrie. Vol. 1. Die optisch-agnostischen Störungen*. Leipzig und Wien: F. Deutische, 1928.
- PÖTZL, O. Über Verkehrtsehen. *Zeitschrift für die gesamte Neurologie und Psychiatrie*, 176: 780-821, 1943.
- RIDDOCH, G. Dissociation of visual perception due to occipital injuries with special reference to appreciation of movement. *Brain*, 40: 15-57, 1917.
- RUSSELL, W., and WHITTY, C.W.M. Studies in traumatic epilepsy: three visual fits. *Journal of Neurology, Neurosurgery and Psychiatry*, 18: 79-96, 1955.
- SPINNLER, H., and TOGNONI, G. Taratura e standardizzazione italiana di test neuropsicologici. *The Italian Journal of Neurological Sciences, suppl. 6*: 1987.
- TODD, J. The syndrome of Alice in Wonderland. *Canadian Medical Association Journal*, 73: 701-704, 1955.
- WARRINGTON, E.K., and JAMES, M. Visual apperceptive agnosia. A clinico-anatomical study of three cases. *Cortex*, 24: 13-32, 1988.
- WEINSTEIN, S. Neuropsychological studies of the phantom. In A.L. Benton, (Ed.), *Contributions to Clinical Neuropsychology*, Chicago: Aldine, 1969, Ch. 3.

Hans Spinnler, Clinica Neurologica III - Polo Didattico S. Paolo - Ospedale San Paolo, Via di A. Starabba Rudini, 8 - 20142 Milano, Italy. E-mail: hansum@imiucca.csi.unimi.it

(Received 8 May 97, accepted 15 July 1997)