

4. Poewe WH, Lees AJ, Stern GM. Dystonia in Parkinson's disease: clinical and pharmacological features. *Ann Neurol* 1988;23:73-78.
5. Mandir AS, Rowland LH, Dougherty PM, Lenz FA. Microelectrode recording and stimulation techniques during stereotactic procedures in the thalamus and pallidum. *Adv Neurol* 1997 (in press).
6. Laitinen LV, Bergenheim AT, Hariz MI. Leksell's posteroventral pallidotomy in the treatment of Parkinson's disease. *J Neurosurg* 1992;76:53-61.
7. Lozano AM, Lang AE, Galvez JN, et al. Effect of GPi pallidotomy on motor function in Parkinson's disease. *Lancet* 1995;346:1383-1387.
8. Iacono RP, Shima F, Lonser RR, Kuniyoshi S, Maeda G, Yamada S. The results, indications, and physiology of posteroventral pallidotomy for patients with Parkinson's disease. *Neurosurgery* 1995;36:1118-1125.
9. Sutton JP, Couldwell W, Lew MF, et al. Ventroposterior medial pallidotomy in patients with advanced Parkinson's disease. *Neurosurgery* 1995;36:1112-1116.
10. Nutt JG. Levodopa-induced dyskinesia: review, observations, and speculations. *Neurology* 1990;40:340-345.
11. Verhagen Metman L, Van den Munckhof P, Klaassen AAG, Blanchet P, Mouradian MM, Chase TN. Effects of supra-threshold levodopa doses on dyskinesias in advanced Parkinson's disease. *Neurology* 1997;49:711-713.
12. Boyce S, Clarke CE, Luquin R, et al. Induction of chorea and dystonia in parkinsonian primates. *Mov Disord* 1990;5:3-7.
13. Mitchell JJ, Luquin R, Boyce S, et al. Neural mechanisms of dystonia: evidence from a 2-deoxyglucose uptake study in a primate model of dopamine agonist-induced dystonia. *Mov Disord* 1990;5:49-54.
14. Iacono RP, Kuniyoshi SM, Lonser RR, Maeda G, Inae AM, Ashwall S. Simultaneous bilateral pallidotomy for idiopathic dystonia musculorum deformans. *Pediatr Neurol* 1996;14:145-148.
15. Vitek JL, Evatt M, Zhang J, et al. Pallidotomy is an effective treatment for patients with medically intractable dystonia [Abstract]. *Mov Disord* 1997;12:31.
16. Marsden CD, Parkes JD, Quinn N. Fluctuations of disability in Parkinson's disease—clinical aspects. In: Marsden CD, Fahn S, eds. *Movement disorders*. London: Butterworth, 1981:96-122.
17. Nutt JG. Dyskinesia induced by levodopa and dopamine agonists in patients with Parkinson's disease. In: Lang AE, Weiner WJ, eds. *Drug-induced movement disorders*. New York: Futura Publishing Co, Inc, 1992:281-314.

Cortical Action Tremor and Focal Motor Seizures After Parietal Infarction



Stroke is the most frequent cause of epileptic seizures in the elderly.¹⁻⁷ When the ischemic area is located subcortically, tremor occasionally occurs.⁸⁻¹¹ The occurrence of both tremor and focal motor seizures as a sequel to stroke has not been reported. We describe a patient suffering from focal motor seizures of the contralateral hand and forearm after right pari-

etal infarction who also developed a rhythmic action tremor restricted to the same region. Whereas the seizures were controlled by therapy with carbamazepine, the action tremor persisted for another year before disappearing spontaneously. The association of tremor and seizures is discussed with regard to a common pathogenesis.

Case Report

A 68-year-old man with preexisting atrial fibrillation, arterial hypertension, and diabetes mellitus developed weakness of the left arm that he considered too mild to see a physician. Some weeks later, recurrent spontaneous focal motor seizures restricted to his left forearm occurred with consecutive Todd's paresis. The frequency of seizures without medication was one every third or fourth day. At times, the jerking was vigorous enough to make the patient lose his balance and fall. Neither Jacksonian march nor secondary generalization of seizures occurred. In addition to these spontaneous motor seizures, opposition of his left thumb and index finger triggered rhythmic tremor-like jerking of his left forearm muscles (see the videotape). This action tremor was confined to the period of continuous voluntary muscle contraction and was not observed during Todd's paresis. The presence or absence of focal motor seizures did not have considerable impact on tremor severity and frequency.

Clinical examination showed moderate weakness of the left face and arm, with exaggerated tendon reflexes of the left arm. Surface electromyographic recordings from left abductor pollicis brevis and first dorsal interosseus as well as from forearm flexor and extensor muscles showed rhythmic cocontractions of agonist and antagonist muscles at a frequency of 4-5 s when the thumb and index finger were voluntarily opposed; individual tremor bursts lasted 80-100 ms (Fig. 1). Even repeated interictal electroencephalographic (EEG) recordings did not show epileptic discharges during or in the absence of action tremor; intermittent regional slowing was sometimes found over the right parietal cortex. The amplitudes of cortical sensory-evoked potentials were normal (4 μ V with left median nerve stimulation, 3.5 μ V with right median nerve stimulation, and 0.5 μ V with either tibial nerve stimulation), with prolonged latencies resulting from polyneuropathy. Also, motor-evoked potentials in abductor pollicis brevis muscles were of normal amplitude (2.0 mV) and latencies (23.0 ms, right; and 23.7 ms, left). Transcranial magnetic stimulation did not induce repetitive tremor-like discharges or focal motor seizures. Cranial computed tomography and magnetic resonance imaging showed a hypodensity-hyperintensity in the white matter underlying the right parietal cortex (Fig. 2).

During the following year, the patient's left facial and arm paresis gradually improved, leaving a left forearm pronator drift and slowness of rapid repetitive movements. With doses of up to 600 mg phenytoin per day, therapeutically effective serum levels could not be established, and focal motor seizures persisted. Thus, the patient was treated with carbamazepine, which completely abolished spontaneous seizures for 1 year. He was gradually tapered off carbamazepine, and his motor seizures have not recurred for >18 months. Action tremor of the left hand and forearm initially persisted, however, under medication with carbamazepine for 1 more year before gradually disappearing without any additional medication.

A videotape accompanies this article.

Received April 16, 1996; revisions received November 6, 1996, and June 19, 1997. Accepted July 14, 1997.

Address correspondence and reprint requests to Dr. A. Schulze-Bonhage at Neurologische Klinik, Städtische Kliniken, Kassel, Germany.

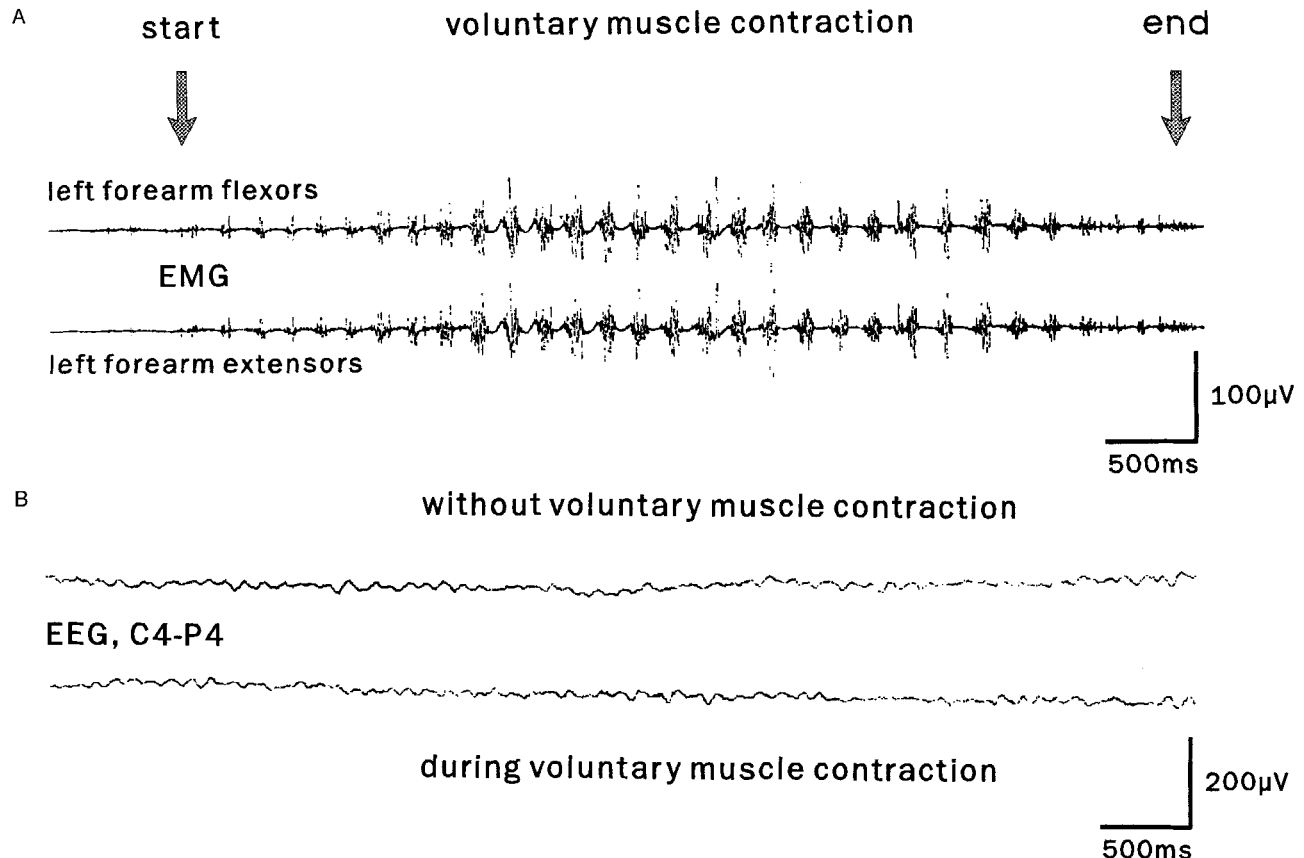


FIG. 1. (A) Surface electromyographic recordings from left forearm flexor and extensor muscles during voluntary opposition of the left thumb and index finger. During action, agonist and antagonist muscles discharge synchronously at 4–5 Hz. (B) Bipolar electroencephalographic (EEG) recordings over the right central region with and without contralateral tremor activity from the same recording session. There is no evidence of tremor-related EEG changes.

Discussion

Focal motor seizures after cerebral infarction are considered to be the result of focal hyperexcitability in the cortical border zone of the infarct. There is experimental evidence that inhibition to paired electrical pulses in this region is diminished probably as a result of reduced GABAergic input to pyramidal cells.¹² The mechanism of tremor generation after cortical infarction is less well understood.

There are reports of patients suffering from tremor of probable cortical origin^{13,14} without morphologically identifiable lesions. These patients were reported to have rhythmic electromyographic discharges at frequencies of 9–18 s particularly during action. Lance–Adams syndrome, myoclonus epilepsy, and opsoclonus–myoclonus syndrome were the respective underlying causes. Surface EEG recordings were normal in most cases. Back-averaging of EEG activity revealed a cortical pre-movement potential, and there were giant somatosensory-evoked potentials (SSEPs), from which the concept of rhythmic cortical myoclonus underlying the clinical phenomenon of tremor in these patients emerged (see also Hallett¹⁵). Treatment with clonazepam had some effect. In our patient, tremor frequency was slower, and neither EEG spikes nor giant SSEPs were present.

The 5 s writing tremor after cortical infarction in the case

reported by Kim and Lee¹⁰ shares some clinical characteristics with the tremor of our patient, but their patient's tremor was not task specific. The simultaneous appearance of spontaneous focal motor seizures and action-induced tremor in the same part of the body after cortical infarction suggests some common mechanism in their generation. Focal motor seizures may be the clinical manifestation of spontaneous repetitive firing of neurons in the border zone of the infarction. The propensity of the same region to discharge rhythmically may also become clinically apparent in the form of tremor-like contractions resulting from excitatory input during voluntary contraction of forearm muscles.

Carbamazepine administration suppressed the seizures, whereas action-induced tremor persisted for some time. During action, the tonically active pyramidal tract neurons may have been depolarized sufficiently to relay the otherwise subthreshold inputs from the border zone of infarction (see also Ferbert and Gerwig⁸); alternatively, tonic pyramidal cell output might have activated the region generating rhythmic discharges either axon collaterals or indirectly by way of recurrent sensory input. Similar to our patient with focal motor seizures, spontaneous resolution of *epilepsia partialis continua* is well recognized¹⁶ and may be the result of some local synaptic reorganization in the border zone of infarction, resulting in reduced excitability or inhibition of the spread of discharges.

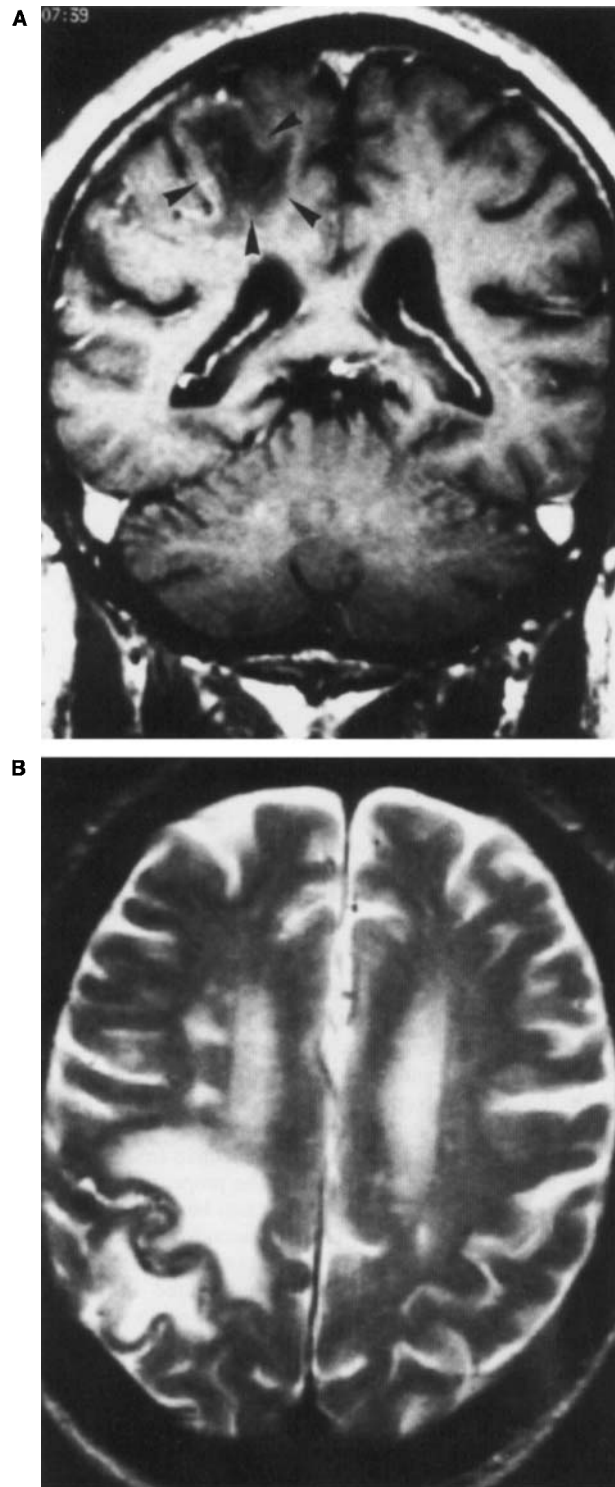


FIG. 2. Coronal T1-weighted (A) and axial T2-weighted (B) magnetic resonance images showing the extension of right parietal infarction 3½ months after the onset of symptoms.

The simultaneous development of motor seizures and action tremor in the same region in our patient suggests that hyperexcitability and synchronized rhythmic neuronal activity in the border zone of infarction may be the common cause of both focal epileptic seizures and cortical action tremor.

Legend to the Videotape

A few months after right parietal infarction, opposition of left thumb and index finger would trigger rhythmic action tremor restricted to the activated muscles. This tremor lasts as long as voluntary contraction is maintained. Tremor is also evident bringing the left index finger to the nose.

A. Schulze-Bonhage
A. Ferbert
Neurological Clinic
City Clinics
Kassel
Germany

References

1. Jackson JH. On the scientific and empirical investigation of epilepsies. In: Taylor J, ed. *Selected writings of John Hughlings Jackson*. London: Hodder and Stoughton, 1931:233.
2. Lühdorf K, Jensen LK, Plesner AM. Etiology of seizures in the elderly. *Epilepsia* 1986;47:458-463.
3. Cocito L, Favale E, Reni L. Epileptic seizures in cerebral arterial occlusive disease. *Stroke* 1982;13:189-195.
4. Gupta SR, Naheedy MH, Elias D, Rubino FA. Postinfarction seizures. *Stroke* 1988;19:1477-1481.
5. Olsen TS, Hogenhaven H, Thage O. Epilepsy after stroke. *Neurology* 1987;37:1209-1211.
6. Lesser RP, Lüders H, Dinner DS, Morris HH. Epileptic seizures due to thrombotic and embolic cerebrovascular disease in older patients. *Epilepsia* 1985;26:622-630.
7. Lancman ME, Golimstok A, Norscini J, Granillo. Risk factors for developing seizures after a stroke. *Epilepsia* 1993;34:141-143.
8. Ferbert A, Gerwig M. Tremor due to stroke. *Mov Disord* 1993;8:179-182.
9. Kim JS. Delayed onset hand tremor caused by cerebral infarction. *Stroke* 1992;199:292-294.
10. Kim JS, Lee MC. Writing tremor after discrete cortical infarction. *Stroke* 1994;25:2280-2282.
11. Dethy S, Luxen A, Bidaut L, Goldman S. Hemibody tremor related to stroke. *Stroke* 1993;24:2094-2096.
12. Domann R, Hagemann G, Kraemer M, Freund HJ, Witte OW. Electrophysiological changes in the surrounding brain tissue of photochemically induced cortical infarcts in the rat. *Neurosci Lett* 1993;155:69-72.
13. Ikeda A, Kakigi R, Funai N, Neshige R, Kuroda Y, Shibasaki H. Cortical tremor: a variant of cortical reflex myoclonus. *Neurology* 1990;40:1561-1565.
14. Toro C, Pascual-Leone A, Deuschl G, Tate E, Pranzatelli MR, Hallett M. Cortical tremor: a common manifestation of cortical myoclonus. *Neurology* 1993;43:2346-2353.
15. Hallett M. Myoclonus: relation to epilepsy. *Epilepsia* 1985;26:S67-S77.
16. Cockerell OC, Rothwell J, Thompson PD, Marsden CD, Shorvon SD. Clinical and physiological features of *epilepsia partialis continua*. *Brain* 1996;119:393-407.