



ELSEVIER

Journal of Neurological Sciences 154 (1998) 89–90

JOURNAL OF THE
**NEUROLOGICAL
SCIENCES**

Case report: A veterinarian who collapsed after the delivery of a calf by cesarean section

Peter Berlit*, Christof Klöttsch

Department of Neurology, Alfried Krupp Hospital, 21 Alfried-Krupp-Str., 45117 Essen, Germany

Received 15 January 1997; revised 4 March 1997; accepted 21 March 1997

Abstract

We report a patient who experienced internal carotid artery dissection with cerebral ischemia and cranial nerve involvement. The clinical features, the diagnostic approach and the therapeutic options are discussed in view of the recent literature. © 1998 Elsevier Science B.V.

Keywords: Dissection; Internal carotid artery; Stroke; Anticoagulation; Magnetic resonance imaging

1. Case report

A 62-year-old veterinarian was called to the delivery of a cow. A cesarean section became necessary and he had to perform the operation in the narrow stable, with the angry and restless cow. Using his maximum physical strength he opened up the uterus and delivered a heavy calf. At this time, he suffered from sudden, severe right-sided headache. He was able to finish the operation, but noticed blurred vision of his right eye and dysarthria. Thirty minutes after the onset of the headache he collapsed with a left-sided hemiparesis. On admission in the hospital, he presented a moderate sensorimotor hemiparesis on the left with extensor plantar response. There were a mild facial palsy on the left, a right sided Horner's syndrome, and a deviation of the tongue to the right side (right hypoglossal paresis). While cranial computed tomography (CCT) and Doppler sonography of the extracranial vessels were normal, magnetic resonance imaging (MRI) revealed a bleeding into the vessel wall of the right internal carotid artery prior to and in the carotid canal of the petrous bone (Fig. 1). The dissection of the ICA was confirmed by

digital subtraction angiography and the patient was put on anticoagulants. His hemiparesis and twelfth-nerve palsy improved gradually and he presented an isolated Horner's syndrome on the right at control-examination four months later. Control angiography showed a normal lumen of the right ICA, and anticoagulants were discontinued.

The average annual incidence of spontaneous dissections of the ICA is 2.6 per 100 000 persons (Schievink et al., 1993). They occur most frequently more than 2 cm distal to the origin of the ICA, especially before entry of the artery into the petrous bone. Physical activities as bowling, coughing, vigorous nose-blowing and trivial trauma antedate dissections in many patients (Sturzenegger, 1995). Common symptoms signalling the dissection are unilateral headache (hemicrania) and oculosympathetic paresis (Horner's syndrome) (Silbert et al., 1995). Cranial nerve palsies include frequently the hypoglossal nerve as in our patient. Focal cerebral ischemia occurs usually delayed after hours to days, following thrombus formation distal to the dissection with arterio-arterial embolism. While angiography is still performed for the diagnosis of ICA-dissection in many centers, non-invasive diagnostic approaches including ultrasonography, dynamic computed tomography, and MRI are increasingly accepted as reliable methods (Zuber et al., 1994; Levy et al., 1994; Ozdoba et al., 1996). The semilunar signal hyperintensity on axial MRI in our patient

*Correspondence to: Prof. Dr. Med. P. Berlit, Department of Neurology, Alfried Krupp Hospital, 21, Alfried-Krupp-Str., 45117 Essen, Germany. Tel.: +49 201 4342528; fax: +49 201 4342377.

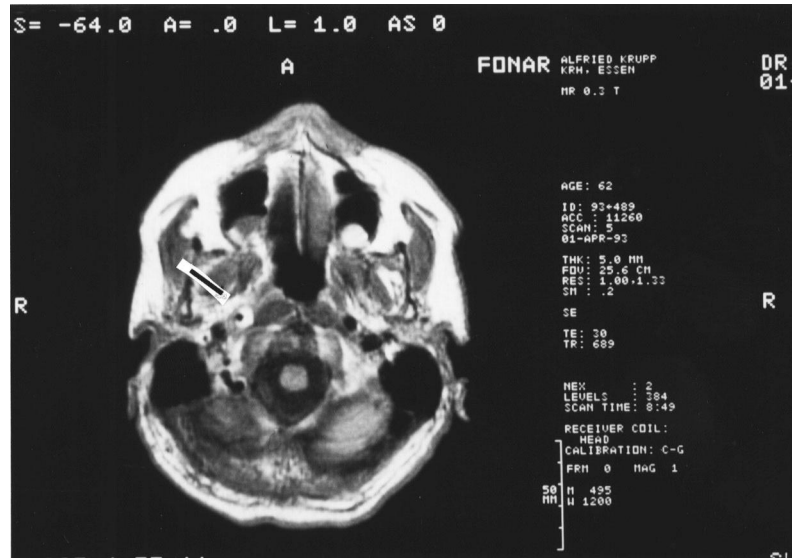


Fig. 1. MRI of the skull base. Narrowed eccentric signal void of the right ICA surrounded by a semilunar signal hyperintensity.

corresponds to the mural hematoma. Angiography revealed an irregular narrowing of the artery, the so called 'string sign'. Anticoagulation is recommended in order to avoid secondary thrombotic or embolic complications of the dissection though there is no definite study showing its benefit. About 85 percent of ICA-dissections are found to have improved or normalized at the time of follow up-angiography. ICA-dissection is a benign condition; delayed recurrence has been reported but is uncommon and often runs an oligosymptomatic course (Bassetti et al., 1996).

References

- Bassetti, C., Carruzzo, A., Sturzenegger, M., Tuncdogan, E., 1996 Recurrence of cervical artery dissection. A prospective study of 81 patients. *Stroke*. 27: 1804–1807.
- Levy, C., Laissy, J.P., Raveau, V. et al., 1994 Carotid and vertebral artery dissections: three dimensional time of flight MR angiography and MR imaging versus conventional angiography. *Radiology*. 190: 97–103.
- Ozdoba, C., Sturzenegger, M., Schroth, G., 1996 Internal carotid artery dissection: MR imaging features and clinical–radiologic correlation. *Radiology*. 199: 191–198.
- Schievink, W.I., Mokri, B., Whisnant, J.P., 1993 Internal carotid artery dissection in a community. Rochester, Minnesota, 1987–1992. *Stroke*. 24: 1678–1680.
- Silbert, P.L., Mokri, B., Schievink, W.I., 1995 Headache and neck pain in spontaneous internal carotid and vertebral artery dissections. *Neurology*. 45: 1517–1522.
- Sturzenegger, M., 1995 Spontaneous internal carotid artery dissection: early diagnosis and management in 44 patients. *J Neurol*. 242: 231–238.
- Zuber, M., Meary, E., Meder, J.-F., Mas, J.-L., 1994 Magnetic resonance imaging and dynamic CT scan in cervical artery dissections. *Stroke*. 25: 576–581.