



ELSEVIER

Journal of Neurological Sciences 154 (1998) 94–100

JOURNAL OF THE
**NEUROLOGICAL
SCIENCES**

Uncommon presentations of neurocysticercosis

I.M.S. Sawhney^{a,*}, G. Singh^a, O.P. Lekhra^a, S.N. Mathuriya^b, P.S. Parihar^a, S. Prabhakar^a

^a*Department of Neurology, Postgraduate Institute of Medical Education and Research, Chandigarh-160012, India*

^b*Department of Neurosurgery, Postgraduate Institute of Medical Education and Research, Chandigarh-160012, India*

Received 27 December 1996; received in revised form 18 June 1997; accepted 27 June 1997

Abstract

Neurocysticercosis commonly presents with seizures, raised intracranial tension and dementia. The unusual location of the cysts may result in uncommon manifestations mimicking a host of neurological disorders. Ten patients with neurocysticercosis with rare clinical presentations have been described in this series. These include dorsal midbrain syndrome, isolated bilateral ptosis, papillitis, cerebral hemorrhage, painful cervical radiculopathy, progressive swelling of arm, paraplegia due to intramedullary cyst, third ventricular cyst, dystonia and nominal aphasia masquerading as transient ischaemic attacks. The clinical details and possible mechanisms for these rare presentations are discussed. © 1998 Elsevier Science B.V.

Keywords: Neurocysticercosis; Uncommon manifestations; Mesencephalic syndrome; Cerebral hemorrhage; Papillitis; Dystonia; Nominal aphasia; Intramedullary cyst

1. Introduction

Neurocysticercosis is a common parasitic infection of the central nervous system in the Indian subcontinent, central and south America, Spain and Eastern Europe (ILAE, 1994; Schantz et al., 1994; Tsang and Wilson, 1995). Its incidence is rising in the non-endemic areas because of rising rates of immigration from endemic countries (DelBrutto et al., 1988; Sorvillo et al., 1992; Shandera et al., 1994). Clinical manifestations depend upon cyst load, topographic location of cysts and the host's immune response (DelBrutto et al., 1988). The disease has pleomorphic presentations. The common clinical features are seizures, raised intracranial tension and dementia (Sotelo et al., 1985; Wei et al., 1988). The uncommon clinical manifestations include pure motor hemiparesis, ataxic hemiparesis, homonymous hemianopia, Parinaud's syndrome, cerebellopontine angle syndrome, Brown-Sequard syndrome and stroke (Kaene, 1982; McCormick,

1985; Sotelo et al., 1985; Sharma et al., 1987; Barinagarmenteria and DelBrutto, 1988, 1989). It is important to recognise the rare presentations of the disease as these can mimic a number of other neurological disorders. The lack of awareness of these uncommon presentations may lead to wrong diagnosis, especially in tropical countries where diagnostic facilities are limited because of a paucity of resources. We report some of the rare clinical manifestations.

2. Patients

Ten cases of neurocysticercosis with rare clinical manifestations were admitted to the department of Neurology and Neurosurgery, Postgraduate Institute of Medical Education and Research, Chandigarh, India, in the last ten years. The diagnosis of cysticercosis was made by clinical course and radiological tests. Immunological tests for cysticercosis were positive in cases 4 and 10. Histo-

*Corresponding author.

Table 1
Case summaries of neurocysticercosis

Case no.	Age (years)/sex	Clinical features	Investigations	Therapy and outcome	Uncommon features	Localisation
1	42/ male	Left partial motor seizures for eight years Diplopia, gradual loss of vision and swaying to the left side for two months Fully conscious, bilateral papilloedema, skew deviation of eyes, upward gaze palsy, left hemiparesis, bilateral extensor plantars	CT scan—multiple hypodense lesions left frontal, parietal and occipital regions Mild hydrocephalus	Anticonvulsants Steroids Ventriculo peritoneal shunt—no relief Right partial frontal lobectomy with enucleation of cysts—had partial relief	Mesencephalic syndrome, upward gaze palsy, skew deviation	Midbrain
2	4/ Female	Low grade fever and headache for two months drooping of eyelids for two weeks Fully conscious, bilateral papilloedema bilateral isolated ptosis with intact pupillary reflexes and ocular movements	CT scan—bilateral multiple ring-enhancing lesions with perifocal oedema One lesion in midbrain (Fig. 1)	Steroids Almost complete recovery	Mesencephalic syndrome Isolated bilateral ptosis	Midbrain
3	7/ Female	Rapid diminution of vision and disc oedema in right eye (papillitis) for seven days Developed recurrent seizures, raised ICT and bilateral post papillaematous optic atrophy within two months of visual symptoms	CT scan—white matter oedema only MRI—multiple cysticerci	Anticonvulsants Steroids Albendazole Seizures and raised ICT controlled; vision—no recovery	Papillitis	Optic nerve
4	10/ Male	Headache, vomiting, right partial motor seizures for five days Developed right hemiparesis six weeks later	CT scan on admission —normal Repeat CT—left parietal hematoma (Fig. 2) Four vessel angiography —normal MRI—multiple cysts	Steroids Albendazole No improvement	Haemorrhagic stroke	Left parietal lobe
5	13/ Male	Severe neck pain, headache, vomiting and neck rigidity Painful restriction of neck movements and bilateral papilloedema Developed seizures in later part of illness	Cervical spine x-rays —normal Cranial CT and myelo CT —normal CSF cells—normal, protein = 90 mg%, normal sugar MRI—multiple cysts Tonsillar herniation	Antituberculosis therapy—no response Steroids Praziquantel Anticonvulsants	Cervical radiculopathy Tonsillar herniation	Posterior fossa
6	45/ Female	Gradually progressive swelling and pain over right arm	Plain x-ray right arm—multiple radiopaque lesions (Fig. 3a–b)	Operation was done AVM riddled with clumps of cysts Complete recovery	AVM riddled with cysts	Muscle

Table 1. Continued

Case no.	Age (years)/sex	Clinical features	Investigations	Therapy and outcome	Uncommon features	Localisation
7	28/ Male	Pain in upper dorsal region followed by paraesthesia in lower limbs Developed complete paraplegia with D ₂ sensory level and bladder involvement	Myelo CT—intramedullary lesion at D ₁ MRI—spine neurocysticercosis cyst (Fig. 4) CSF: 40 cells/mm ³ Lymphocytes: 50% Polymorphs: 50% Protein: 80 mg% Sugar: 30 mg%	Operation—whitish cyst (cysticercus) 1 cm in size Improved—grade 4 muscle power and full control of bladder in six months	Compressive myelopathy	Intramedullary cyst
8	16/ Female	Headache and progressive diminution of vision for two years Raised ICT, diplopia for twenty days	Skull X-ray erosion of dorsum sellae CT—dilated lateral ventricles isodense mass in anterior third ventricle Conray ventriculogram—cyst in anterior third ventricle (Fig. 5)	Operation—single cyst of NCC removed Symptoms relieved one week after surgery	—	Third ventricular cyst
9	21/ Male	Left side frontal headaches associated with occasional vomiting for two years Complex partial seizures for two years Episodic dystonic posturing of right upper and lower limbs lasting from a few minutes to hours	EEG: generalised epileptiform discharges CT: hypodense cysts pars interna of globus pallidi, ring-enhancing lesion in left corona radiata, bifrontal diffuse white matter oedema	Steroids Anticonvulsants Improved	Unilateral dystonia	Temporal/ frontal lobe
10	45/ Female	Hypertension for five years Three episodes of transient aphasia lasting for 10–15 min	CT—ring-enhancing lesion with mild perifocal oedema over left Sylvian fissure	Asymptomatic on anticonvulsant therapy	Transient ischaemic attacks	Left Sylvian fissure

ICT, intracranial tension; AVM, arteriovenous malformation; NCC, neurocysticercosis.

pathological confirmation was available in four cases. The cases are summarised in Table 1.

3. Discussion

The uncommon presentations of neurocysticercosis in this series (Table 1) are as follows:

3.1. Mesencephalic syndrome

The clinical features of this syndrome found in the cases studied include upward gaze palsy, convergence retraction nystagmus, eyelid retraction, pupillary abnormalities and skew deviation. The common underlying pathology is obstructive hydrocephalus (Kaene, 1982) due to a cyst in the third or fourth ventricle or granulomatous ependymitis secondary to degenerating intraventricular cyst. It can result from communicating hydrocephalus, which develops in 25% of cases of neurocysticercosis because of arachnoiditis or meningeal fibrosis (Lobato et al., 1981; Sotelo et al., 1985; Sotelo and Martin, 1987). The syndrome has also been seen because of cysticercoid arachnoiditis involving the mid brain. The arachnoid adhesions in the interpeduncular and prepontine cisterns lead to occlusion of paramedian and mesencephalic arteries, resulting in multiple areas of ischaemic necrosis in the mesencephalon. Finally, a parenchymal cyst located in the dorsal mid brain may be responsible for this syndrome (Fig. 1). This mechanism appears to be operative in case nos. 1 and 2.

3.2. Papillitis

Papilledema resulting in optic atrophy is well known in cases of neurocysticercosis with chronic raised intracranial tension. However, papillitis as a presenting feature of neurocysticercosis has not been documented. The rapid loss of vision associated with disc oedema and the absence of symptoms of raised intracranial tension at the time of first presentation are consistent with the diagnosis of papillitis in case no. 3. She developed symptoms of raised intracranial tension and seizures two months later.

4. Stroke

The association of cerebrovascular disease with stroke is well recognised (Sotelo et al., 1985; Barinagarrementeria and DelBrutto, 1988, 1989; Penring et al., 1992; DelBrutto, 1992; Monteiro et al., 1994; Levy et al., 1995). The incidence of stroke in neurocysticercosis varies from 2.0 to 11.8% (Sotelo et al., 1985; DelBrutto, 1992). Vascular occlusion can occur as a result of superficial cortical vessel thrombosis due to chronic meningitis (Grisolia and Wiederholt, 1982), vasculitis (Sotelo et al., 1985), lacunar infarcts due to endarteritis of small vessels (Barinagarrementeria and DelBrutto, 1988, 1989) and occlusion of the middle cerebral artery due to cysts or arachnoiditis (Penring et al., 1992). All the cases reported in literature so far presented with occlusive stroke. Case no. 4 is unique because of the presence of parenchymal hemorrhage (Fig.

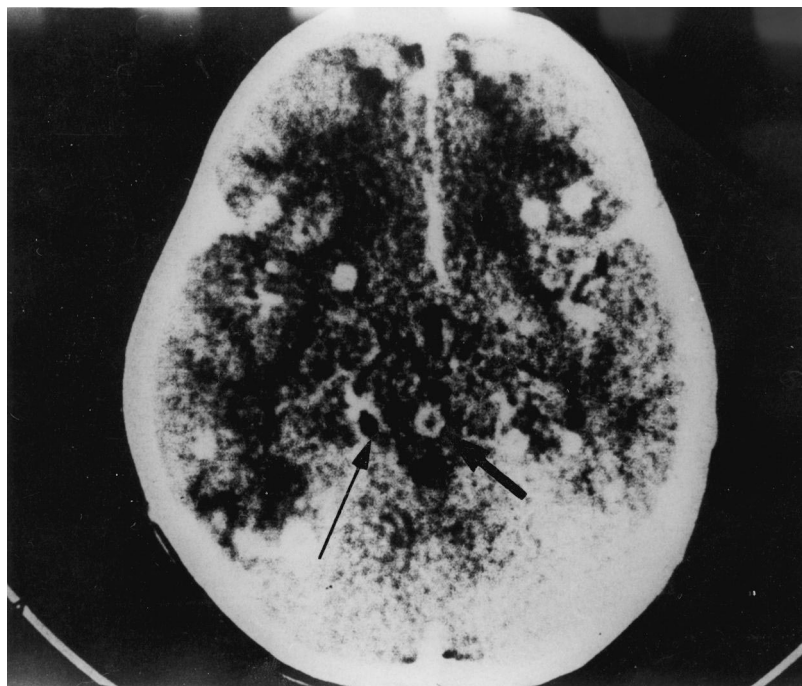


Fig. 1. Contrast-enhanced CT scan showing multiple ring lesions of neurocysticercosis. There is a ring-enhanced lesion in the mid brain (thick arrow) responsible for mesencephalic syndrome. The thin arrow shows the quadrigeminal plate cistern around the mid-brain.

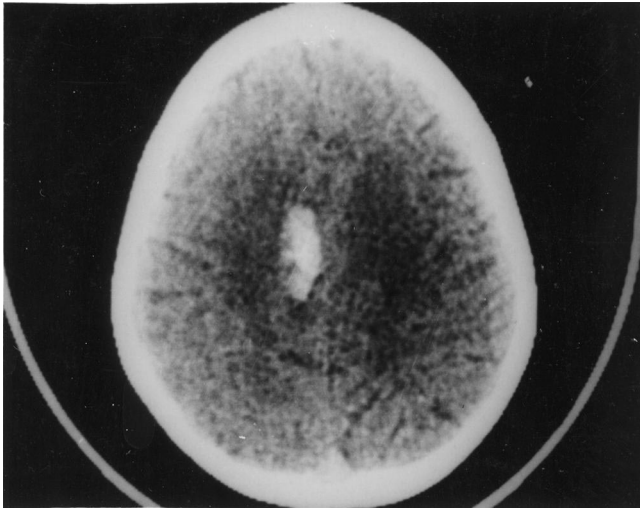


Fig. 2. Non-contrast CT scan showing a left parietal hematoma.

2). The possible mechanism of parenchymal hemorrhage is rupture of mycotic aneurysm (Grisolia and Wiederholt, 1982), erosion of a degenerating cyst in the wall of a small vessel or a vasculitic hemorrhage (Sotelo et al., 1985).

4.1. Painful cervical radiculopathy

Cervical radiculopathy is a rare manifestation of neurocysticercosis. Case no. 5 presented with severe nuchal pain. As cranial CT was normal, a myelo CT was performed to rule out a high cervical compressive lesion and it did not reveal any abnormality. Magnetic resonance

imaging (MRI) confirmed the diagnosis of multiple cysticerci in the posterior fossa and inferior displacement of the tonsils. Tonsillar herniation was the cause of neck pain in this case. Nuchal pain and rigidity can occur in neurocysticercosis because of raised intracranial tension or meningitis. The clinical differentiation of these two conditions can be difficult because of the overlapping symptoms. The intracranial hypertension due to neurocysticercosis can prove to be life threatening. Chronic arachnoiditis is a frequent complication of cisternal cysticercosis and is associated with a prolonged course, multiple relapses and a high case-fatality rate (Joubert, 1993).

5. Intramedullary spinal cyst

In a large series of neurocysticercosis, 1–3.2% of cases were of spinal cysticercosis (Sotelo et al., 1985). Both intradural extramedullary and intramedullary (Queiroz et al., 1975; Garza-Mercado, 1976; Akiguchi et al., 1979; Kim and Weinberg, 1985; Savolardo et al., 1986) forms have been reported. Intramedullary cysticercosis is much less common than the extramedullary leptomeningeal disease. Sharma et al. (1987) reviewed the published literature of intramedullary spinal cysticercosis and found 32 published cases. Fifty six per cent of intramedullary cysts are located in the thoracic cord (Fig. 4). This predilection of the cysts for the thoracic spinal cord is linked to the regional spinal cord blood flow, which is highest in the thoracic cord. The presence of rapid spontaneous worsening because of the inflammatory re-

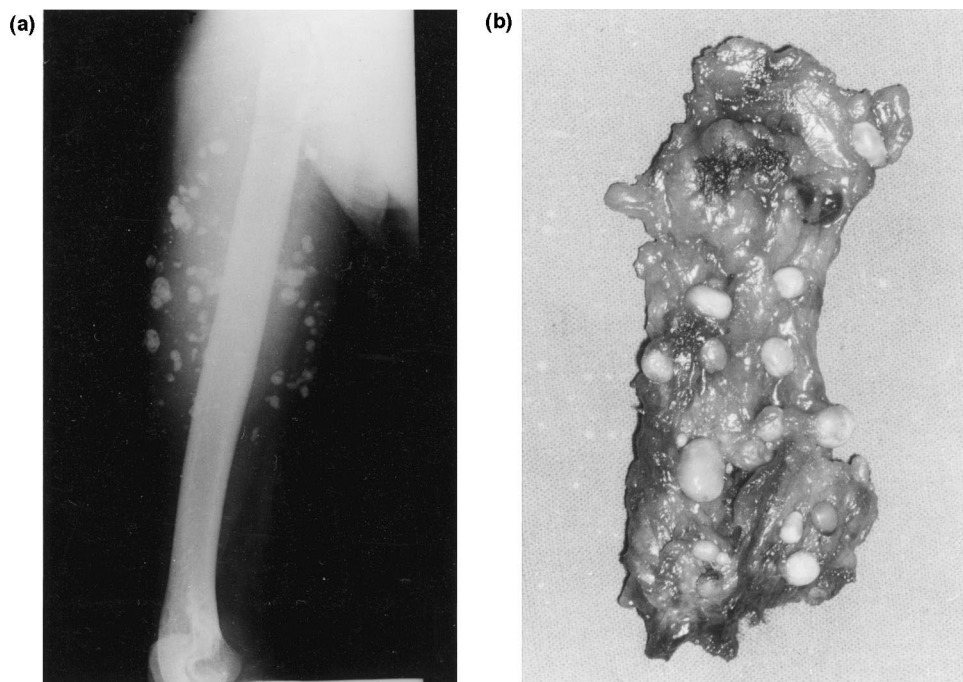


Fig. 3. (a) Radiograph of the limb showing soft tissue swelling with calcification. (b) Pathology specimen of the same showing multiple cysticerci.

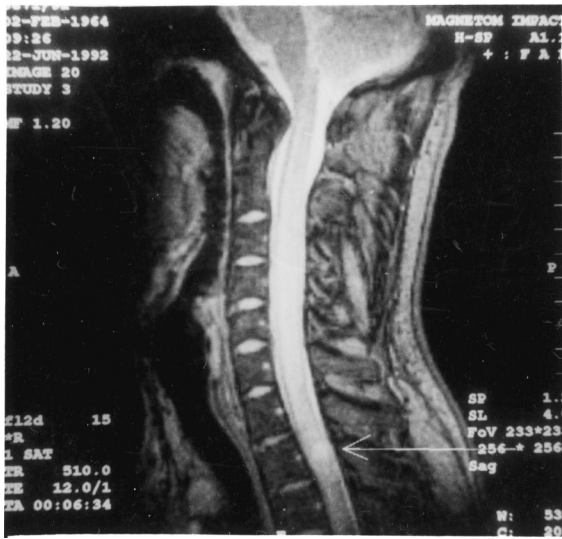


Fig. 4. MRI with T2 weighted image showing an intramedullary cyst in the dorsal spinal cord.

action to the cyst, associated systemic or cerebral cysticercosis, cerebrospinal fluid eosinophilia or a positive cerebrospinal fluid complement fixation test are features that may arouse suspicion that cysticercosis is the underlying pathology in compressive myelopathies.

5.1. Ventricular cysts

Intraventricular cysts are uncommon cysts that usually are larger than parenchymal cysts and may be free-floating or attached to the ventricular wall (Zee et al., 1984). The common site for these cysts is the fourth ventricle (Zee et al., 1993). Cysts in the third ventricle, as seen in case no. 8 (Fig. 5), are rare (Salazar et al., 1983). These cysts become symptomatic by blocking the aqueduct of Sylvius, resulting in obstructive hydrocephalus and raised intracranial tension.

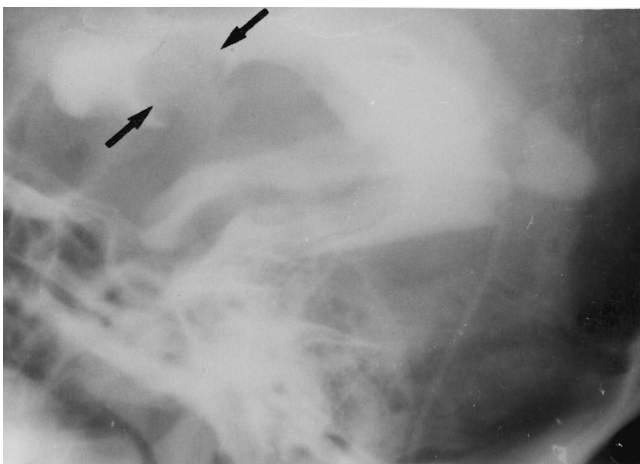


Fig. 5. Conray ventriculogram showing cyst (arrows) in the anterior third ventricle.

5.2. Dystonia

Unilateral dystonic posturing is an unusual feature of epilepsy and has been reported in complex partial seizures of temporal origin (Kotgal et al., 1989). Dystonia is contralateral to the epileptic focus and is probably due to the spread of ictal discharge to subcortical structures, namely the basal ganglia. The dystonia in case no. 9 was epileptic in nature, as the patient had typical complex partial seizures and electroencephalogram (EEG) abnormality. However, some of the attacks lasted for hours, mimicking symptomatic dystonia.

5.3. Transient ischaemic attacks

Case No. 10 was diagnosed to have transient ischaemic attacks because of recurrent transient neurological deficits and hypertension. The diagnosis of neurocysticercosis was established after the CT scan. The recurrent transient neurological deficit was due to partial seizures. It is well known that partial seizures can mimic transient ischaemic attacks.

The pleomorphic clinical presentation of neurocysticercosis can mimic a number of neurological syndromes. When a patient presents with rare clinical features, the diagnosis may be missed, especially in developing countries where investigative facilities are limited. The patients from endemic areas presenting with the neurological manifestations described above should have a high index of suspicion for neurocysticercosis and be investigated for it.

References

- Akiguchi, I., Fujiwara, T., Matsuyama, H., Maranka, H., Kamayama, M., 1979. Intramedullary spinal cysticercosis. *Neurology* 29, 1531–1534.
- Barinagarrementeria, F., DelBrutto, O.H., 1988. Neurocysticercosis and pure motor hemiparesis. *Stroke* 19, 1156–1158.
- Barinagarrementeria, F., DelBrutto, D.H., 1989. Lacunar syndrome due to neurocysticercosis. *Arch Neurol* 46, 415–417.
- DelBrutto, O.H., Garcia, E., Talmas, O., Sotelo, J., 1988. Sex related severity of inflammation in parenchymal brain cysticercosis. *Arch Intern Med* 148, 544–546.
- DelBrutto, O.H., 1992. Cysticercosis and cerebrovascular disease: a review. *J Neurol Neurosurg Psychiatry* 55, 252–254.
- Garza-Mercado, R., 1976. Intramedullary cysticercosis. *Surg Neurol* 5, 331–332.
- Grisolia, J.G., Wiederholt, W.C., 1982. CNS cysticercosis. *Arch Neurol* 39, 540–544.
- International League against Epilepsy, 1994. Relationship between epilepsy and tropical diseases. *Epilepsia*, 35, 89–93.
- Joubert, J., 1993. Cysticercal meningitis: a pernicious form of neurocysticercosis which responds poorly to praziquantel. *S Afr Med J* 77, 528–530.
- Kaene, J.R., 1982. Neuroophthalmic signs and symptoms of cysticercosis. *Arch Ophthalmol* 100, 1445–1448.
- Kim, K.S., Weinberg, P.E., 1985. Spinal cysticercosis. *Surg Neurol* 24, 80–82.
- Kotgal, P., Luders, H., Morris, H.H., Dinner, D.S., Wyllie, E., Godoy, J.,

- Rothner, A.D., 1989. Dystonic posturing in complex partial seizures of temporal onset. A new lateralising sign. *Neurology* 39, 196–201.
- Levy, A.S., Lillehei, K.O., Rubinstein, D., Stears, J.C., 1995. Subarachnoid neurocysticercosis with occlusion of major intracranial arteries: case report. *Neurosurgery* 36, 183–188.
- Lobato, R.D., Lames, E., Portillo, J.H., 1981. Hydrocephalus in cerebral cysticercosis: pathogenic and therapeutic considerations. *J Neurosurg* 55, 786–793.
- McCormick, G.F., 1985. Cysticercosis — a review of 230 patients. *Bull Clin Neurosci* 50, 76–101.
- Monteiro, L., Almeida-Pinto, J., Leite, I., Xavier, J., Correia, M., 1994. Cerebral cysticercus arteritis: five angiographic cases. *Cerebrovasc Dis* 4, 125–133.
- Penring, B., Litchman, C.D., Haier, L., 1992. Bilateral middle cerebral artery occlusions in neurocysticercosis. *Stroke* 23, 282.
- Queiroz, L.D.S., Pelegrino, A.F., Callegaro, D., Faria, L.L.D., 1975. Intramedullary cysticercosis. Case report, literature review and comments on pathogenesis. *J Neurol Sci* 26, 61–70.
- Salazar, A., Sotelo, J., Martinez, H., Escobedo, F., 1983. Differential diagnosis between ventriculitis and fourth ventricle cyst in neurocysticercosis. *J Neurosurg* 59, 66–663.
- Savolardo, M., Cimino, C., Passeria, A., Mantina, L., 1986. Mobile myelographic filling defects — Spinal cysticercosis. *Neuroradiology* 28, 166–169.
- Schantz, P.M., Sarti, E., Plancarte, A., Wilson, M., Criales, L., Roberts, J., Flisser, A., 1994. Community-based epidemiological investigations of cysticercosis due to *Taenia solium*: comparison of serological screening tests and clinical findings in two populations in Mexico. *Clin Infect Dis* 18, 879–885.
- Shandera, W.X., White, A.C., Chen, J.C., Diaz, P., Armstrong, R., 1994. Neurocysticercosis in Houston, Texas — A report of 112 cases. *Medicine* 73(i) 37–52.
- Sharma, B.S., Banerjee, A.K., Kak, V.K., 1987. Intramedullary spinal cysticercosis. Case report and review of literature. *Clin Neurol Neurosurg* 89, 111–116.
- Sorvillo, F.J., Waterman, S.H., Richards, F.O., Schantz, P.M., 1992. Cysticercosis surveillance: locally acquired and travel related infection and detection of intestinal tapeworm carriers in Los Angeles. *Am J Trop Med Hyg* 47, 365–371.
- Sotelo, J., Guerrero, V., Rubio, F., 1985. Neurocysticercosis — a new classification based on active and inactive forms. A study of 753 cases. *Arch Intern Med* 145, 442–445.
- Sotelo, J., Martin, C., 1987. Hydrocephalus secondary to cysticercotic arachnoiditis: a long term follow up and review of 92 cases. *J Neurosurg* 66, 686–689.
- Tsang, V.C.W., Wilson, M., 1995. *Taenia solium* cysticercosis: an under recognised but serious public health problem. *Parasitol. Today* ii, 124–126.
- Wei, C.Z., Chu Jang, L., Jia-Mei, M., Meng-Chen, D., 1988. Cysticercosis of the central nervous system — A clinical study of 1400 cases. *Chin Med J* 101, 493–500.
- Zee, C.S., Segall, H.D., Apuzzo, M.L.J., Ahmadi, J., Dobbin, W.R., 1984. Intraventricular cysticercal cysts — further neuroradiological observations and neurosurgical implications. *Amer J Neuroradiol* 5, 727–730.
- Zee, C.S., Segall, H.D., Destian, S., Ahmadi, J., Apuzzo, M.L.J., 1993. MRI of intraventricular cysticercosis. *J Comput Assisted Tomogr* 17, 932–939.