

Significant Case Reports

Extrarolandic Origin of Spike and Myoclonus Activity in Epilepsia Partialis Continua: A Magnetoencephalographic and Positron Emission Tomography Study

J. Volkmann, MD

Department of Neurology
Heinrich-Heine-University
Moorenstr. 5
40225 Düsseldorf, Germany

R. J. Seitz, MD

Department of Neurology
Heinrich-Heine-University

H. W. Müller-Gärtner, MD

Institute for Medicine
Research Center Jülich
Jülich, Germany

O. W. Witte, MD

Department of Neurology
Heinrich-Heine-University

ABSTRACT

The dipole sources of interictal spike activity were localized and the myoclonus activity back-averaged by combined magnetoencephalography and surface electromyographic measurements in a child who had epilepsia partialis continua without a structural brain lesion. Dipole sources were matched with metabolic information obtained from interictal 5-fluoro-D-glucose positron emission tomography (PET) and superimposed onto high-resolution magnetic resonance images. Dipole sources of interictal epileptic discharges clustered within the inferior parietal cortex, which also showed a regional hypermetabolism on PET scans. The dipole sources of reafferent activity following myocloni in the postcentral gyrus were associated with a local hypometabolism.

Received Mar 26, 1996, and in revised form Sep 9, 1996, and May 6, 1997. Accepted for publication May 7, 1997.

Address correspondence to Dr Volkmann.

Although there was no obvious phase relationship between interictal spikes and myoclonic jerks, the myocloni were initiated from within the interictal spike area in the extrarolandic cortex. The data demonstrate that motor symptoms may be a remote effect of epileptic activity within functional brain circuits.

Key words: Epilepsia partialis continua, PET, EEG.

Volkmann J, Seitz RJ, Müller-Gärtner HW, Witte OW. Extrarolandic origin of spike and myoclonus activity in epilepsia partialis continua: a magnetoencephalographic and positron emission tomography study. *J Neuroimag* 1998;8:103–106

Epilepsia partialis continua (EPC) is a rare form of a partial epileptic status characterized by continuous myoclonic twitching of a body part. EPC can occur with a variety of etiologically different acute or chronic brain lesions including Rasmussen's encephalitis. Most authors describe a cortical origin of myoclonic activity in EPC.¹ Time-locked myoclonic and interictal spike activity in some patients with EPC suggests an initiation of myoclonic activity from within the spike-generating zone. In the majority of patients, however, polygraphic recordings fail to demonstrate an obvious phase relationship between epileptic and myoclonic discharges. Using electromyography (EMG)-triggered back-averaging of electroencephalographic (EEG) activity in a patient with EPC without premyoclonic EEG spikes, Celesia and colleagues² recently demonstrated that the source of myoclonic activity fell within the foot area of the primary motor cortex in close vicinity to an arteriovenous malformation presumably causing the disorder. The present authors combined magnetoencephalography (MEG), [¹⁸F]2-fluoro-2-deoxy-D-glucose positron emission tomography (FDG-PET), and high-resolution magnetic resonance imaging (MRI) to noninvasively localize the irritative (spike-generating) zone and symptomatic

genic (myoclonus-generating) zone in a child who had EPC without a structural brain lesion.

Case Report

The 11-year-old girl was the seventh child of healthy, nonconsanguineous parents, born after uneventful pregnancy and labor. At the age of 2 years the girl had a minor head injury as a result of a fall from a chair and shortly later developed stuttering. Motor and intellectual development was otherwise normal. Six months before admission to the hospital the girl experienced a first focal motor seizure on the right side of her body with secondary generalization. Within the following weeks, seizure frequency increased up to 12/hr regardless of the high doses of various anticonvulsive drugs administered. At the same time a rapidly progressive right-sided hemiparesis emerged. On admission to the authors' hospital, neurological examination revealed a right-sided hemiparesis and a continuous, approximately 1/sec myoclonic twitching of the right fingers. Somatosensory evoked potentials (SSEPs) showed increased conduction latencies (42.8 msec) after right tibial nerve stimulation but no giant potentials. Transcranial magnetic stimulation could not elicit a motor evoked response in the right anterior tibial muscle, despite normal amplitude and central conduction latencies to the other extremities. MRIs at the time of the recording were normal but previous MRIs had shown a diffuse edema of the left sensorimotor and parietal cortex. Positive cerebrospinal fluid (CSF) oligoclonal bands with preserved normal cell count suggested a chronic encephalitis. Rasmussen's encephalitis was discussed but the results of a brain biopsy were inconclusive.

Methods

Spontaneous interictal neuromagnetic activity was registered using a 74-channel dual-probe MEG system (Biomagnetic Technologies). The two MEG probes were centered around C3/C4 covering approximately two-thirds of each hemisphere (Fig 1). For dipole fitting, a spherical head model was chosen; it was

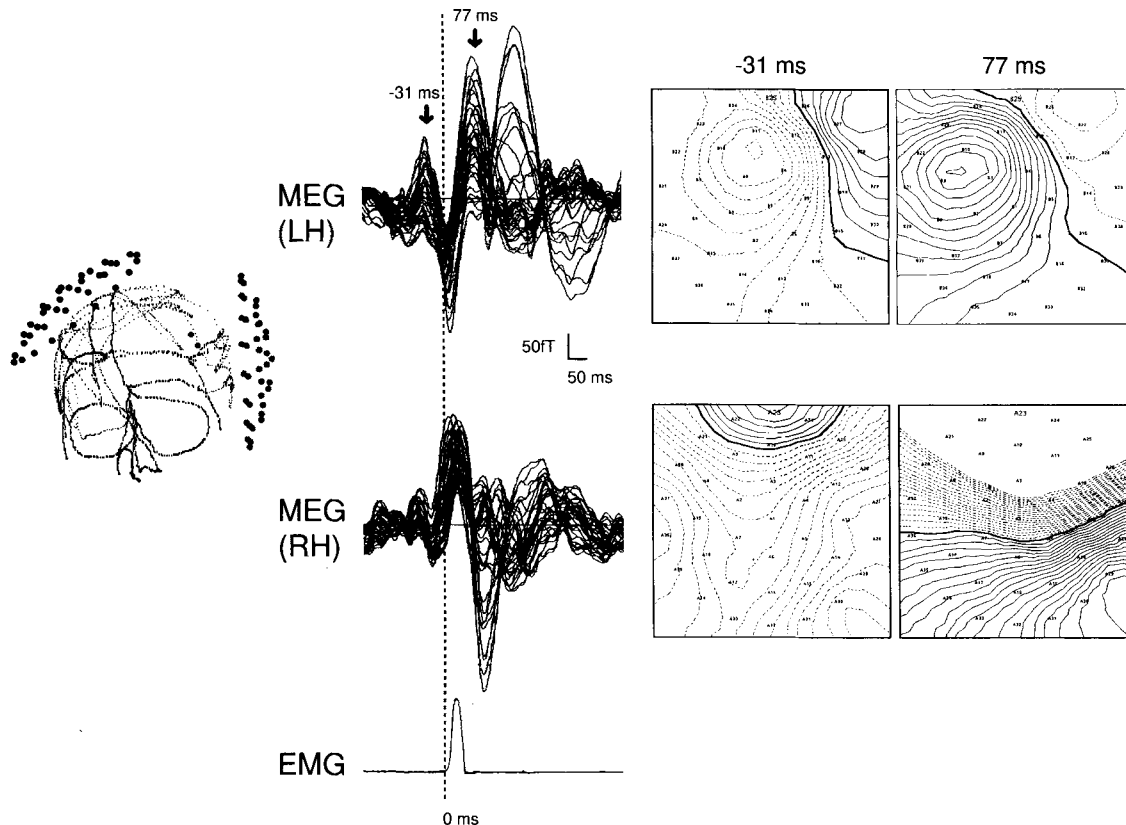


Fig 1. The back-averaged, jerk-locked MEG waveforms superimposed for all channels of the left (LH) and right hemispheric (RH) probe are shown. Dipolar field patterns (shown in isocontour diagrams on the right) resulting in dipole fits with low residual variance could only be observed around 30 msec prior and 80 msec after the onset of EMG activity over the left hemisphere. *Solid lines* in the isocontour diagrams indicate ingoing, and *dashed lines* indicate outgoing magnetic flux. For better orientation the position of each sensor of the dual-probe 37-channel MEG system is displayed on the left with respect to the digitized head surface of the patient.

determined by digitizing the surface of the subject's head and using an iterative algorithm to calculate the best-fitting sphere. Single equivalent dipole fits with a goodness of fit > 0.95 were used to compute mean dipole locations in a window of ± 5 msec around peak latencies for each of 27 interactively identified, interictal spikes. The rectified and integrated EMG activity of the flexor digitorum superficialis was used to trigger back-averaging of myoclonus activity (204 events). The MEG baseline was established in each epoch by DC-offset correction in the time period 500 to 250 msec prior to EMG onset. From the back-averaged waveforms and for each hemisphere, independent single equivalent dipole (ECD) solutions were computed for every sample point within a time window of -150 to 500 msec around EMG onset. Only those dipole fits that had a goodness of fit > 0.9 at latencies showing a clear dipolar field distribution were accepted for further analysis.

Immediately prior to MEG, FDG-PET was carried out using a Scanditronix PC 4096/7 WB PET camera as described in

detail elsewhere.³ No seizure activity was noticed clinically or on the EEG during PET scanning. Interictal spike rate and myoclonus activity were comparable during PET and MEG.

ECD and PET data were matched with the individual MRI anatomy (Siemens Magnetom, T1 three-dimensional [3D] flash sequence) using the surface-matching module of Analyze to align the MRI and PET volumina and in-house software to convert MEG dipole coordinates into MRI pixel coordinates based on fiducial markers.⁴ MRI sectioning, 3D rendering, and multimodal image integration were performed on a SUN workstation using Analyze software.

Hypermetabolic and hypometabolic areas on PET scans were defined as pixel values lying outside of a 2-standard deviation range around the mean cortical metabolism of the contralateral hemisphere. This statistical approach, which consists of the only way of looking at focal changes in brain metabolism in a single case, is justified in two regards: (1) Heiss and coworkers⁵ showed that for normal subjects, metabolic rates and kinetic con-

stants in FDG-PET may vary substantially among different subjects and cortical regions of the same subject, but not between the hemispheres of each individual. (2) In the present patient the ratio of the metabolic rate in the left and right hemisphere was 0.99 ± 0.02 , proving a significantly symmetrical hemispheric metabolism like that in normal subjects.

Results

Evaluation of the raw MEG and EMG traces revealed a random phase relationship between interictal spike and myoclonic activity. Less than 20% of myoclonic jerks were preceded by visible spike activity at random time intervals. On the other hand, spikes were often not followed by myoclonic jerks.

For 27 interactively identified, interictal spikes, clear dipolar magnetic field patterns were observed and allowed source localization using a single equivalent dipole model. Dipole sources for these spikes clustered within an area of approximately 60 cm^3 within the left inferior parietal lobule.

The jerk-locked, averaged waveforms

(see Fig 1) showed one prominent deflection in the premyoclonic period with a peak latency of 31 msec prior to EMG onset and three deflections in the postmyoclonic period with peak latencies of 77, 172, and 300 msec after EMG onset, which were all maximal over the left hemisphere. A large deflection with inward-directed flux in all channels over the left hemisphere and outward-directed flux in all right hemispheric channels during myoclonic jerks was presumably caused by a movement artifact and did not result in a localizable field distribution. Stable dipolar field patterns resulting in single equivalent dipole fits with low residual variance (goodness of fit > 0.90) could only be observed for the premyoclonic field 50 to 20 msec prior to EMG onset and for the first postmyoclonic field 56 to 100 msec after EMG onset (see Fig 1). Since the source locations varied little in the respective time periods, the dipole coordinates at peak latencies were chosen for anatomical coregistration with PET and MRI images. The second and third postmyoclonic fields at 172 and 300 msec after EMG onset resulted in more diffuse field patterns that could not be fitted using a single equivalent dipole model. The source of premyoclonic activity 31 msec before EMG onset localized to the anterior border of the spike area within the left inferior parietal lobule (goodness of fit = 0.956). Seventy-seven milliseconds after EMG onset of myoclonic activity, a dipolar generator in the left somatosensory cortex was observed (goodness of fit = 0.952) (Fig 2). This postmyoclonic field was consistent in latency, field distribution, and source location with the movement evoked field 1 (MEF1) normally obtained after voluntary finger movements.⁶ The MEF1 and its electrical counterpart most probably reflect reafferent activity to area 3a from muscle spindle and joint receptors.^{7,8}

FDG-PET showed increased FDG uptake in the left inferior posterior parietal

cortex—only partially overlapping the spike area. In addition, a focal hypermetabolism was found within the premotor cortex surrounded by decreased FDG uptake in prefrontal and sensorimotor cortex (see Fig 2). As remote effects, a significant hypermetabolism appeared in the left dorsal thalamus and right cerebellum.

Discussion

Noninvasive MEG and PET scans in the present patient suggest a cortical origin of EPC, in agreement with previous results of intraoperative cortical recordings.^{2,9–12} Demonstrated were (1) cortical generators of interictal epileptic fields, (2) the initiation of jerks in the interictal spike area, and (3) focal cortical abnormalities in FDG-PET.

Some features of the present patient deserve special attention: Dipole analysis revealed that interictal epileptiform activity was generated in the inferior parietal cortex. Despite an absence of a phase relationship between interictal spikes and myoclonic jerks, premyoclonic activity surprisingly originated from within the interictal spike area, as revealed by the back-averaging technique. Transcranial magnetic stimulation of the primary motor cortex revealed normal corticomuscular conduction latencies (17.2 msec to the left first dorsal interosseous muscle and 16.4 msec to the right first dorsal interosseous muscle). The latency of 31 msec between the premyoclonic field and myoclonus onset, therefore, suggests a polysynaptic transmission to the spinal

cord, probably via activation of the premotor cortex, that was hypermetabolic but showed no dipolar activity on MEG. Unfortunately, MEG did not identify the site of final corticospinal outflow, which may be related to multiple factors such as the presence of myoclonus-induced movement artifacts, limitations of the single equivalent dipole model, or contribution of radial current components to the generator.

While many reports emphasize that an abnormality within motor cortex itself is responsible for EPC,¹ Obeso and coauthors¹³ argued that via dense corticocortical connections other cortical areas may exert a remote effect on the motor cortex in patients with cortical myoclonus. This would also explain the giant SSEPs often observed in cortical reflex myoclonus: Shibasaki and colleagues¹⁴ suggested that the enhancement of the P1-N2 component is generated by the same mechanism that underlies myoclonus-related cortical spikes. The hyperexcitability in the somatosensory cortex might provide an increased input volley into the motor cortex, which then causes the jerk. In accordance with such an indirect generation of myoclonic activity, Cowan and associates¹⁰ presented a case of cortical myoclonus, EPC, and motor epilepsy in which surface EEG, intraoperative corticography, and PET revealed abnormal activity in the postcentral parietal cortex. After resection of the parietal focus, the cortical myoclonus and EPC disappeared.

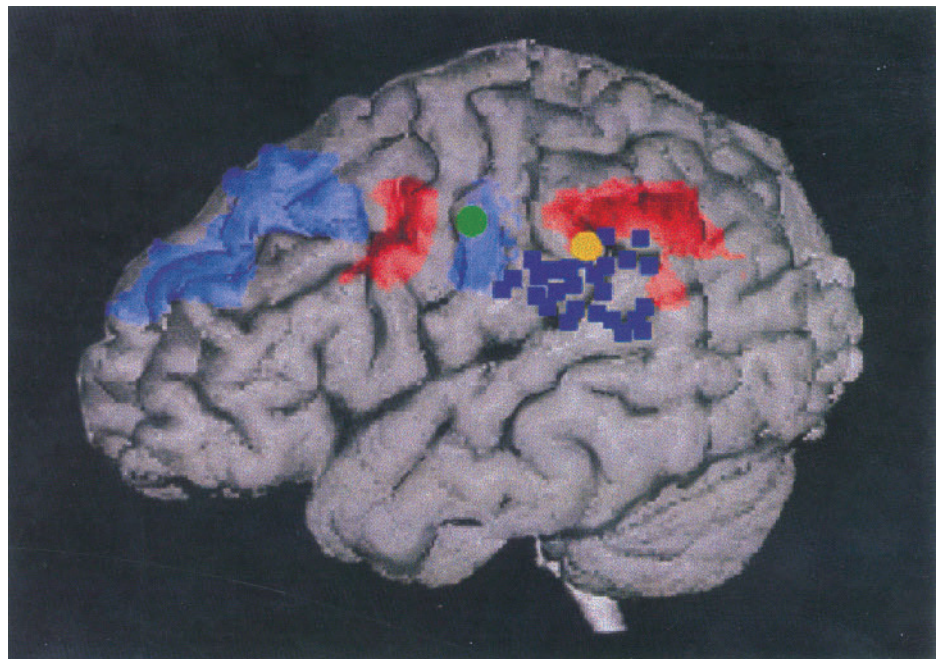


Fig 2. Summary of the cortical metabolic and electrophysiological changes related to epilepsy partialis continua in the investigated child. In a semitransparent 3D MRI rendering, areas of relative cortical hypermetabolism appear in red, while areas of cortical hypometabolism are in blue. Dipole sources of interictal spikes (*blue squares*), myoclonus-initiating activity (*yellow dot*), and myoclonus feedback activity (*green dot*) computed from MEG are superimposed.

Intuitively, one would expect a focal hypermetabolism in the area of the epileptic focus. Such a hypermetabolism has indeed been observed in some patients with EPC, and can also be observed in experimentally induced focal epilepsy.¹⁵ However, just as common has been the observation of a focal hypometabolism in patients with EPC.^{16,17} In the present patient areas with focal hypermetabolism and areas with hypometabolism were found. Although areas of regional hypermetabolism and interictal spike activity were adjacent in the inferior parietal cortex, there was only little overlap between them. A possible explanation would be a decoupling of electrophysiological activity and brain metabolism in this region, which has been described in animal models of focal brain lesions [18]. An additional area of focal hypermetabolism was situated in the premotor cortex and was probably related to the generation of epileptic jerks. The hypermetabolic areas were surrounded by areas of hypometabolism as also described for experimental epilepsy.¹⁵ Notably, the reafferent somatosensory activation fell into a zone with reduced metabolism. This may be due to the slow stimulus rate in addition to a partial volume effect based on the relatively low spatial resolution of PET and the small area of activated cortex,¹⁹ which were not sufficient to evoke focal metabolic increases within an area of pathologically reduced metabolism.

The present report shows that noninvasive techniques like MEG, PET, and MRI may be useful in analyzing the functional circuits involved in focal epileptic activity. In this respect the present case is an illustration of the conceptual framework put forward by Lüders²⁰ who differentiated between subregions of cortex related to the generation of interictal epileptic discharges (irritative zone), seizure onset (pacemaker zone), and ictal and interictal symptomatology (ictal symptomatogenic and functional deficit zone) in focal epilepsy. While the pacemaker zone—as in the present patient—usually resides within the irritative zone, the ictal symptomatogenic and functional deficit zone may be located remotely, sometimes even in the contralateral hemisphere, and affected by the spread of pathological activity.

References

1. Thomas JE, Reagan TJ, Klass DW. Epilepsia partialis continua. *Arch Neurol* 1977;34:266–275
2. Celesia GG, Parmeggiani L, Brigell M. Dipole source localization in a case of epilepsy partialis continua without premyoclonic EEG spikes. *Electroencephalogr Clin Neurophysiol* 1994;90:316–319
3. Seitz RJ, Schlaug G, Kleinschmidt A, et al. Remote depressions of cerebral metabolism in hemiparetic stroke: topography and relation to motor and somatosensory functions. *Hum Brain Mapping* 1994;1:81–100
4. Walter H, Seitz RJ, Knorr U, et al. Individual somatotopy of primary sensorimotor cortex revealed by intermodal matching of MEG, PET and MRI. *Brain Topogr* 1992;5:183–187
5. Heiss W-D, Pawlik G, Herholz K, et al. Regional kinetic constants and cerebral metabolic rate of glucose in normal human volunteers determined by dynamic positron emission tomography of [¹⁸F]-2-fluoro-2-deoxy-D-glucose. *J Cereb Blood Flow Metab* 1984;4:212–223
6. Kristeva R, Cheyne D, Deecke L. Neuromagnetic fields accompanying unilateral and bilateral voluntary movements: topography and analysis of cortical sources. *Electroencephalogr Clin Neurophysiol* 1991;81:284–298
7. Arezzo J, Vaughan HG, Koss BT. Relationship of neuronal activity to gross movement-related potentials in monkey pre- and postcentral cortex. *Brain Res* 1977;132:362–369
8. Arezzo J, Vaughan HG. Intracortical sources and surface topography of the motor potential and somatosensory evoked potential in the monkey. *Prog Brain Res* 1980;54:77–83
9. Kugelberg E, Widen L. Epilepsia partialis continua. *Electroencephalogr Clin Neurophysiol* 1954;6:503–506
10. Cowan JMA, Rothwell JC, Wise RJS, et al. Electrophysiological and positron emission studies in a patient with cortical myoclonus, epilepsy partialis continua and motor epilepsy. *J Neurol Neurosurg Psychiatry* 1986;49:796–807
11. Wieser HG, Graf HP, Bernouilli C, et al. Quantitative analysis of intracerebral recordings in epilepsy partialis continua. *Electroencephalogr Clin Neurophysiol* 1978;44:14–22
12. Siegfried J, Bernouilli C. Stereoccephalographic exploration and epilepsy partialis continua. *Acta Neurochir (Wien)* 1976;23:183–191
13. Obeso JA, Rothwell JC, Marsden CD. The spectrum of cortical myoclonus. *Brain* 1985;108:193–224
14. Shibasaki H, Yamashita Y, Neshige R, et al. Pathogenesis of giant somatosensory evoked potentials in progressive myoclonus epilepsy. *Brain* 1985;109:225–240
15. Witte OW, Bruehl C, Schlaug G, et al. Dynamic changes of focal hypometabolism in relation to epileptic activity. *J Neurol Sci* 1994;124:188–197
16. Hefter H, Witte OW, Reiners K, et al. High frequency bursting during rapid finger movements in an unusual case of epilepsy partialis continua. *Electromyogr Clin Neurophysiol* 1994;34:95–103
17. Ochs RF, Gloor P, Tyler J, et al. Positron emission tomography measurements of glucose metabolism in epilepsy partialis. *Neurology* 1985;35:227
18. Ginsberg MD, Castella Y, Dietrich WD, et al. Acute thrombotic infarction suppresses metabolic activation of ipsilateral somatosensory cortex: evidence for functional diaschisis. *J Cereb Blood Flow Metab* 1989;9:329–341
19. Ibanez V, Deiber MP, Sadato N, et al. Effects of stimulus rate on regional cerebral blood flow after median nerve stimulation. *Brain* 1995;118:1339–1351
20. Lüders HO. *Epilepsy surgery*. New York: Raven, 1991

Isolated Straight Sinus Thrombosis: Clinical and Neuroradiologic Correlates

James Valeriano, MD

Department of Neurology
MCP—Hahnemann School of Medicine
Allegheny General Hospital
Pittsburgh, PA

Kumar Bhagavatula, MD

Department of Neurology
MCP—Hahnemann School of Medicine
Allegheny General Hospital

Andrew Ku, MD

Department of Radiology
MCP—Hahnemann School of Medicine
Allegheny General Hospital

Peter J. Snyder, PhD

Department of Neurology
MCP—Hahnemann School of Medicine
Allegheny General Hospital

ABSTRACT

A rare case of straight sinus thrombosis in a 36-year-old female with sudden onset of status migrainosus is presented. This condition was demonstrated by a linear density in the midline on a noncontrast computed tomography scan, as a filling defect at the location of straight sinus on mag-