

6. Suzuki J, Takaku A. Nonsurgical treatment of chronic subdural hematoma. *J Neurosurg* 1970;33:548-553
7. Bender MB, Christoff N. Nonsurgical treatment of subdural hematoma. *Arch Neurol* 1974;31:73-79
8. Lee KS, Bae HG, Yun IG. Small-sized subdural hematoma: operate or not. *J Kor Med Sci* 1992;7:51-57
9. Croce MA, Dent DL, Menke PG, et al. Acute subdural hematoma: non-surgical management of selected patients. *J Trauma* 1994;36:820-826
10. Dent DL, Croce MA, Menke PG, et al. Prognostic factors after acute subdural hematoma. *J Trauma* 1995;39:36-42

69-year-old woman who underwent resection of the left cerebellar hemisphere for an acoustic neurinoma 17 years earlier. Functional impairment in cerebral cortical and subcortical structures was evaluated by studying the level of glucose metabolic activity at rest. Relative glucose metabolism was reduced in the prefrontal cortex contralateral to the cerebellar lesion. Contralateral thalamic metabolism was reduced significantly. The results suggest that this phenomenon of "crossed cerebello-thalamo-cerebral diaschisis" is related to a functional depression of the cerebello-thalamo-cortical pathway.

Key words: PET, Pet-FDG, cerebello-thalamo-cerebral diaschisis.

Tecco JM, Wuilmart P, Lasseaux L, Wikler D, Damhaut P, Goldman S, Gilles C. Cerebello-thalamo-cerebral diaschisis: A case report. *J Neuroimag* 1998;8:115-116

Cerebello-thalamo-cerebral Diaschisis: A Case Report

Juan M. Tecco, MD

Service de Psychogériatrie
Hôpital Ambroise Paré
Mons, Belgium

Philippe Wuilmart, MD

Service de Psychogériatrie
Hôpital Ambroise Paré

Laurence Lasseaux, BS

Service de Psychogériatrie
Hôpital Ambroise Paré

David Wikler, Ir

PET/Biomedical Cyclotron Unit
ULB-Hôpital Erasme
Brussels, Belgium

Philippe Damhaut, PhD

PET/Biomedical Cyclotron Unit
ULB-Hôpital Erasme

Serge Goldman, MD

PET/Biomedical Cyclotron Unit
ULB-Hôpital Erasme

Christian Gilles, MD

Service de Psychogériatrie
Hôpital Ambroise Paré

ABSTRACT

This reports positron emission tomography and [¹⁸F]fluorodeoxyglucose (PET-FDG) in a

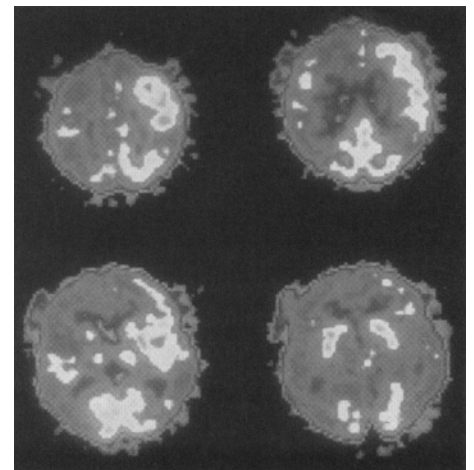
Positron emission tomography (PET) may help to understand functional aspects of anatomic circuitry in human pathologic conditions. The main cerebellar output participates in a functional cerebello-thalamo-cortical pathway.¹ The lateral part of the cerebellar cortex sends its output to the dentate nucleus. By crossing pathways in the superior cerebellar peduncle, efferent fibers from the dentate nucleus reach contralateral ventrolateral thalamic nucleus, which projects to the cerebral cortex. The existence of a "crossed cerebello-cerebral diaschisis"² has been demonstrated in several reports on single photon-emission computed tomography (SPECT) and PET studies.²⁻⁷ This diaschisis consists of a decreased cerebral metabolism and blood flow in the frontal cortex contralateral to a lesioned cerebellar hemisphere. Functional depression of the cerebello-ponto-thalamo-cerebral pathway is the most probable cause for crossed cerebello-cerebral diaschisis.² Nevertheless, metabolic changes in the thalamus, a major component of this circuitry, has not been described previously, perhaps because of the difficult appreciation of the thalamic activity with the SPECT and low-resolution PET systems.⁸ This reports a PET study in a woman, 17 years after a large resection of the left cerebellar hemisphere to determine if, in a situation of cortical diaschisis

following chronic cerebellar damage, thalamic contralateral metabolic changes could be recorded by PET.

Case Report

A 69-year-old woman suffered onset history of schizophrenia at age 23. Since then, she was treated by neuroleptics. At age 51, she underwent surgery for an acoustic neurinoma and kept left deafness and facial palsy as sequelae. Apart from these cranial nerves deficits, examination at age 69 revealed major cognitive deterioration and bilateral extrapyramidal manifestations. Post-surgical absence of the left cerebellar lobe and the inferior left cerebellar peduncle was noted by brain computed tomography and magnetic resonance imaging.

Positron emission tomography with [¹⁸F]-fluoro-2-deoxy-D-glucose (FDG) was obtained using a CTI-Siemens 933 camera (CTI, Knoxville, TN) with eight rings of detectors providing 15 slices in a 10.5-cm field of view. Transaxial images were reconstructed with a 0.5 Hanning filter. A transmission scan was obtained using a ring source filled with a ¹⁸F-fluoride to allow a measured correction of the images for attenuation. The patient was injected intravenously with 5 mCi of FDG, and 20-minute static images were



Positron emission tomography with [¹⁸F]-fluorodeoxyglucose images parallel to the cantho-meatal line obtained at four levels from top (*left upper image*) to middle part of the brain (*right lower image*). Right frontal hypometabolism is visible on the two upper images and right thalamic and middle frontal hypometabolism is visible on the right lower image. Some degree of right parietal and temporal hypometabolism is also evidenced on these images. The right side of the brain is on the left side of the image.

Address correspondence to Dr Goldman, PET/Biomedical Cyclotron Unit, ULB-Hôpital Erasme, 808, route de Lennik, B-1070 Brussels, Belgium.

Received Apr 14, 1997, and in revised form Jul 25, 1997. Accepted for publication Sep 10, 1997.

acquired 40 minutes later. Positron emission tomography images were analysed visually. Absence of metabolic activity in the left cerebellum was noted. Metabolic activity was extremely asymmetric in the frontal lobe because of a relative reduction of activity in the right superior and middle frontal cortex (Fig). A lesser degree of cortical hypometabolism also was noted in the parietal and superior temporal areas of the right hemisphere. Metabolic activity in the fronto-parietal region of this hemisphere was the most preserved in the primary somatosensory area. Thalamic metabolism was asymmetric because of a reduction of activity on the right side. An index of asymmetry of the metabolic activity in the thalamus, using the total counts in the thalamus on two successive planes covering the entire structure, indicated a reduction by 21% of the values on the right side compared with the left.

Discussion

Contralateral cerebellar hypometabolism is found in patients with hemispheric supratentorial lesions.³ The mechanism is thought to be a functional deactivation caused by a loss of excitatory impulses through cerebrocerebellar pathways. The cerebellar cortex sends signals via ascending connections to the association areas of the cerebral cortex. In 1987, Broich et al introduced the concept of "crossed cerebello-cerebral diaschisis."² They presented the case of a 26-year-old male with a right cerebellar stroke and reduced metabolism in the left frontal cortex, suggesting that lesions in a cerebellar hemisphere could induce cerebral hypometabolism in the frontal cortex contralateral to the cerebellar lesion. Their observation was confirmed later by a small number of SPECT studies.³⁻⁷ Accordingly, we attributed the supratentorial metabolic disturbances in our patient to her cerebellar lesion. This patient was schizophrenic. Several studies have shown alterations in cortical and subcortical glucose metabolism in schizophrenia.¹¹⁻¹³ Nevertheless, metabolic alterations described in those reports are not consistent with a significant relative reduction in the metabolism of the right thalamus and the right frontal cortex. Therefore, the abnormalities observed in this patient are unlikely to be secondary to her psychiatric illness and most probably are related to her cerebellar lesion.

Functional depression of the cerebello-thalamo-cerebral pathway is the most probable cause of crossed cerebello-cerebral diaschisis.² Interestingly, reduction in cortical metabolism ipsilateral to a thalamic lesion also has been described.⁹ Therefore, "thalamo-cortical diaschisis" could be the direct cause of cortical hypometabolism when dysfunction of the cerebello-thalamo-cortical pathway is caused by a cerebellar lesion. A PET study by Tranchant et al of a 53-year-old woman with a right cavernous angioma of the cerebellum revealed left cerebral hypometabolism but failed to demonstrate hypometabolism of the thalamic nuclei contralateral to the cerebellar lesion.¹⁰ The authors raised the possibility of a retrograde transneuronal deactivation of the cerebro-ponto-cerebellar pathway instead of a cerebello-thalamo-cerebral deactivation in view of the absence of hypometabolism at the thalamic level. In contradiction with their findings, this PET study reveals not only frontal hypometabolism contralateral to a cerebellar lesion but also contralateral thalamic hypometabolism confirming the hypothesis of a cerebello-thalamo-cortical deactivation. The impact of the cerebellum on the cognitive functions has been emphasized recently¹⁴⁻¹⁶ and cerebello-cortical outputs via the thalamus seem to be implicated in these effects.¹⁷ Therefore, it appears reasonable to hypothesize that the hemispheric metabolic changes secondary to a cerebellar lesion may relate to this functional influence of the cerebellum on higher cortical functions. Such an hypothesis deserves investigation by activation studies with PET or functional magnetic resonance imaging in patients with cerebellar lesions.

References

1. Allen GI, Tsukara N. Cerebrocerebellar communication systems. *Physiol Rev* 1974;54:957-1006
2. Broich K, Hartmann A, Biersack HJ, Horn R. Crossed cerebello-cerebral diaschisis in a patient with cerebellar infarction. *Neurosci Lett* 1987;83:7-12
3. Baron JC, Boussier MG, Comar D, Castaigne P. Crossed cerebellar diaschisis;cf in human supratentorial brain infarction. *Trans Am Neurol Assoc* 1980;105:459-461
4. Attig E, Botez MI, Hublet C, Veronck K, Jacquy J, Capon A. Diaschisis cérébral croisé par lésion céré-

- ébelluse. *Rev Neurol Paris* 1991;147:3, 200-207
5. Botez MI, Leveille J, Lambert R, Botez TH. Single photon emission computed tomography (SPECT) in cerebellar disease: Cerebello-cerebral diaschisis. *Eur Neurol* 1991;31:405-412
6. Rousseaux M, Steinling M. Crossed hemispheric diaschisis in unilateral cerebellar lesions. *Stroke* 1992;23:511-514
7. Sönmezoglu K, Sperling B, Henriksen T, Tfelt-Hansen P, Lassen NA. Reduced contralateral hemispheric flow measured by SPECT in cerebellar lesions: crossed cerebral diaschisis. *Acta Neurol Scand* 1993;87:275-280
8. Andreasen N. Evaluation of brain imaging techniques in mental illness. *Ann Rev Med* 1988;39:335-45
9. Baron JC, Levasseur M, Mazoyer B, Legault-Demare F, Mauguier F, Pappata S, Jedynak P, Derome P, Cambier J, Tran-Dinh S, Cambon H. Thalamocortical diaschisis: positron emission tomography in humans. *J Neurol Neurosurg Psychiatry* 1992;55:935-942
10. Tranchant C, Maquet J, Eber AM, Dietemann JL, Franck P, Warter JM. Angiome caveux cérébelleux, dystonie cervicale et diaschisis cortical croisé. *Rev Neurol Paris* 1991;8-9:599-602
11. Wolkin A, Jeager J, Brodie J, Wolf A, Fowler J, Rotrosen J, Gomez-Mont F, Cancro R. Persistence of cerebral metabolic abnormalities in chronic schizophrenia as determined by positron emission tomography. *Am J Psychiatry* 1985;142:564-571
12. Biver F, Goldman S, De Maertelaer V, et al. Interregional correlation of cerebral glucose metabolism in unmedicated schizophrenia? *Eur Neuropsychopharmacol* 1996;6:141-147
13. Biver F, Goldman S, Delvenne V, et al. Altered frontostriatal relationship in unmedicated schizophrenic patients. *Psychiatry Res* 1995;61:161-171
14. Leiner HC, Leiner AL, Dow RS. Cognitive and language functions of the human cerebellum. *Trends Neurosci* 1993;16:444-447
15. Kim SG, Ugurbil K, Strick PL. Activation of a cerebellar output nucleus during cognitive processing. *Science* 1994;265:949-951.
16. Fiez JA. Cerebellar contributions to cognition. *Neuron* 1996;16:13-15.
17. Middleton FA, Strick PL. Anatomical evidence for cerebellar and basal ganglia involvement in higher cognitive function. *Science* 1994;266:458-461.