

Infectious diarrhea was originally suspected because of acute onset with fever and leukocytosis, the severity of the diarrhea, and the presence of sheets of polymorphonuclear leukocytes in stool. The difficulty in culturing *S. dysenteriae* from the stool was a major factor in our failure to establish a correct diagnosis. This is not uncommon since 20% of patients known to be infected with *Shigella* may not have microorganisms cultured from their stool.

The barium enema interpreted as ulcerative colitis added to confusion in diagnosis.<sup>17</sup> Had proctosigmoidoscopy been done initially, diagnostic dilemma would have been avoided, and a course of antimicrobial therapy might have reversed the pathologic process before colectomy became necessary.

*Shigella dysenteriae* type I. must be returned to the list of causes of pseudomembranous colitis.

#### REFERENCES

1. Formal SB, Gemski R, Gianella RA, et al: Mechanism of *Shigella* pathogenesis, *Am J Clin Nutr* **25**:1427, 1972.
2. Saphir O: A text on systemic pathology, New York 1959, Grune & Stratton, Inc, pp 950-952; 962-963.
3. Sleisenger M, and Fordtran J: Gastrointestinal disease, Philadelphia, 1973, WB Saunders Company, pp 1373-1377.
4. Silverman A, Roy CC, and Cozzetto FJ: Pediatric clinical gastroenterology, St. Louis, 1971, The CV Mosby Company, pp 140-141.
5. Boekus HL, et al: Gastroenterology, in Dearing WH, editor: Infectious diarrheas, Philadelphia, 1976, WB Saunders Company, pp 956-957.
6. Morson BC, and Dawson IMP: Gastrointestinal pathology, ed 2, Oxford, England, 1974, Blackwell Scientific Publications, p 259.
7. Reiner L, Schlesinger MJ, Miller GM: Pseudomembranous colitis following aureomycin and chloramphenicol, *Arch Pathol* **54**:39, 1972.
8. Pettet JD, Baggenstoss AH, Dearins HH, et al: Post-operative pseudomembranous enterocolitis, *Surg Gynecol Obstet* **98**:546, 1954.
9. Scott AJ, Nicholson GI, and Ken AR: Lincomycin as a cause of pseudomembranous colitis, *Lancet* **2**:1232, 1973.
10. Cohen IE, McNeill CJ, and Wells RF: Clindamycin associated colitis, *JAMA* **223**:1379, 1973.
11. Tedesco FJ, Barton RW, and Alpers DH: Clindamycin associated colitis, *Ann Intern Med* **81**:429, 1974.
12. Goulston SH, and McGovern VJ: Pseudomembranous colitis, *Gut* **6**:207, 1973.
13. Tedesco FJ, Stanley RJ, and Alpers DH: Diagnostic features of clindamycin associated pseudomembranous colitis, *N Engl J Med* **290**:841, 1974.
14. Reller B, Gangarosa EI, and Brachman PS: Shigellosis in the United States—five-years review of nationwide surveillance, 1964-1968, *Am J Epidemiol* **91**:161, 1970.
15. Levine VD, Overturf GD, and Mathies AW: *Shigella dysenteriae* type I—severe dysentery and sepsis with hematologic hepatic and renal complications, *West J Med* **121**:501, 1974.
16. Willis KC, and Rosenblatt RM: Shiga bacillus dysentery complicated by bacteremia and disseminated intravascular coagulation, *J PEDIATR* **83**:90, 1973.
17. Shimkin PM, and Link RJ: Pseudomembranous colitis: A consideration in the barium enema differential diagnosis of acute generalized ulceration colitis, *Br J Radiol* **46**:437, 1973.

## *The "locked-in" syndrome in children*

Gerald S. Golden, M.D.,\*

Norman Leeds, M.D., Bronx, N. Y.,

Martin W. Kremenitzer, M.D., New York,

N. Y., and Barry S. Russman, M.D.,

Hartford, Conn.

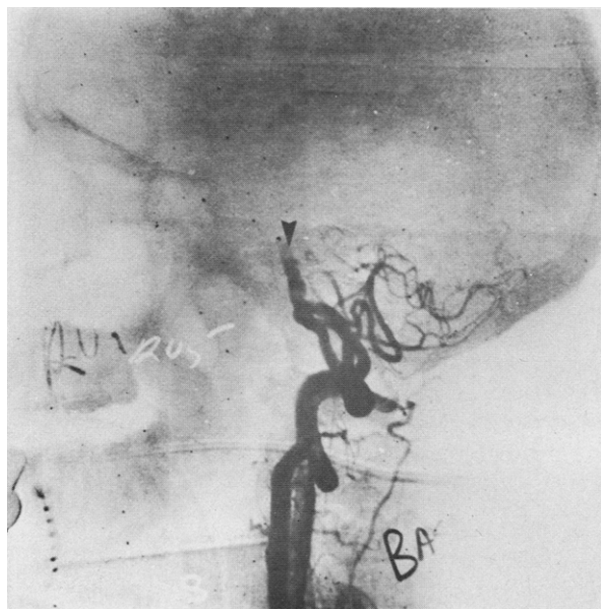
*From the Departments of Pediatrics and Neurology, Albert Einstein College of Medicine; Department of Radiology, Montefiore Hospital and Medical Center; Departments of Pediatrics and Neurology, New York Medical College; and Departments of Pediatrics and Neurology, University of Connecticut Medical School.*

\*Reprint address: 1410 Pelham Parkway South, Bronx, N. Y. 10461.

THE TERM "LOCKED-IN" SYNDROME refers to the condition of total motor paralysis with preservation of mesencephalic-controlled vertical eye movements and an intact sensorium. This has been described as "alert wakefulness accompanied by mute tetraplegia."<sup>1</sup> As evidence for intact cerebral cortical function, the patient can be taught to communicate by means of a set of coded eye blinks. The syndrome differs from that of the akinetic mute. In the latter condition, the patient can move, although he rarely does, and despite a superficial appearance of alert wakefulness, communication cannot be established. No previous reports of this condition in children have been found.

#### CASE REPORTS

**Case 1.** This 13-year-old boy had cyanotic congenital heart disease consisting of tricuspid atresia, ventricular septal defect, and pulmonic stenosis. At age 10 years a Blalock-Taussig anastomosis had been performed.



**Fig. 1.** Basilar artery occlusion. The lateral projection following injection of contrast medium into the right vertebral artery demonstrates reflux into the left vertebral artery. A thrombosis of the basilar artery is demonstrated in its mid-segment (arrow) (Case 1).

On the day of admission he had sudden onset of dizziness followed by nausea, vomiting, and lethargy. Neurologic examination showed deep obtundation and bilateral decerebrate posturing. Pupils were small and reactive. Optic axes were conjugate, but there were no spontaneous ocular movements and no reaction to oculocephalic maneuvers. Ice water caloric testing showed a bilateral internuclear ophthalmoplegia only on the first day.

Electroencephalogram had depressed, disorganized activity, but with organized sleep spindles and vertex sharp waves. Cerebral angiography demonstrated occlusion of the midportion of the basilar artery (Fig. 1).

Four days after admission he remained quadriplegic but appeared to be awake and alert. He could blink, elevate, and depress his eyes and could use a blink code to answer questions.

Over the following year and one-half his neurologic status remained virtually unchanged, except for some voluntary function of his left arm that permits use of a communication board and an electric typewriter.

**Case 2.** A 5 1/2-year-old boy with transposition of the great vessels had an atrial septotomy by balloon catheter at age nine days, and an anastomosis of the right pulmonary artery to the superior vena cava at age 10 months.

Because of increasing cyanosis and fatiguability, cardiac catheterization was carried out, and four hours later he became decerebrate with bilateral ptosis and fixed pupils. Extraocular movements could not be obtained, either with cold caloric testing or oculocephalic maneuvers.

Some recovery occurred over the next three days, with partial

return of lateral eye movements and responsiveness of the right pupil to light. Two months later he remained aphonic, but could move his eyes laterally on command, and responded by smiling.

Four months later he began to vocalize and to make purposeful movements with his left arm. Two months later he had complete ptosis on the left and partial ptosis on the right. There was no convergence or vertical gaze. The right eye had some movement past midline. He had a bilateral intention tremor and a wide-based stance. Slow improvement has continued.

**Case 3.** A 13-year-old girl presented with headache, facial numbness, and unsteady gait. She had dysfunction of the left fifth, sixth, and seventh cranial nerves, bilateral pyramidal tract signs with right-sided preponderance, ataxia of the left hand, and an ataxic gait. An intramedullary brainstem tumor was identified by cerebral angiography.

She received a total dose of radiotherapy of 5,640 rad to the posterior fossa. She survived for 10 months with progression of her neurologic signs. For a period of several days she developed bilateral decerebrate posturing, was aphonic, and had facial diplegia and complete lateral gaze palsies. She was able to open and close her eyes and look up and down on command, however. Subsequently she again became comatose.

## DISCUSSION

The term "locked-in" syndrome has been applied to patients who can perform no voluntary movements other than vertical eye movements, but are able to communicate utilizing the latter. The underlying pathology in the majority of anatomically documented cases is nearly complete infarction of the basis pontis, owing to occlusion of the basilar artery.<sup>2</sup>

Destruction of this region of the brainstem interrupts both corticospinal tracts producing quadriplegia, often with decerebrate posturing. Vertical eye movements are lost as a result of involvement of the sixth nerve nuclei, paraabducens region, and medial longitudinal fasciculus. Lack of involvement of the mesencephalon permits preservation of convergence and eye movements in the vertical plane. To maintain consciousness the bulk of the rostral pontine tegmentum must be spared.

Since severe vascular damage in the distribution of the posterior circulation generally leads to fatal illness, the manifestations may be difficult to elicit and only be present transiently during the patient's rapid decline. A few long-term survivors have been reported.

Electroencephalography has shown, in most cases, alpha and theta rhythms which were reactive to external stimuli.<sup>3</sup> This is characteristic of conscious patients and differs from the unresponsive fixed alpha frequencies sometimes seen in coma; it may be useful in confirming the diagnosis.

Patient 1 clearly met all of the clinical criteria of this syndrome, and the site of the lesion was confirmed

angiographically. This has not been previously reported in children, probably owing to the rarity of posterior circulation occlusive vascular disease in children.<sup>4</sup> Children with cyanotic congenital heart disease are predisposed to vascular accidents and basilar occlusion,<sup>5</sup> but not to the "locked-in" syndrome. The Blalock-Taussig procedure can be associated with basilar insufficiency, but rarely occlusion.<sup>6</sup>

Although the second patient was mute and tetraparetic but awake, alert, and responsive, he rapidly regained some horizontal eye movements, while maintaining bilateral ptosis and inability to carry out vertical movements. This implies involvement of mesencephalic structures as well as of the pons. A patient with bilateral midbrain infarcts as a cause of the "locked-in" state has been previously reported.<sup>7</sup>

The third child is unusual, since only one previous case of this syndrome in a patient with a brainstem tumor has been reported.<sup>8</sup> This was an adult who had a reticulum cell sarcoma involving the thalamus, mesencephalon, and pons.

Although rare in its occurrence, it is important that this condition not be overlooked. Any patient seemingly comatose should be tested for the presence of vertical eye

movements in response to verbal commands. The electroencephalogram may be a useful ancillary tool in diagnosis. Recognizing the "locked-in" syndrome is important for humane patient care, especially in the case of children in whom long-term survival is possible.

#### REFERENCES

1. Plum F, and Posner JB: The diagnosis of stupor and coma, Philadelphia, 1966, FA Davis Company, pp 92-93.
2. Nordgren RE, Markesberry WR, Fukada K, and Reeves AG: Seven cases of cerebromedullospinal disconnection: The "locked-in" syndrome, *Neurology* **21**:1140, 1971.
3. Hawkes CM, and Bryan-Smyth L: The electroencephalogram in the "locked-in" syndrome, *Neurology* **24**:1015, 1974.
4. Harwood-Nash DC, McDonald P, and Argent W: Cerebral arterial disease in children, *Am J Roentgenol* **111**:672, 1971.
5. Cottrill CM: Cerebral vascular accidents in cyanotic congenital heart disease, *Am J Dis Child* **125**:484, 1973.
6. Clarkson PM, Gomez MR, Wallace RB, and Weidman WM: Central nervous system complications following Blalock-Taussig operation, *Pediatrics* **39**:18, 1967.
7. Karp JS, and Hurtig MI: "Locked-in" state with bilateral midbrain infarcts, *Arch Neurol* **30**:176, 1974.
8. Cherington M, Stears J, and Hodges J: Locked-in syndrome caused by a tumor, *Neurology* **26**:180, 1976.

## *Normal leukocyte glutathione peroxidase activity in patients with chronic granulomatous disease*

Lawrence R. DeChatelet, Pamela S. Shirley,  
and Linda C. McPhail, *Winston-Salem, N. C.*

CHRONIC GRANULOMATOUS DISEASE of childhood is a syndrome characterized by an inability of the patient's leukocytes to kill many types of bacteria.<sup>1</sup> This is associated with defective oxidative metabolism which usually accompanies the phagocytic event. Leukocytes from affected patients do not exhibit increases in oxygen

consumption, hexose monophosphate shunt activity, nitroblue tetrazolium dye reduction, and hydrogen peroxide and superoxide anion production.<sup>2</sup> At least two forms of the disease exist; the classic disease is described in male children and appears to be inherited in an X-linked pattern.<sup>3</sup> A similar syndrome has been described in females and in some males in which cases there are no demonstrable heterozygotes in the families; the inheritance of CGD in these cases may be autosomal recessive.<sup>4</sup>

Abbreviation used CGD: Chronic granulomatous disease
---

*From the Department of Biochemistry, The Bowman Gray School of Medicine.*

*Supported by a grant from the Forsyth Cancer Service and by United States Public Health Service Grant A1-10732 from the National Institute of Allergy and Infectious Disease.*

The precise molecular defect is controversial in the X-linked disease,<sup>5</sup> but Holmes and associates<sup>6</sup> reported a deficiency in leukocyte glutathione peroxidase activity in two female patients with the disease. To the best of our knowledge, this observation has not been verified in the literature and so we initiated an investigation of leukocyte glutathione peroxidase activity in patients with CGD.

#### MATERIALS AND METHODS

The seven patients studied had a positive diagnosis of CGD as evidenced by metabolic studies (including oxygen