

Localization of Epileptic Auras Induced on Stimulation by Subdural Electrodes

*R. Schulz, †H. O. Lüders, *I. Tuxhorn, *A. Ebner, *H. Holthausen, *M. Hoppe, *‡S. Noachtar, §H. Pannek, ¶Th. May, and *P. Wolf

*Mara gGmbH, Epilepsiezentrum Bethel; §Gilead gGmbH, Neurochirurgische Klinik; and ¶Gesellschaft für Epilepsieforschung, Bielefeld, †Neurologische Klinik der Ludwig-Maximilians-Universität, Klinikum Großhadern, München, Germany; and ‡Cleveland Clinic Foundation, Cleveland, Ohio, U.S.A.

Summary: *Purpose:* This study evaluates the localization of stimulation-induced auras (SIA) and tries to determine whether the SIA can help to define the boundaries of resection in epilepsy surgery.

Methods: Using subdural grid electrodes, 31 patients with drug resistant focal epilepsy were examined in a retrospective and prospective study lasting 2 years.

Results: On stimulation by subdural electrodes, we elicited habitual auras in 16 patients (52%). The zone of SIA overlapped the epileptogenic lesion in 12 patients (75%), the EEG seizure onset zone in 12 patients (75%), and the irritative zone of interictal spikes in eight patients (50%). Postoperative results showed a significant correlation with the complete removal of the epileptogenic lesion ($p < 0.001$). Because the number of patients in the study was small, we could not find a significant correlation with the complete removal of the SIA zone, EEG seizure onset zone, and irritative zone.

Conclusions: Our study confirms previous analyses which indicate that complete resection of the epileptogenic lesion is essential to achieve a good outcome. Frequent overlap of the SIA zone with the epileptogenic lesion and the EEG seizure onset zone indicates proximity of the SIA with the epileptogenic zone. Nevertheless, this study does not support the concept that the SIA zone and the EEG seizure onset zone have additional value in defining the boundaries of resection in epilepsy surgery. Three case presentations suggest that SIA result from facilitated pathways between the stimulated cortex, the epileptogenic zone around the lesion, and the symptomatogenic zone. Functional reorganization in the vicinity of the cortical lesion cannot be ruled out but was not seen in our patients. Thus, SIA often do not reflect the normal function of the stimulated underlying cortex. **Key Words:** Epilepsy Surgery—Aura—Stimulation—Cortical function—Outcome.

Cushing (1), Foerster and Penfield (2,3), and Penfield and Jasper (4-7) were the first to report that they had elicited their patients' habitual auras on intraoperative stimulation. However, they used an intrasurgical stimulation method which made it difficult to study this phenomenon in detail because of limited time and difficulties in precise observation of seizure semiology and definition of stimulated anatomical structures. Because no attempts were made to document the occurrence of afterdischarges, they could not exclude the possibility that the symptomatology produced by cortical stimulation was due to propagation of epileptic discharges. Many of these disadvantages can be avoided when stimulating chronically implanted subdural grid electrodes. In this study, we tried to determine whether stimulation-induced

auras (SIA) could help us define the location of the epileptogenic zone which has to be resected to achieve seizure freedom. The epileptogenic zone is a theoretical concept. The irritative zone of interictal spikes, the EEG seizure onset zone, the epileptogenic lesion, the symptomatogenic zone (eliciting the initial clinical signs of a seizure) and the functional deficit zone (e.g. postictal paresis) are all areas that can be measured and give us an index of the approximate location and boundaries of the epileptogenic zone (8).

SUBJECTS AND METHODS

Thirty-one (31) patients were studied, using subdural grid electrodes, from January 1993 until January 1995. In 16 of 31 patients, SIA were elicited (7 patients were studied retrospectively and 9 patients prospectively). The ages of these 16 patients ranged from 8 to 40 years (mean 25.1 years). One of these patients reported a sensation of movement of the eye, the second a sensation of clonic

Accepted May 22, 1997

Address correspondence and reprint requests to Dr. H. O. Lüders at Cleveland Clinic Foundation, 9500 Euclid Ave., Cleveland, OH 44195, U.S.A.

TABLE 1. *Epilepsy syndromes, histology, aura description and subdural electrode position in 16 patients with invasive video, EEG monitoring, and cortical stimulation*

Patient #	Syndrome	Histology	Aura	Subdural Electrodes
KH66	FLE, right	Cortical dysplasia	Tingling left forearm	64: Left frontocentral, 10: left frontal anterior mesial
STM84	FLE, left	Glioneuronal hamartia	Tingling right foot	64: Left frontocentral lateral, 10: left frontalcentral mesial
RH78	FLE, left	Cortical dysplasia	Warmth, sweat, sensation in head and chest	68: Left frontocentral lateral, 16: left frontal mesial
AT61	POLE, left	Cortical dysplasia	Vertigo, abdominal uneasiness; "I can't see," but is able to read (mentally retarded patient)	64: Left centroparietotemporal lateral
ZA 74	TLE, right	Glioneuronal hamartoma (WHO 1)	Abdominal sensation; distorted voices; uneasy, abstract feeling	48: Right temporoparietal lateral, 20: right temporal basal
TE76	FLE, right	Cortical dysplasia	Sensation of eye jerks to the left (no objective change visible)	64: Left frontozentral lateral, 10: left frontal lateral, 10: Left frontal mesial
KC55	FLE, right	Cortical dysplasia	Dull feeling; "like in a desparate situation"	64: Left frontoparietal, lateral, 10: left frontal mesial
TN72	Perirolandic E., left	No surgery	Tingling paresthesiae: right upper arm→forearm→hand	64: Left frontoparietal lateral
HK54	TLE, left	Ganglioglioma (WHO 1)	Fear; environment seems threatening	24: Left temporal lateral, 20: left temporal basal
BM77	POLE, left	Oligoastrocytoma (WHO 2)	Indescribable sensation in the head; objects move in the right visual field	64: Left parietotemporal
GF55	POLE, left	Microulegyria (perinatal)	Previous aura: yellow sparks or lights, right visual field; present aura: blue sparks or lights, right visual field	24: Left occipital lateral, 20: left occipital mesial 10: Right occipital mesial
WR54	FLE, right	Spongy-microcystic; adjoining gliosis	Variable: warmth (sometimes tingling) in the head, left forearm, hand, calf, leg	36: Right frontal lateral, 20: right frontal and parietal mesial
BJ81	Foc. E., right	Cortical dysplasia	Left mouth cloni	64: Left frontoparietal lateral, 24: left frontal lateral, 2x20: left frontal lateral and basal, 10: left temoral basal
MA 64	FLE, right	Multiple neuronal heterotopia	Warmth, paresthesias left arm→body→right leg, fear doing something she does not want to	48: Right frontal lateral, 10: right frontal mesial
KS77	FLE, right	Microcystic, fibrillary astrocytoma (WHO 2)	Sensation in the throat: cannot speak, can move the tongue: Broca area + probably pharynx muscle	64: Right frontal, central, lateral
KB54	TLE, right	Cortical dysplasia	Funny feeling, tingling in the head	36: right temporal, central

TLE, temporal lobe epilepsy; FLE, frontal lobe epilepsy; POLE, parietooccipital lobe epilepsy.

jerks of the labial angle, and the third an inability to speak. No objective motor signs were seen in any of the 3 patients. Each of the 16 patients had a lesion in MRI. Table 1 shows the epilepsy syndromes, the sites of the lesions, the symptoms of the auras and the placement of the subdural grid electrodes in each of the 16 cases.

The results from studies with closely spaced scalp electrodes according to the 10–10 system, high resolution MRI, positron emission tomography (PET), neuropsychologic testing and intracarotid amobarbital testing, were used to define the placement of the subdural grids. Electrode arrays were placed subdurally to define more precisely the extent of the epileptogenic zone and to locate eloquent cortical areas in the immediate surroundings of the epileptogenic region. The arrays of subdural electrodes consisted of 3-mm stainless steel electrodes with a center-to-center interelectrode distance of 1 cm, which were embedded in 1 mm thick medical-grade Silastic. Thus, about 7 mm separated the borders of adjacent electrodes. The positions of the subdural electrodes

were documented with x-ray pictures of the skull in 2 planes, and in most cases with MRI as well. The positions of the electrode arrays were visually related to the brain structures shown in the preoperative high resolution MRI. The relationship of the subdural electrodes to the central sulcus and the sylvian fissure was verified by somatosensory evoked potentials (SEP) of the median nerve and by cortical stimulation of the primary motor and sensory strip.

Interictal spikes, slowing, and clinical and subclinical EEG seizure patterns, were documented during invasive EEG-video monitoring (9). The ictal EEG and the clinical semiology of seizures and auras were analyzed independently. The EEG was recorded with a high frequency filter of 70 Hz and a low frequency filter of 1 Hz. We defined the irritative zone as the location underlying those electrodes where $\geq 10\%$ of a sample 100 spikes had their greatest amplitude. The restriction to $\geq 10\%$ was set because the majority of interictal spikes are confined to a relatively circumscribed area, but a small per-

centage of spikes are widely distributed over noncontiguous cortex. Only spikes which clearly stood out from the background activity were counted. A burst of interictal spikes was counted as a single spike. The ictal EEG frequently showed rapid propagation. The EEG seizure onset zone was defined by those electrodes which showed (a), repetitive spikes, or (b), low amplitude fast beta activity before widespread propagation.

Cortical stimulation was carried out after completing video and EEG monitoring (9). Stimulation consisted of 5–10 s trains of 50 Hz alternating positive and negative square wave pulses lasting 0.3 ms delivered by a Grass S-12C stimulator. To find a “reference” electrode, stimulation was first performed between pairs of immediately adjacent electrodes. A “reference” electrode was defined as one which, on stimulating at 15 mA, produced no afterdischarges and no positive or negative symptoms, e.g., speech arrest or negative motor responses. The occurrence of negative motor responses was excluded by asking the patient to read aloud and to perform rapid alternating movements during a stimulation current of 15 mA. Theoretical consideration and practical evidence support the assumption that the effect of stimulation is limited to the area of the brain underlying the 2 electrodes that are stimulated (9). Once a reference electrode had been found, all other electrodes were tested, using the same indifferent reference and using progressively higher stimulus intensities, starting at 1 mA. The stimulus intensity was increased in steps of 0.5–1 mA up to a maximum of 15 mA until (a), afterdischarges occurred, (b), the patient experienced ipsilateral facial/scalp pain or contraction of head muscles, or (c), the patient experienced positive or negative symptoms (habitual auras, illusions, hallucinations, autonomic phenomena, speech disturbances, contralateral motor contractions, and paresthesiae). Only auras that occurred without afterdischarges and in which coincidental occurrence of an aura was unlikely were considered as SIA. Chance occurrence was considered unlikely when the same aura could be elicited repeatedly by stimulation of the same electrode (prospective study) or adjacent electrodes (retrospective study). The occurrence of afterdischarges was excluded by simultaneous recording of 18-channel paper EEG (Schwarzer-Picker, type ED24). Because of the limited number of channels, paper EEG was available only for the stimulation and for all adjoining electrodes.

At surgery, the general objective was lesionectomy plus the resection of the EEG seizure onset zone, avoiding, however, eloquent cortex. The irritative zone and the SIA zone were, generally, less considered (e.g., Figs. 1, 2, 4, and 5).

Follow-up was carried out after 6 months, and after 2 years postoperatively, in adults, and in addition, after 1 year in children and adolescents (up to 15 years of age). The mean follow-up was 15.7 months (5–30 months).

Controls included the history, an EEG and at least one postoperative MRI.

RESULTS

First, 3 illustrative patients are presented. Then, the locations of the SIAs in the whole patient group and their relationships to the epileptogenic zone, the EEG seizure onset zone, and the irritative zone, are discussed.

CASE PRESENTATIONS

Patient 1 (GF55)

A patient 38 years of age who had left-sided parieto-occipital lobe epilepsy from the age of 8 due to perinatal asphyxia, had seizures which consisted of elementary visual auras of the right visual field (yellow sparks or lights, present only in the patient's childhood) and tonic seizures with falling and frequent head injuries (at the time of the evaluation 2 to 3 times per day). Neurological findings showed a defect in the right lower visual field in addition to marked cerebellar ataxia. The MRI revealed gliosis of the left occipital lobe, a right-sided frontomedial contusion and cerebellar atrophy. The right-sided frontomedial contusion was caused by 1 of the patient's severe tonic seizures; it was not visible on previous CT scans after onset of the epilepsy. Positron Emission Tomography (PET) showed a 30% decrease in glucose metabolism of the left occipital lobe. Interictal single photon emission computed tomography (SPECT) also showed a clear reduction of perfusion of the left occipital lobe. Noninvasive EEG was not of diagnostic value. Interictal EEG recording with subdural grid electrodes (Figs. 1 and 2) showed intermittent slowing and sharp waves at the lateral base of the left occipital lobe. The ictal EEG was difficult to localize, due to rapid spreading of the ictal discharge, but ictal EEG onset occurred twice as frequently on the left as on the right occipital lobe (4 times left occipital versus 2 times right occipital and 2 times nonlateralized). The patient had isolated auras, consisting of visual hallucinations of rapidly revolving glowing *blue* sparks or lights in the right visual field. Only auras of blue color were observed during this monitoring. They were of long duration (up to one min) and were accompanied by an EEG seizure pattern arising from the left lateral occipital lobe (electrode D5, Fig. 1). Stimulation of electrode D5 elicited the same blue hallucinations (Fig. 1). Furthermore, similar auras but consisting of bright yellow lights in the right visual field (identical to his habitual auras) occurred on stimulating electrodes placed on the left median occipital lobe (electrodes E2 and G1, Fig. 2). Two out of 17 electrodes overlying the epileptogenic lesion elicited SIA, and one electrode with SIA overlapped with the zone of the EEG seizure onset. There was, however, no overlap with the irritative zone.

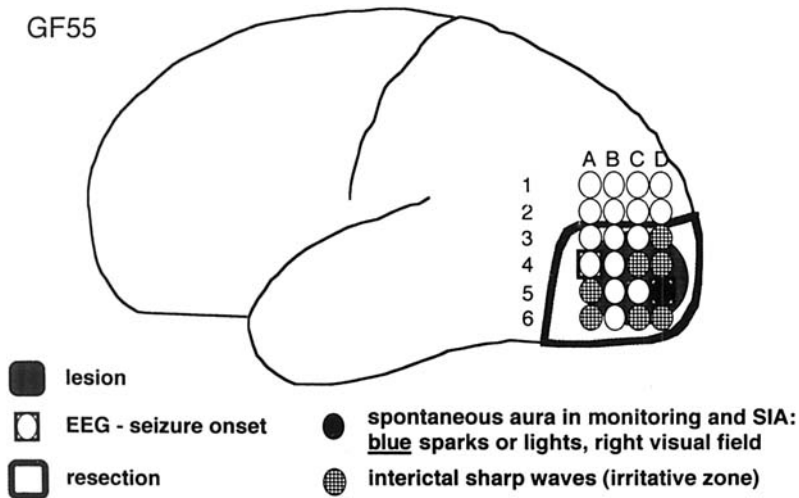


FIG. 1. Patient 1. Convexity of the left hemisphere.

According to intraoperative observation and postoperative MRI findings, a complete left occipital lobe resection was carried out (Fig. 1). Corticography after the resection showed no interictal spikes. Eight months after the operation, the seizure frequency had improved by >90%. The habitual auras, which had disappeared years before the surgery, did not reappear. Histologic examination of the resected occipital lobe showed a microulgyria, confirming that the seizures were secondary to a perinatal lesion.

The perinatal etiology of the seizures (frequently associated with seizures of biooccipital lobe origin) as also the recording of occasional seizures arising from the contralateral right occipital lobe placed the patient at a higher risk of recurrence of seizures following occipital lobectomy.

Patient 2 (TN72)

This 21-year-old woman had suffered from seizures since the age of 2, due to a left centroparietal cortical

dysplasia seen on MRI. She had tonic seizures, and at times had generalized tonic-clonic seizures (GICS) preceded by a somatosensory aura of tingling paresthesia of the right arm. Video and EEG monitoring with scalp electrodes showed interictal sharp waves in the left centroparietal area and an EEG seizure pattern which also originated from the left centroparietal region.

Video and EEG monitoring with subdural plate electrodes showed periodic interictal spikes and a localized EEG seizure pattern arising from electrodes placed near the epileptogenic lesion (Fig. 3). When the patient held both arms outstretched, an epileptic negative myoclonus of the right arm was revealed. SIA were elicited upon stimulation of the cortex by electrodes placed over the primary sensory cortex. Recording of median nerve SEP showed a phrase reversal across the center of the epileptogenic zone. SIA were induced by stimulation of 4 out of 8 electrodes overlying the epileptogenic lesion, by 5 out of 13 electrodes, which comprised the EEG seizure onset zone, and by all 4 electrodes located in the irritative

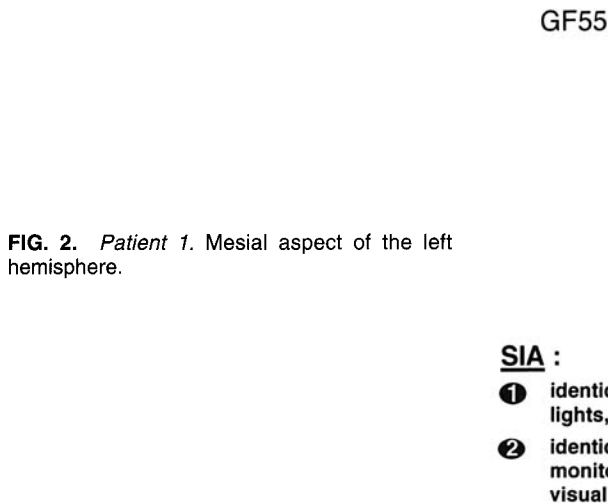


FIG. 2. Patient 1. Mesial aspect of the left hemisphere.

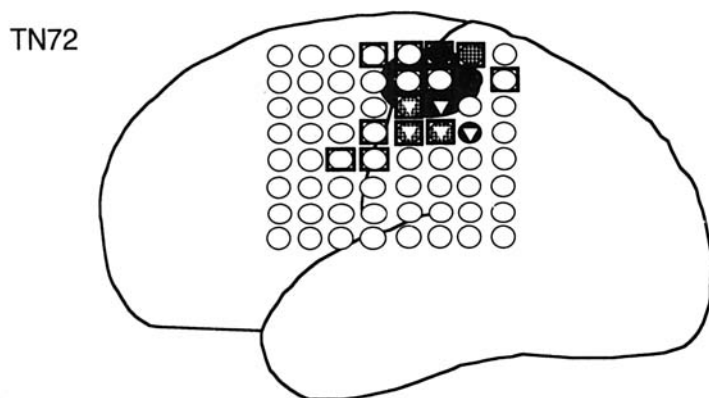


FIG. 3. Patient 2. Convexity of the left hemisphere.

SIA :

- tingling paresthesia right arm -> right forearm (march)
- ⊙ interictal sharp waves (irritative zone)
- ▼ -> right hand
- EEG seizure
- lesion

zone. The aura always began in the region of the right upper arm and shoulder and with stimulation of 3 electrodes, it then moved down towards the forearm, and with stimulation of 5 electrodes, it moved towards the hand.

The patient refused surgery because of the risk of right-hand paresis.

Patient 3 (WR54)

Since she was 12 years of age, this woman now 39 years of age, had had somatosensory auras of the left arm evolving to tonic and not infrequently secondary generalized clonic seizures. The neurological examination was normal. On MRI, a cystic lesion was seen in the right medial frontal lobe anterior to the lobulus paracentralis. Scalp electrodes localized the seizure origin to the region of the lesion.

Invasive recording with subdural grid electrodes showed repetitive interictal sharp waves mainly from electrodes placed over the epileptogenic lesion (Figs. 4 and 5). Two isolated auras and 6 auras which had evolved to a tonic seizure showed an EEG seizure pattern arising from electrodes placed over the region of the right frontal medial lesion. Upon stimulation, the patient experienced many different symptoms, which she identified as auras. In a patient history taken earlier, the patient said that her habitual auras most often involved the left arm and head, but seldom the left leg. These auras consisted predominantly of somatosensory symptoms, which were induced by stimulation of the convexity of the right frontal lobe. Stimulation that was more rostral and dorsal elicited somatosensory auras of the head, and symptoms of the left leg and arm were obtained more ventrally and caudally. No somatotopic grouping was

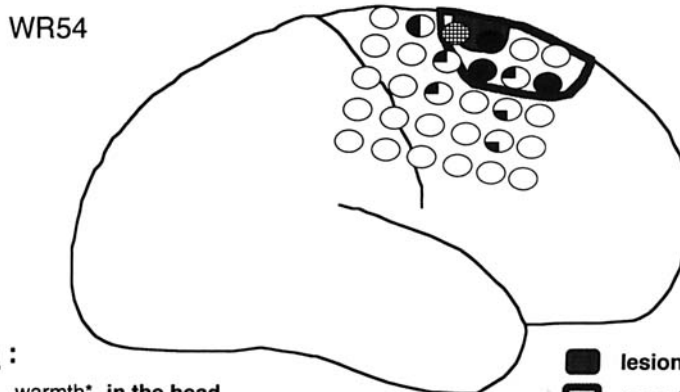


FIG. 4. Patient 3. Convexity of the right hemisphere.

SIA :

- warmth* in the head
- ◐ warmth* left forearm, wrist or hand
- ◑ warmth* left calf or left leg
- ◒ warmth* left calf and left hand
- lesion
- resection
- EEG seizure, mesial
- ⊙ interictal sharp waves (irritative zone)

* (usually warmth, but occasionally also tingling)

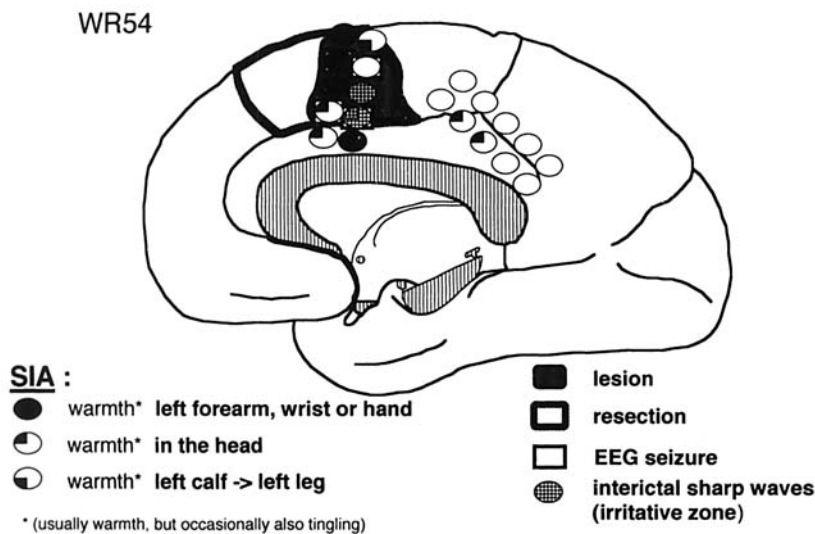


FIG. 5. Patient 3. Mesial aspect of the right hemisphere.

observed in the elicited auras of the frontal mesial region. SIA were induced on stimulating 20 electrodes: 8 out of 20 electrodes overlying the epileptogenic lesion, 4 out of 20 electrodes comprising the EEG seizure onset zone, and 2 out of 20 electrodes located in the irritative zone. Corticography after resection of the mesial lesion and adjoining parts of the right frontal lobe (Figs. 4 and 5), revealed no epileptiform discharges.

Seven months after surgery, the patient had only somatosensory auras of the left hand, whose frequency had decreased from once a week, after discharge from the hospital, to 1 in 3 weeks.

Group analysis

We found SIA in 16 out of 31 patients. On average SIA were induced at 4.8 electrodes per patient (range: 1–20 electrodes). The area with SIA was smaller than the lesion in some patients (in 4 patients, it consisted of only 1 electrode), and in other patients, the area with SIA was more extended (e.g., Figs. 4 and 5). The electrodes with SIA were contiguous in 4 patients but noncontiguous in 8 patients.

SIA were elicited when stimulating over or in the immediate proximity of the epileptogenic lesion or the EEG seizure onset zone: SIA occurred in 75% (12 out of 16 patients) on stimulation above the epileptogenic lesion (retrospectively in all 7, prospectively in 5 out of 9; in 3 patients SIA were elicited within 1 cm from the lesion, in one patient within 2 cm from the lesion. SIA occurred in 75% of the patients when the stimulating electrodes were within the EEG seizure onset zone (12 out of 16 patients, retrospectively in 5 out of 7, and prospectively in 7 out of 9). In 3 additional patients SIA were elicited when stimulating electrodes placed within 1 cm from the EEG seizure onset zone. In the other patient, the EEG seizure

onset was situated on the frontal mesial plate, whereas the SIA was located on the plate over the convexity.

There was less overlap of the irritative zone and the SIA zone. SIA occurred in 50% of the patients when stimulating electrodes located over the irritative zone (in 8 out of 16 patients, retrospectively in 6 out of 7, prospectively in 2 out of 9 patients). In 4 patients, SIA occurred 1 cm away. In 4 other patients, SIA occurred 2 cm away.

The degree of resection of the epileptogenic lesion, the EEG seizure onset zone, the irritative zone and the area which was defined by SIA was correlated to the postsurgical seizure outcome (Table 2). The degree of resection of the epileptogenic lesion was judged according to the postsurgical MRI findings and histologic studies. Seven patients had a total removal of the epileptogenic lesion. All were seizure free: auras persisted in 3 of the patients. Two out of 3 patients with a possibly incomplete resection were seizure-free (1 still had auras); the third had a decrease of seizure frequency of >95%. In 5 patients, the resection of the lesion was subtotal; 1 had a reduction of seizures of >90%; 2 showed rewarding improvement, either in the form of a clear decrease of the intensity of seizures or in the loss of especially disabling seizure types. There was no improvement in 2 patients. One of these 5 patients had suffered a perinatal lesion (GF55 = patient 1; EEG seizure onset was also contralateral), which was confirmed histologically. Multiple neuronal heterotopias were found in another patient, so that total removal of the epileptogenic lesion was impossible. One of the 16 patients had no surgery because of the risk of neurological deficits (TN72 = patient 2). These data show that the extent of the removal of the epileptogenic lesion (complete; possibly incomplete; incomplete) and the outcome (seizure-free, including patients with auras only; not seizure-free) were significantly related ($p =$

TABLE 2. Postsurgical outcome versus lesionectomy and resection of SIA zone, EEG seizure onset zone, and irritative zone (as ratio of corresponding electrodes) in 16 patients studied with invasive video and EEG monitoring and ensuing cortical stimulation

Patient	lesionectomy	Resection (ratio corresponding to electrodes)			Outcome
		SIA zone	EEG seizure onset zone	Irritative zone	
KH66	Total ?	3/3	8/15	2/5	> 95% reduction of seizures (running down of seizures)
STM84	Total	4/5	3/9	4/7	No seizures; running down of auras
RH78	Total	6/6	5/5	7/10	No auras; no seizures
AT61	Total ?	5/5	2/2	6/10	No seizures; auras questionable
ZA 74	Incomplete	6/6	2/2	3/4	No appreciable change
TE76	Total ?	2/2	19/19	14/15	No auras; no seizures
KC55	Total	1/1	1/1	5/6	No auras; no seizures
TN72	No surgery				
HK54	Total	7/7	14/14	9/9	Two auras; no seizures
BM77	Total	0/4	3/9	2/11	No auras; no seizures
GF55	Incomplete	2/4	5/7	11/11	No auras; > 90% reduction of seizures
WR54	Total	11/20	4/4	3/3	Running down of auras; no seizures
BJ81	Incomplete	2/2	5/5	2/2	No auras; worthwhile seizure reduction
MA 64	Incomplete	1/1	11/12	6/6	No appreciable change
KS77	Total	0/1	2/5	2/7	No auras; no seizures
KB54	Incomplete	0/1	0/2	0/6	No appreciable change

SIA, Stimulation-induced auras.

0.0006; 2-sided p-value, extension of Fisher's exact test for 2 × 3 contingency tables).

The degree of excision of the EEG seizure onset zone did not permit a prediction of the surgical outcome (Fisher's exact test, 1-sided $p > 0.2$). Out of 8 patients with complete resection of the EEG seizure onset zone, 6 were seizure-free (including 3 who still had auras); 2 had a rewarding improvement. In 7 patients, the EEG seizure onset zone could not be removed entirely. Three were seizure-free (out of whom one had auras); 2 had an improvement of >95 or 90%, 2 showed no improvement.

The degree of resection of the irritative zone also did not correlate with the postoperative result (Fisher's exact test, 1-sided $p > 0.2$). Of 10 patients in whom the irritative zone could only be partially removed, 7 were seizure-free (two still had auras), one had an improvement of seizure frequency of >95%, and one a rewarding improvement, but in 1 there was no improvement. Out of 5 patients, in whom the irritative zone was completely removed, 2 had auras only, 1 a reduction in the seizure frequency by >90%; 1 had a rewarding improvement, and in 1 there was no improvement.

Complete excision of the area defined by SIA did not predict a good surgical outcome (Fisher's exact test, 1-sided $p > 0.2$). Of 9 patients in whom this area was entirely removed, 5 were seizure-free, (2 still had auras). There was a reduction in seizure frequency of >95% in 1 patient. Two had a rewarding improvement, but 1 had no improvement. Of the 6 patients in whom this area was not removed, 4 were seizure-free (2 only had auras), 1 had a reduction in seizure frequency of >90%, and 1 patient had no improvement. The phenomenon of "running down of auras" occurred in 2 of the 6 patients in whom the removal of the SIA zone was incomplete. Pa-

tient WR54 had only somatosensory auras of her left hand immediately after surgery. Seven months after surgery, the frequency of these auras had dropped from 1 a week to one in 3 weeks. Patient STM84 stated that he had several somatosensory auras of the right foot within the first 3 weeks after discharge from the hospital. Only a single aura occurred between 6 months and 2 years following surgery.

Complete excision of the EEG seizure onset zone, SIA zone, or irritative zone in addition to complete removal of the epileptogenic lesion did not yield better results than the total removal of the epileptogenic lesion alone.

DISCUSSION

In this study, we have tried to define the pathophysiology of SIA, and tried to determine whether the cortical area which elicits SIA can be used as an index of epileptogenicity.

To define the pathophysiological significance of the SIA we will first discuss its topographic relationship to the other "zones." Our results show a considerable overlap of all zones. The area of the SIA overlapped the epileptogenic lesion as well as the EEG seizure onset zone in 75% of the patients. On the other hand, the overlap of the SIA to the irritative zone is less apparent. Only 50% of the SIA were within the irritative zone. There were no differences between the retrospective and prospective part our study.

Theoretically, there are 2 alternative explanations for the occurrence of SIA in the absence of afterdischarges: (a), a symptomatogenic zone is stimulated directly or (b), the stimulation activated an area outside the symptom-

atogenic zone which has facilitated pathways to a specific symptomatogenic zone. In the second case, the cortical area with the facilitated pathway could represent a part of the epileptogenic zone.

If the first hypothesis is correct, the SIA zone should have a location and size that is consistent with the expected location and size of the corresponding symptomatogenic area. In our material presented here neither of these 2 stipulations is fulfilled, because the SIA area was often too large and in most cases was located outside the expected functional map. If the second hypothesis is correct, we could expect a close correlation of the SIA area to the epileptogenic zone and the EEG seizure onset zone. All the data presented here support the second hypothesis. Functional reorganization as a consequence of the underlying cortical lesion may lead to a significant distortion of the normal cortical representation (10). Such a functional reorganization cannot be ruled out, but, in the patients of our study, this possibility is not supported by the otherwise normal cortical representation. On the other hand, the conclusion that there is a close proximity of SIA and the lesion remains the same, independent of the assumption that facilitated pathways indicate epileptogenicity or functional and structural reorganization within or close to the epileptogenic lesion.

This conclusion is well illustrated in patients TN72 and WR54. In patient TN72, the area of cortical somatosensory representation of the hand and lower and upper arm is larger than usual. Identical somatosensory symptoms in the right upper arm (Jackson march) were elicited by stimulation from 8 electrodes. This suggests the existence of a facilitated propagation to the representation of the right upper arm. In addition, a march of the aura from the upper arm into the right hand was observed on stimulation of the inferior 5 electrodes near the primary sensory area of the hand. This stereotyped march also supports the hypothesis of an epileptogenic, facilitated pathway. On the other hand, facilitated propagation was lacking in the primary motor cortex, because no auras could be induced anterior to the sulcus centralis, although the lesion covered parts of the primary motor cortex.

In patient WR54, the somatotopic grouping of the SIA from the lateral frontal lobe is opposite to the normal sensory homunculus. The extensive distribution of the SIA zone on the mesial frontal region also supports the hypothesis of the existence of epileptogenic, facilitated pathways.

We observed the phenomenon of "running down of auras" in 2 of 14 patients (STM84, WR54). It is possible that this phenomenon was related to incomplete removal of the epileptogenic zone. Hence the epileptic activity in the remaining part of the epileptogenic zone was still able to activate the symptomatogenic zone. "Healing" of the remaining epileptogenic tissue seemed to take

place during subsequent treatment with antiepileptic medication. "Running down of fits," according to Salanova et al. (11) occurred in most patients with frontal lobe epilepsy and has been described for essentially all anatomic and etiologic subgroups of patients, who were operated on the Montreal Neurological Institute during a period of >50 years. "Running down" of seizures was observed on an average of 18 months after surgery and occurred in 38.5% of the patients with nontumoral temporal lobe epilepsies (12,13). Changes at a cellular level in "running down of fits or auras" have not yet been explained.

The success of epilepsy surgery depends on the exact definition of the epileptogenic zone, which is the cortical area that must be resected to achieve seizure freedom. This study, which included only a relatively small number of patients, showed that the best results were obtained when the epileptogenic lesion was removed completely (Fisher's exact test, 2-sided $p < 0.001$). This finding corroborates previous studies (14–16). This study also suggests that the extent of the epileptogenic lesion apparently defines the epileptogenic zone better than the SIA zone and the EEG seizure onset zone. Removal of the irritative zone was least correlated with outcome in this study. Wyllie et al. found a significantly better clinical outcome after complete resection of the EEG seizure onset zone and of the irritative zone, but they did not consider the degree of removal of the epileptogenic lesion (17). Awad et al. showed a trend toward improved seizure outcome with complete focus resection in patients whose lesions could not be resected in total (16). Additional studies will be needed to establish the value of the EEG seizure onset zone and the SIA zone to achieve a more precise definition of the epileptogenic zone.

There is evidence to suggest that the removal of the epileptogenic lesion (lesionectomy) is sufficient to achieve complete seizure control in the majority of the patients who have tumors or cavernous hemangiomas (7). However, the lesion visible on MRI is only the "tip of the iceberg" in patients with cortical dysplasia, vascular, or traumatic lesions. In these cases, and also in cases in which the MRI shows no lesion, the definition of the epileptogenic zone usually depends on establishing with precision the location and boundaries of the EEG seizure onset and the irritative zone. The close correlation of the SIA zone with the EEG seizure onset zone, the irritative zone, and the epileptogenic lesion, suggests that the SIA zone may also play an important role in defining the epileptogenic zone in those cases in which the MRI shows no lesion or only a small part of the epileptogenic cortex. As a consequence, further studies should include a greater number of patients and particularly should address the etiology of the epileptogenic lesion.

Acknowledgment: We thank G. S. Macpherson, BSc, MA, PhD, for his valuable contribution in the translation of the manuscript.

REFERENCES

1. Cushing H. A note upon the faradic stimulation of the postcentral gyrus in conscious patients. *Brain* 1909;32:44–53.
2. Foerster O, Penfield W. Der Narbenzug am und im Gehirn bei traumatischer Epilepsie in seiner Bedeutung für das Zustandekommen der Anfälle und die therapeutische Bekämpfung derselben. *Z Ges Neurol* 1930;125:475–572.
3. Foerster O, Penfield W. The structural basis of traumatic epilepsy and results of radical operation. *Brain* 1930;53:99–119.
4. Penfield W, Jasper H. *Epilepsy and the functional anatomy of the human brain*. Boston: Little, Brown & Co., 1954:119–40.
5. Salanova V, Andermann F, Olivier A, Rasmussen T, Quesney LF. Occipital lobe epilepsy: electroclinical manifestations, electrocorticography, cortical stimulation and outcome in 42 patients treated between 1930 and 1991. *Brain* 1992;115:1655–80.
6. Salanova V, Andermann F, Rasmussen T, Olivier A, Quesney LF. Parietal lobe epilepsy: clinical manifestations and outcome in 82 patients treated surgically between 1929 and 1988. *Brain* 1995; 118:607–27.
7. Salanova V, Andermann F, Rasmussen T, Olivier A, Quesney LF. Tumoural parietal lobe epilepsy: clinical manifestations and outcome in 34 patients treated between 1934 and 1988. *Brain* 1995; 118:1289–304.
8. Lüders HO, Awad I. Conceptual considerations. In: Lüders HO, ed. *Epilepsy surgery*. New York: Raven Press, 1992:51–62.
9. Lüders H, Lesser RP, Dinner DS et al. Commentary: Chronic intracranial recording and stimulation with subdural electrodes. In: Engel J, ed. *Surgical treatment of the epilepsies*. New York: Raven Press, 1987:297–321.
10. Merzenich MM, Kaas JH, Wall JT, Sur M, Nelson RJ, Felleman DJ. Progression of change following median nerve section in the cortical representation of the hand in areas 3b and 1 in adult owl and squirrel monkeys. *Neuroscience* 1983;10:639–65.
11. Salanova V, Quesney LF, Rasmussen T, Andermann F, Olivier A. Reevaluation of surgical failures and the role of reoperation in 39 patients with frontal lobe epilepsy. *Epilepsia* 1994;35:70–80.
12. Rasmussen T. Surgical treatment of complex partial seizures: results, lessons, and problems. *Epilepsia* 1983;24(suppl. 1):S65–76.
13. Rasmussen T. Cortical resection for medically refractory focal epilepsy: Results, lessons, and questions. In: Rasmussen T, Marino R, eds. *Functional neurosurgery*. New York: Raven Press, 1979:253–69.
14. Palmini A, Andermann F, Olivier A, Tampieri D, Robitaille Y. Focal neuronal migration disorders and intractable partial epilepsy: results of surgical treatment. *Ann Neurol* 1991;30:750–7.
15. Palmini A, Gambardella A, Andermann F et al. Operative strategies for patients with cortical dysplastic lesions and intractable epilepsy. *Epilepsia* 1994;35(suppl. 6):S57–71.
16. Awad IA, Rosenfeld J, Ahl J, Hahn JF, Lüders H. Intractable epilepsy and structural lesions of the brain: Mapping, resection strategies, and seizure outcome. *Epilepsia* 1991;32:179–86.
17. Wyllie E, Lüders H, Morris HH III, et al. Clinical outcome after complete or partial cortical resection for intractable epilepsy. *Neurology* 1987;37:1634–41.