

Clinical paper

# The value of transcranial duplex sonography in the management of patients subsequent to surgery for middle cerebral artery aneurysms

Kay Mursch \*, Thorsten Enk, Evangelos Markakis

*Department of Neurosurgery, Georg-August-University Göttingen, Robert-Koch-Straße 40, D-37075 Göttingen, Germany*

Received 18 May 1997; received in revised form 9 September 1997; accepted 15 September 1997

---

## Abstract

*Objective:* We intended to evaluate the value of transcranial color-coded duplex sonography (TCCS) in the management of patients after clipping of an aneurysm of the middle cerebral artery. Question was whether this method was able to predict poor clinical outcome by detection of local circulation disorders in the postoperative course. *Methods:* A series of 15 consecutive patients was examined daily by TCCS. Special attention was paid to the branches of the middle cerebral artery distal from the clip (M2 branches). We correlated the TCCS results to the clinical outcome and occurrence of infarction on CCT. *Results:* In six patients, one or more M2 branches could not be found in the immediate postoperative course, but reappeared after a period of 1–12 days in five patients. The three patients with a missing signal for more than 4 days suffered from infarction of the dependent territory and permanent neurological deficit not due to vasospasm of the middle cerebral artery. In the nine patients with constant TCCS signals, there was only one infarction due to pre-hospital systemical hypotension. *Conclusion:* TCCS cannot give exact postoperative information about incidental vessel occlusion during surgery for MCA aneurysms because M2 branches can remain invisible for some days without being occluded, but this invisibility seems to be coupled with ischemic complications. © 1997 Elsevier Science Ireland Ltd. All rights reserved.

*Keywords:* Aneurysm surgery; Duplex scanning; Hemodynamics; Middle cerebral artery; Ultrasonics

---

## 1. Introduction

The presence of postoperative blood flow within vessels distal to a clipped aneurysm is

\* Corresponding author. Tel.: +49 551 396032; fax: +49 551 398794; e-mail: juliaetkay@aol.com

Table 1  
Patient demographics

Patient no.	Age (years)	Gender	Initial Hunt and Hess score	Day of operation	Side of aneurysm
1	19	M	1	2	Right
2	51	F	4	21	Right
3	52	M	4	1	Right
4	51	F	3	3	Left
5	65	M	3	2	Left
6	37	M	3	1	Left
7	38	M	5	1	Right
8	52	F	1	1	Right
9	52	M	3	24	Right
10	53	M	4	1	Right
11	46	F	4	1	Left
12	45	F	1	2	Left
13	32	M	1	2	Left
14	30	F	4	1	Left
15	33	F	4	1	Right

essential information for the correct postoperative management of the patient. Normally, the surgeon is able to provide a distinct description of the intraoperative situation, but it has been reported that incidental occlusion of vessels was not clearly apparent intraoperatively but was subsequently diagnosed by angiography (Macdonald et al., 1993). On the other hand, immediate postoperative angiography is not always available and may be hazardous to the patient (Perret and Nishioka, 1966) who may be suffering from intracranial hypertension or circulatory instability. Transcranial Doppler sonography (TCD) may be confusing in the postoperative course: reliable identification of the vessels is complicated by dislocation due to local swelling and other pathological conditions (Otis, 1993) in the early postoperative course.

Transcranial color-coded duplex sonography is a new diagnostic tool for intracranial angiology. The practical integration of transcranial Doppler technology with real-time imaging capabilities in the monitoring of patients suffering from subarachnoidal hemorrhage after rupture of cerebral aneurysms has been described (Becker et al., 1991). It provides measurements of blood flow velocities in the distal branches of the middle cerebral artery in nearly every patient, and it simplifies reidentification of the vessels in daily follow-up measurements.

In the following study, we analysed the clinical outcome, neuroradiological features, and TCCS findings in 15 patients after rupture and operative treatment of a middle cerebral artery aneurysm.

The objective of our study was to evaluate repetitive TCCS examinations for the postoperative treatment of such patients.

## 2. Materials and methods

During a 1-year period, 16 patients suffering from a subarachnoidal hemorrhage caused by rupture of an aneurysm of the middle cerebral artery bi- or trifurcation were admitted to our department: in 15, a clipping of the aneurysm was possible. One patient (initial Hunt and Hess (Hunt and Hess, 1968) score 5) died on the second day due to severe brain swelling prior to operation and was excluded from our series. The patient demographics are shown in Table 1.

A computerized sonography system (Computerized sonography system, Model SD 800, manufactured by Philips, Irvine, CA) with a 2.0-MHz transducer was used for all transcranial Duplex sonography measurements. The ultrasound probe was applied to the preauricular area of the temporal bone at the site of the ruptured aneurysm. Severe reduction of image quality due to postop-

erative scalp swelling had to be excluded by visibility of B-mode landmarks (e.g. third ventricle, brain stem, clip and sylvian fissure) which were also useful for vessel identification.

In every patient, the three-dimensional anatomy of the bi- or trifurcation of the middle cerebral artery was confirmed by analysis of the digital subtraction angiograms and by intraoperative aspects (normally, the TCCS examiners were present during the operation), and by TCCS. Color-coded imaging of the position of the vessels allowed clear daily follow-up of the vessels' flow velocity.

Transcranial duplex examinations of blood flow velocities and pulsatility indices in the M1-segment and in the M2-branches distal to the clip were performed daily in axial and coronal plain. Due to short visible course of the M2 branches, no angle corrections were performed. The absence of measurable blood flow or significant flow velocity reduction in a vessel had to be confirmed by both examiners (K.M., T.E.). Vasospasm was defined according to Newell (1990), as blood flow velocity in the MCA exceeding 120 cm/s (time mean of the envelope of the spectrum). The Pulsatility index (PI) according to Gosling and King (1974) was mentioned if it fell below 0.7 or rose over 1.5.

Cranial computed tomographies were performed at least on a weekly basis, normally every time neurological deterioration was observed during the regular neurological examinations. The minimal follow-up period was 2 months postoperatively.

For normal values, 60 volunteers, 35 men and 25 women, mean age 40.6 years, median age 35 years, were examined by TCCS from both sides. We examined the M1 stem and two M2 branches within 1 cm distal to the bifurcation. We distinguished an superior and an inferior branch. Due to the mainly short postbifurcational visible course, an angle correction was not performed.

### 3. Results

Normal mean values were 68.6 cm/s on the right M1 and 68.2 cm/s on the left side. The

superior branch on the right had 43.8 cm/s; the left 44.2 cm/s. The inferior branches of the M2 were 38.0 cm/s right and 38.8 cm/s on the left.

We present two illustrative cases:

#### 3.1. Case 1 (Patient 5)

The 65-year-old man was admitted because of a severe headache. On admission, his neurological state deteriorated and mechanical ventilation was necessary. Angiography revealed an aneurysm of the left middle cerebral artery bifurcation Fig. 1. TCCS showed normal flow velocities in the basal cerebral artery, but a slightly elevated velocity in the frontal M2 branch. An operation was performed on day 2. The course of the operation was uneventful and uncomplicated; both M2 branches were patent after clipping. Postoperatively, intracranial pressure rose, and CT revealed swelling of the left hemisphere Fig. 2. The left M2 branches were not visible on TCCS but reappeared after 4 and 7 days, respectively. The patient did not recover to more than a vegetative state. CCT revealed a complete infarction of the left MCA territory.

#### 3.2. Case 2 (Patient 9)

The 57-year-old man was admitted because of sudden severe headache. On admission, his neurological state deteriorated and mechanical ventilation was necessary. Due to hydrocephalus, a ventricular drain was placed. Angiography revealed an aneurysm of the left middle cerebral artery bifurcation. TCCS showed normal flow velocities in the basal cerebral arteries and in the M2 branches. Due to multiorgan failure, the patient could not be operated before day 24. Despite intraoperative aneurysm rupture, clipping was possible during temporary MCA occlusion for 6 min. Postoperatively, the M2 branches could not be detected but reappeared after 1 and 2 days. CT revealed a local swelling in the MCA territory which disappeared after 5 days and was not followed by infarction. The patient recovered without hemiparesis. Follow-up CT-scans were normal Figs. 3 and 4.

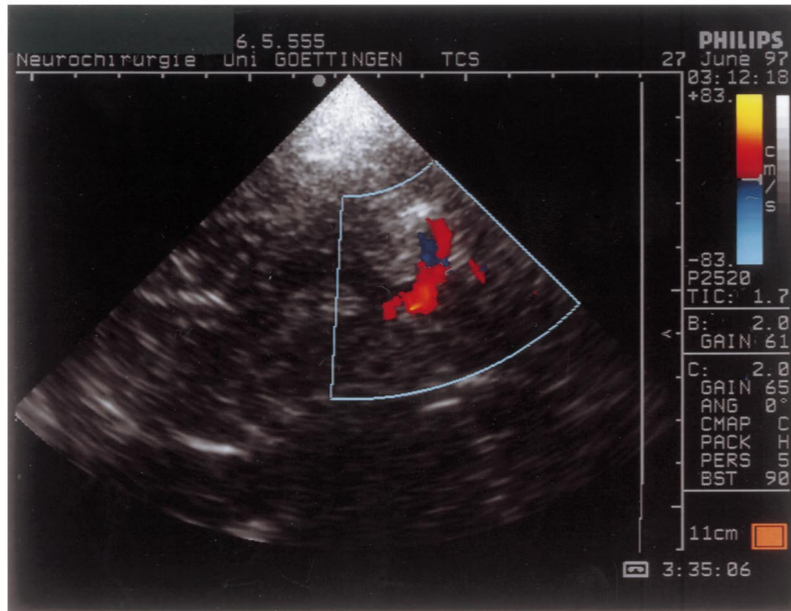


Fig. 1a

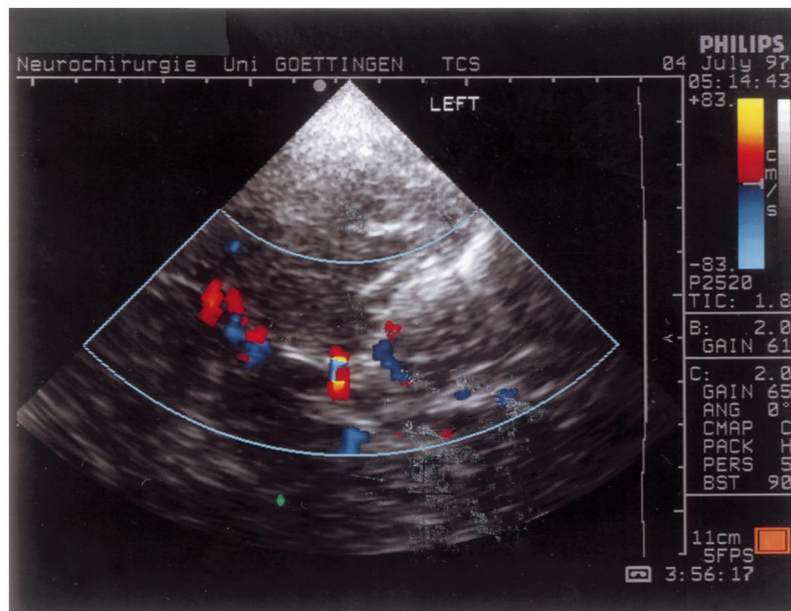


Fig. 2

Fig. 1. (a) Preoperative Duplex image of the three M2 branches (on the right part of the image, two red, one blue) distal to an MCA aneurysm. Axial plane tilted upwards, frontal on the left side. (b) Preoperative angiogram revealing three branches distal to the aneurysm. (c) Preoperative CT scan.

Fig. 2. Postoperative Duplex, M2 branches absent. Notice the collateral flow over the posterior cerebral artery (red and blue signals on the left side of the image). Blue signals on the right part: anterior cerebral artery. Red signal in the center: posterior cerebral artery.

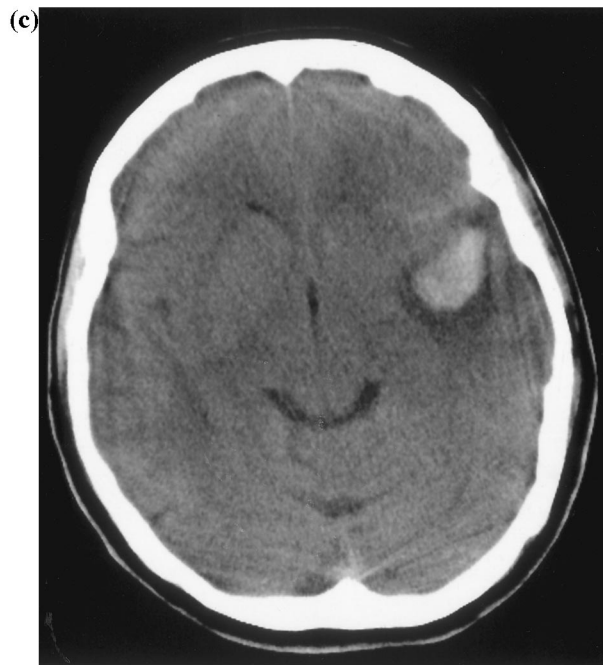
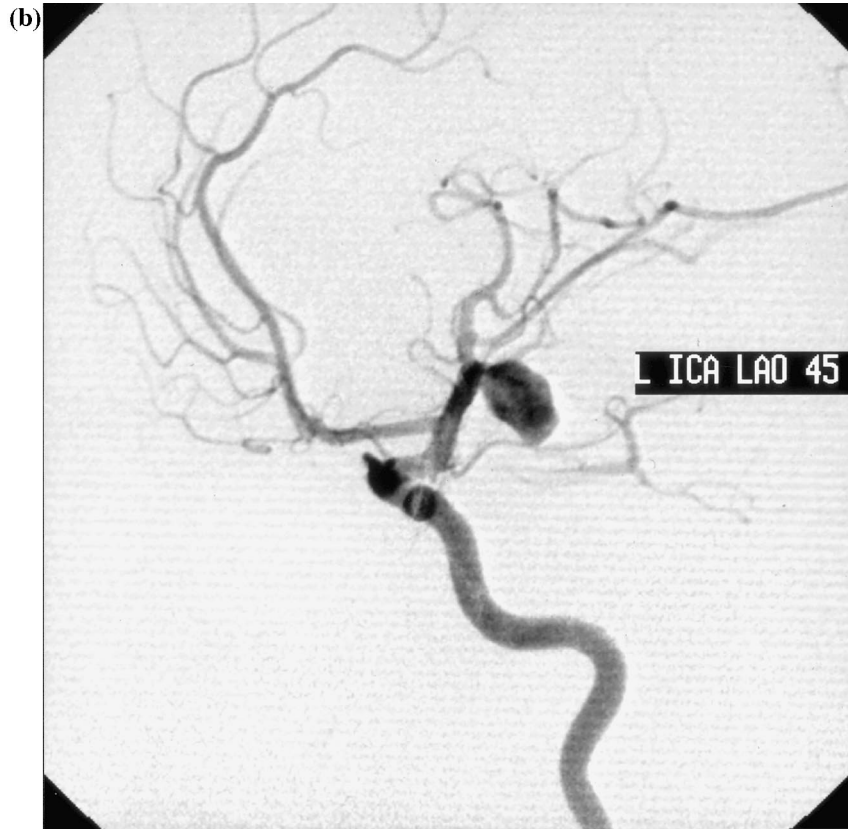
Fig. 1. (Continued)

Table 2  
Results of the TCCS examinations and the clinical and neuroradiological examinations

Patient no.	Loss of Doppler signal in M2 branches	Intracranial hematoma	Vasospasm in the M1 segment (cm/s)	Flow characteristics in M2 after reappearance	Severe focal neurological deficits	Localisation of infarctions on CT scan
1	No loss	No	Max. 192	—	None	No infarction
2	No loss	Yes	Max. 190	—	Tetraparesis	MCA (preoperatively)
3	No loss	Yes	No	—	Transient hemiparesis	No infarction
4	Postoperatively in both M2 branches, reappearance after 10 and 12 days	Yes	No	One with elevated flow velocities (>100 cm/s)	Aphasia/hemiparesis	MCA subterritory
5	Postoperatively in both M2 branches, reappearance after 4 and 7 days	Yes	No	Normal velocities	Severe hemiparesis	MCA infarction
6	No loss	Yes	max. 170	—	None	No infarction
7	Immediate operation without angio, intraoperative occlusion of the M2 branches, after day 7 no M1 signal	Yes	No	No reappearance	Severe hemiparesis	Complete MCA territory infarction
8	No loss	No	No	—	None	No infarction
9	Postoperatively in both M2 branches, reappearance after 1 and 2 days	No	Max. 124	Low PI, no high velocities	Transient hemiparesis	Immediately postoperative local swelling and hypodensity M2 subterritory, but no later infarction
10	No loss	Yes	> 200	Blood flow velocities over 150 cm/s	Persistent hemiparesis	No infarction, but defect after ICH
11	Very fast signal and turbulences near clip	Yes	Max. 121	Very slow post clip	Persistent aphasia, severe hemiparesis	No Infarction
12	Postoperatively in both M2 branches, reappearance after 1 and 2 days	No	Max. 136	Normal velocities	Transient hemiparesis	No infarction
13	No loss	—	No	—	None	No infarction
14	Postoperatively in two M2 branches, (3rd clipped) reappearance after 1 day	Yes	No	Normal velocities	Hemiparesis/aphasia	MCA territorial infarction
15	No loss	Yes	Max. 195	—	None	No infarction

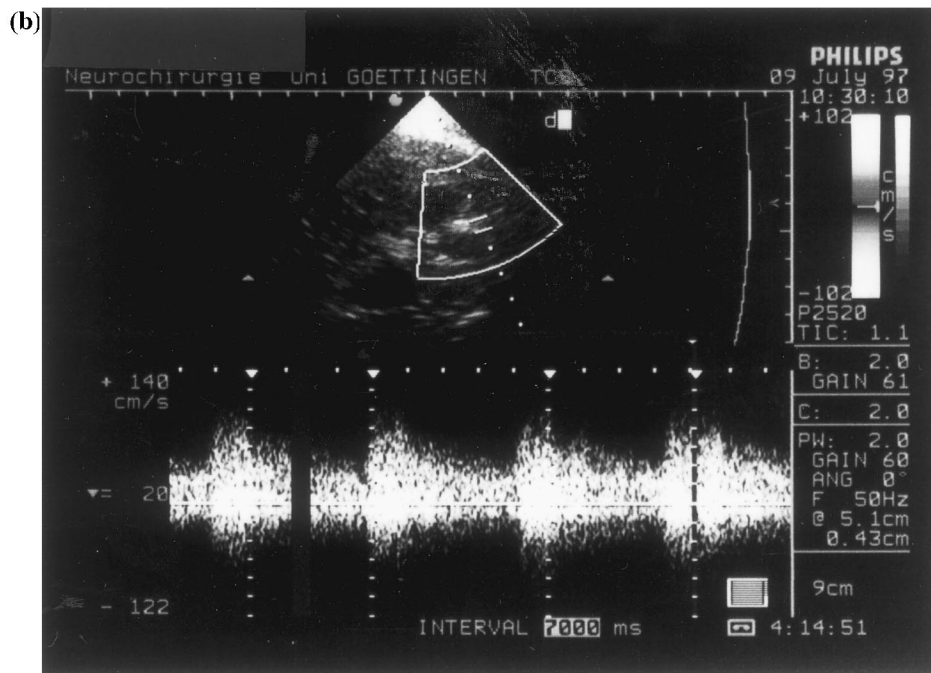
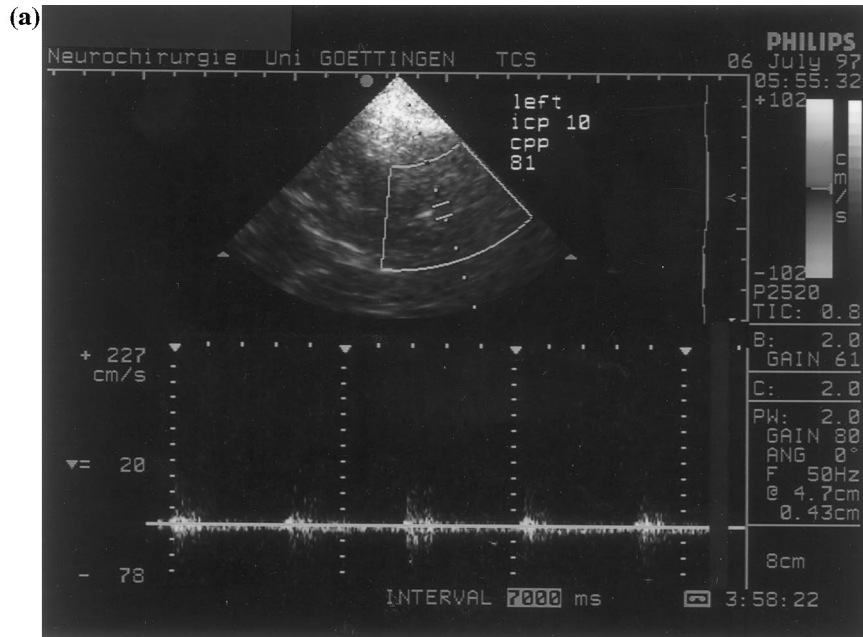


Fig. 3. (a) Reappearance of measurable flow after 9 days very slow Doppler spectrum. (b) Improvement of the Doppler spectrum on day 12.

The results for our 15 patients are listed in Table 2. In six patients, the number of visible vessels distal to the clip changed during the postoperative course. This was not due to abnormal postoperative scalp swelling compared to the other group. In five of them, the postoperative disappearance of the vessels was only transient and lasted from 1 to 12 days. The three patients with vessel reappearing after 1 or 2 days did not suffer from postoperative infarction or deficits; whereas the patients whose vessels reappeared later (or did not reappear) did suffer from those deficits. In the nine patients with normal TCCS findings or vasospasm, only one infarction occurred; it was linked to a breakdown of cerebral perfusion pressure caused by hypotension and hydrocephalus during resuscitation.

There was no typical blood flow pattern for stenosis or vasospasm in the vessels after reappearance.

In all 15 patients, the contralateral MCA and their branches remained visible during the whole course. With the exception of Patient 7, no abnormal flow spectrum in the proximal MCA could be

identified despite the elevated flow velocities mentioned in Table 2.

#### 4. Discussion

For the treatment of neurosurgical patients, the new TCCS technique seems to be promising. In instable patients, in whom unnecessary transports should be avoided, intracranial hematomas or hydrocephalus can be excluded at the bedside (Mursch et al., 1993). We also described the value of TCDS for intraoperative use in clipping of intracerebral aneurysms (Mursch et al., 1997). But until today, the value of this method for the postoperative hemodynamic monitoring of patients subsequent to clipping of intracranial aneurysms has not been clear. Our results in this well-defined population of patients after clipping of MCA bifurcational aneurysms seem to be discouraging in the sense that an occlusion of distal vessels cannot be distinguished from a transient missing duplex signal. In addition to that, the reason for the transiently missing signals is as yet unknown. Except for case 11, where a clip-induced stenosis was observed, the typical sign of intracranial vessel stenosis such as turbulence or murmurs (Ringelstein, 1996), were usually absent. Local vasospasm after operative manipulation may be one reason, but is not probable in those patients, in whom the flow velocities immediately after reappearance were slow or normal. Elevated local intracranial pressure lowering the local blood flow could explain the phenomenon in other cases. Local postoperative air may complicate the ultrasound examination as well as the low fine resolution (5 mm) of the colour mode and the orthograde course of the vessels in the ultrasound beam. We could not evaluate the potential additional value of 'Power Doppler' (Dymling et al., 1991) or ultrasound contrast agents (Bogdahn et al., 1993), because at the time of the study both techniques were not available to us; they are reported to be useful in difficult ultrasound examinations. In our department, early postoperative angiography is not performed routinely. Due to ethical reasons, this regimen was not changed to clarify the reason for the ultrasound problems. The potential benefit of early angiography after patho-

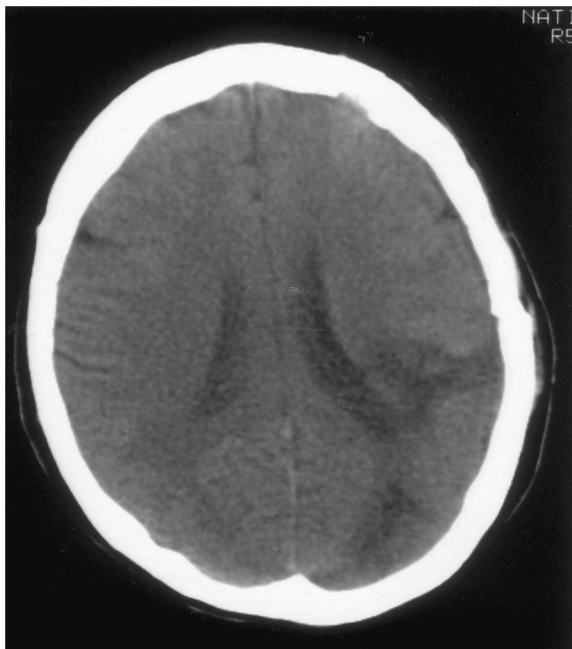

Fig. 4. Persistent hypodensity on CT scan, day 14.



logical postoperative ultrasound is not clear because of the time delay until craniotomy and replacing (if ever possible) of the clip.

On the other hand, our study shows that, unrelated to vasospasm of the parent vessel, the temporary absence of TCCS signals indicates the risk of postoperative neurological deficits and infarctions. In SAH, many different factors, such as elevated intracranial pressure and herniation, incidental perioperative occlusion of vessels (Macdonald et al., 1993), temporary vessel occlusion for operative reasons (Taylor et al., 1996) and vasospasm can cause impaired circulation. Thus, the mechanism of infarction is not always apparent. In contrast to the results of early authors (Aaslid et al., 1984; Sekhar et al., 1988), more recent studies have questioned the clinical value of TCD in predicting delayed neurological deficits caused by vasospasm (Laumer et al., 1993). This critical attitude towards TCD was confirmed by a recent paper, in which the authors reported little correlation between the cerebral blood flow measured by Xenon computed tomography and the elevated blood flow velocities measured by TCD (Clyde et al., 1996).

In this regard, our results show that TCCS may provide additional and valuable information in the treatment of the postoperative SAH patient by focusing the interest on the vessels distal to the clip. In conclusion, TCCS cannot give exact postoperative information about incidental vessel occlusion during surgery for MCA aneurysms because M2 branches can remain invisible for some days without being occluded.

### Acknowledgements

We thank Philips Medical Systems, Hamburg, for providing the sonography system.

### References

Aaslid R, Huber P, Nornes H. Evaluation of cerebrovascular spasm with transcranial Doppler ultrasound. *J Neurosurg*

1984;60:37–41.

Becker G, Greiner K, Kaune B, Winkler J, Brawanski A, Warmuth-Metz M, Bogdahn U. Diagnosis and monitoring of subarachnoid hemorrhage by transcranial color-coded real-time sonography. *Neurosurgery* 1991;28:814–20.

Bogdahn U, Becker G, Schlieff R, Reddig J, Hassel W. Contrast-enhanced transcranial color-coded real-time sonography. *Stroke* 1993;24:676–84.

Clyde BL, Resnick DK, Yonas H, Smith HA, Kaufmann AM. The relationship of blood flow velocity as measured by transcranial doppler ultrasonography to cerebral blood flow as determined by stable xenon computed tomographic studies after aneurysmal subarachnoidal hemorrhage. *Neurosurgery* 1996;38:896–905.

Dymling SO, Persson HW, Hertz CH. Measurement of blood perfusion in tissue using Doppler ultrasound. *Ultrasound Med Biol* 1991;17:433–44.

Gosling RG, King DH. Arterial assessment by Doppler-shift ultrasound. *Proc R Soc Med* 1974;67:447–9.

Hunt WE, Hess RM. Surgical risk as related to time of intervention in the repair of intracranial aneurysms. *J Neurosurg* 1968;28:14–9.

Laumer R, Steinmeier R, Gönner F, Vogtmann T, Priem R, Fahlbusch R. Cerebral hemodynamics in subarachnoidal hemorrhage evaluated by transcranial Doppler sonography. Part I. Reliability of flow velocities in clinical management. *Neurosurgery* 1993;33:1–9.

Macdonald RL, Wallace MC, Kestle JR. Role of angiography following aneurysm surgery. *J Neurosurg* 1993;79:826–32.

Mursch K, Vogelsang J, Kolenda H, Markakis E. Bedside neuroimaging of secondary posttraumatic complications by transcranial colour-coded real-time sonography (Abstract). *J Neurotrauma* 1993;10(1):190.

Mursch K, Schaake T, Markakis E. Using transcranial duplex sonography for monitoring vessel patency during surgery for intracranial aneurysms. *J Neuroimag* 1997;7:164–70.

Newell DW. Distribution of angiographic vasospasm after subarachnoid hemorrhage: implications for diagnosis by TCD. *Neurosurgery* 1990;27:574–7.

Otis SM. Pitfalls in transcranial Doppler diagnosis. In: Babikian VL, Wechsler LR, editors. *Transcranial Doppler Ultrasonography*. St. Louis: Mosby, 1993:39–50.

Perret G, Nishioka H. Report on the cooperative study of intracranial aneurysms and subarachnoid hemorrhage. *J Neurosurg* 1966;25:98–114.

Ringelstein EB. Cerebrovascular diseases. In: Tegeler CH, Babikian VL, Gomez CR, editors. *Neurosonology*. St. Louis: Mosby, 1996:173.

Sekhar LN, Wechsler LR, Yonas H. Value of transcranial Doppler examination in the diagnosis of cerebral vasospasm after subarachnoid hemorrhage. *Neurosurgery* 1988;22:813–21.

Taylor CL, Selman WR, Kiefer SP, Ratcheson RA. Temporary vessel occlusion during intracranial aneurysm repair. *Neurosurgery* 1996;39:893–906.