

G. Defazio
P. Livrea
P. Lamberti
R. De Salvia
G. Laddomada
M. Giorelli
E. Ferrari

Institute of Neurology of the University of
Bari, Italy

Isolated So-Called Apraxia of Eyelid Opening: Report of 10 Cases and a Review of the Literature

Key Words

Apraxia of eyelid opening
Extrapyramidal disorders
Botulinum toxin

Abstract

So-called apraxia of eyelid opening (scAEO) has been described chiefly in the context of extrapyramidal disorders. We described 10 new patients with scAEO developing in the absence of any other CNS sign and reviewed the 11 cases with isolated scAEO reported in the literature. Combining our patients and those from the literature, peak age at onset was in the 6th decade and there was a female preponderance of 2:1. The characteristic inability to initiate lid elevation was frequently associated with failure to sustain lid elevation, thus suggesting that eyelid motor control may be abnormal in isolated scAEO. Antecedent events included ocular signs and symptoms consistent with diseases of eyes or face (4 cases in our series and 2 in the literature), chronic treatment with flunarizine (1 case), and family history of dystonia (1 case). Flunarizine discontinuation led to sustained remission of the eyelid disturbance. Overall, these clues suggest the involvement of the extrapyramidal system in the pathophysiology of isolated scAEO. Familial clustering of isolated scAEO in one of our patients may be in favor of a genetic contribution. In our series, botulinum toxin administration close to the pretarsal part of the orbicularis oculi muscle significantly improved scAEO in 8/10 cases, whereas orbital/preseptal injection had no effect. We conclude that the term 'apraxia' may not be the correct descriptive term even when the eyelid disturbance occurs without any other CNS disease.

Introduction

So-called apraxia of eyelid opening (scAEO) was defined by Goldstein and Cogan [1] as a nonparalytic movement disorder characterized by transient difficulty in voluntarily initiating the act of lid elevation in spite of preserved alertness and language comprehension. Lepore

and Duvoisin [2] pointed out the clinical criteria for the diagnosis of scAEO, but questioned whether the condition should be categorized as apraxia since most patients were affected by extrapyramidal disorders [2–11] or, less frequently, cerebrovascular diseases [12–14]. Based on clinical and electromyographic (EMG) findings as well as on the results of botulinum toxin (BT) treatment, a vari-

ety of other terms have been proposed, including eyelid freezing [15], involuntary levator palpebrae superior (LPS) inhibition [2], blepharokolysis [16], focal eyelid dystonia [9] and pretarsal blepharospasm (BS) [8], but none achieved consensus.

In reviewing the literature, we found sporadic reports [3, 4, 8, 9, 17, 18], mostly consisting of anecdotal descriptions, on isolated scAEO, that is scAEO without extrapyramidal disorders or cerebrovascular diseases. Thus, the origin, nature and clinical features of isolated scAEO are uncertain, as well as the response to BT. To further investigate these issues, we present 10 new patients and a review of the cases described in the literature [3, 4, 8, 9, [7, 18].

Patients and Methods

scAEO was diagnosed according to Lepore and Duvoisin's [2] clinical criteria. These include: (1) no sign of ongoing orbicularis oculi (OO) contractions such as lowering of the brows beneath the superior orbital margins (Charcot's sign); (2) marked frontalis muscle overaction during period of inability to raise eyelids; (3) no ocular motor/ocular sympathetic nerve dysfunction or ocular myopathy. EMG examinations of the OO and LPS muscles were not performed since they are unwieldy, require expertise not readily available in our setting and, finally, seem unnecessary for the diagnosis of scAEO [19].

In reviewing the medical records of patients with excessive eyelid closure seen at our movement disorders clinic from 1987 to 1996 we found 30 patients with scAEO. In the same period, 120 patients were followed for typical BS without discernible scAEO. According to the results of clinical (neurologic and ophthalmologic), radiologic (computed tomography, CT, and/or magnetic resonance, MR, scan of the head) and laboratory (including serum ceruloplasmin estimation) investigations, patients without evidence of central nervous system (CNS) disease were considered to be affected by isolated scAEO.

At the time of the survey, the following information was collected: age, sex, age at disease onset (referring to the time of first symptoms), previous medical and surgical events including diabetes, hypertension, thyroid and ocular diseases, anxiety, depression, other diseases, general anesthesia, and head/face trauma. The occurrence of scAEO or other movement disorders in the first-degree relatives of index patients was assessed by directly examining living relatives; deceased relatives were considered to be affected only if at least another family member or, whenever possible, medical records or photographs provided adequate information to support diagnosis [19].

Patients were treated with BT (Allergan, Irvine, Calif.) according to two different protocols. First, 20–30 U were injected in the upper lid in two puncture sites at the junction of the orbital and preseptal OO, medially and laterally to avoid the LPS. Alternatively, BT (10–20 U/0.1 ml saline) was injected s.c. (one puncture site) in the mid upper lid close to the eyelash line [10]. To evaluate treatment outcome, we focused on a disability scale originally proposed by Fahn [20] for assessing the impact of BS on activities of daily living including driving a vehicle, reading, watching movies or television, going

shopping, walking in crowds and working at home or outside. We feel that this scale can be applied to any lid dyskinesia inducing eye closure. Results are expressed as percent of normal activity whereby 0 and 100% are assigned to subjects completely unable to perform functional activities of daily living or unaware of any difficulty respectively. According to the interpretation of the scale proposed by Lindeboom et al. [21], patients were classified as: functionally blind (0–20% normal activity); severely limited (21–33% normal activity); with moderate to marked limitation (34–57% normal activity); with minor functional limitation (58–75% normal activity); socially affected (76–90% normal activity). The validity of the disability scale has been assessed [21].

A computer-assisted review of the literature was conducted by Medline. To identify all possible cases of scAEO, the following key words were used: apraxia of eyelid opening [1], eyelid freezing [15], involuntary LPS inhibition [2], blepharokolysis [16], focal eyelid dystonia [9] and pretarsal BS [8]. To obtain additional reports we reviewed the bibliographies of all papers thereby identified. scAEO was considered to be isolated when no other CNS disease was reported.

Results

At the time of the first visit, scAEO was observed in the following clinical settings: (a) isolated in otherwise healthy individuals ($n = 12$); (b) adult-onset dystonia ($n = 11$), including BS ($n = 9$), BS plus oromandibular dystonia ($n = 1$) and writer's cramp ($n = 1$); and (c) parkinsonism ($n = 7$), including Parkinson's disease ($n = 3$), progressive supranuclear palsy ($n = 3$) and freezing ($n = 1$). Parkinsonism, cranial dystonia and writer's cramp preceded scAEO, whereas the symptom of onset was not known in 9 patients in whom coexistence of BS and scAEO was diagnosed 0.5–2 years (mean 1.4, SD 0.6) after the onset of eyelid discomfort.

Two out of the 12 patients presenting with isolated scAEO developed BS within 1.5 years. Thus, at the time of survey, 10 patients suffered from isolated scAEO. There were 4 males and 6 females aged 57–76 (mean 63.2, SD 5 years). Age at symptom onset ranged between 50 and 73 years (mean 58.7, SD 5.6), and mean disease duration was 5.2 years (SD, 2.9; range 3–12 years). The onset was bilateral in all patients. Detailed neurologic and ophthalmologic examinations as well as CT and/or MR scan of the head did not reveal any abnormality. There was no sign of ptosis while the eyes were open, and patients could close them readily on command. The strength of the OO was normal. Voluntary eye closure was sometimes effective in triggering scAEO. In addition, all patients showed episodes of involuntary drooping of the eyelids without any obvious sign of OO spasm such as the Carcot's sign. These episodes were followed by the characteristic diffi-

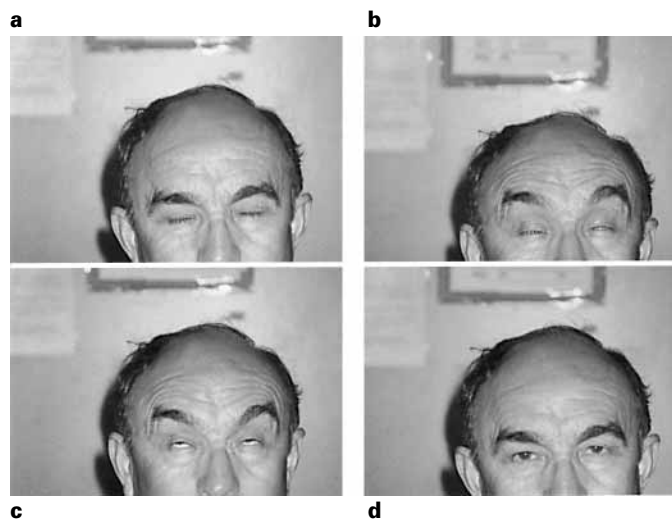


Fig. 1. A patient with isolated scAEO. **a-d** Photographs were taken in succession and demonstrate the characteristic transient inability to raise eyelids following eye closure. Note the bilateral contraction of the frontalis muscle on attempted eye opening.

Table 1. Demographic and clinical features in 10 patients with isolated apraxia of eyelid opening

Patient	Sex, age at onset years	Duration of illness, years	Family history	Antecedent events
1	M, 56	3	Brother with BS, OMD, CD	-
2	F, 53	8	-	Anxiety, benzodiazepines
3	M, 60	4	Father, brother and 2 paternal aunts with AEO	Glaucoma
4	F, 60	3	-	Depression
5	F, 61	3	-	-
6	F, 58	3	-	Hypertension, flunarizine
7	F, 64	5	-	Anxiety, benzodiazepines
8	M, 53	12	-	Photophobia, grittiness of the eyes
9	M, 57	8	-	Irritation, grittiness of the eyes
10	F, 56	3	-	Watering and grittiness of the eyes

OMD = Oromandibular dystonia; CD = cervical dystonia; AEO = apraxia of eyelid opening; M = male; F = female.

culty in raising eyelids (fig. 1). Involuntary drooping of the eyelids frequently occurred in those patients who were classified as functionally blind or severely handicapped (see below) according to the interpretation of the disability scale proposed by Lindeboom et al. [21]. In these individuals, lid closure following voluntary or involuntary eye closure lasted a considerable number of seconds to a few minutes. Geste antagoniste (touching the eyelids or the temporal regions) was often used as a strategy to facilitate reopening. The frequency of the episodes of drooping the eyelids was reduced by alertness or, alternatively, relaxation, increased by bright light, reading, and watching television.

Antecedent Events

Antecedent events are shown in table 1. Prior to the onset of scAEO, 2 cases suffered an anxiety state treated with benzodiazepines which, however, did not cure scAEO. Depression was reported by another case. A female patient with scAEO had been taking flunarizine for 6 years because of hypertension. No other neurological sign was obvious and, thus, she was included in the present series. She was treated with pretarsal BT without any benefit (see below). Flunarizine was stopped 3 years after the scAEO onset; 3 months later, the patient experienced complete sustained remission of scAEO lasting 3.5 years.

One patient was affected by glaucoma prior to the onset of scAEO. Three additional cases experienced ocular symptoms consistent with diseases or irritations of the eyes (including photophobia, irritation, watering or grittiness of the eyes) in the year before the onset of scAEO. At the time of survey, mean duration of scAEO in patients with prior eye symptoms was 6.3 years (SD, 3.2). No patient developed new eye problems later during the course of scAEO.

Family History

scAEO was observed in the brother of a male case (table 1). He did not suffer from any other CNS disease. Their father and 2 paternal aunts (all deceased) were probably affected by the same disturbance. Another case (table 1) had a brother affected by cranial-cervical dystonia.

BT Treatment

Five patients (table 1: cases 1, 2, 6, 8 and 9) were injected with BT in the orbital/preseptal OO, but none improved. All patients were subsequently treated with pretarsal BT. After the initial treatment, the mean percent

Table 2. Summary of the clinical findings of 11 patients in the literature

Authors, year	Ref.	Case No., sex	Age at onset years	Illness duration years	Prior diseases
Katz, 1987	18	1, M	64	4	–
Elston, 1992	8	2, M	55	3	–
		4, F	64	4	–
		5, F	50	6	Depression
		1, F	55	3	Facial weakness
Dewey and Maraganore, 1994	17	2, F	13	1	Blepharitis
		3 cases	Not reported	Not reported	Not reported
Krack and Marion, 1994	9	3 cases	Not reported	Not reported	Not reported
Aramideh et al., 1994	3	21, F	64	7	–
Aramideh et al., 1994	4	5, F	64	8	Blepharochalasis

of normal activity was raised from 26% (SD, 15.8) to 55% (SD, 17.6) ($p < 0.01$). At baseline, 4 patients were functionally blind, 2 were severely limited, and 4 had moderate to marked limitation in the activities of daily living. Under pretarsal BT there were 1 functionally blind patient, 5 cases with moderate and 4 cases with minor limitation in the activities of daily living. Overall, 2 cases (one functionally blind, the other with moderate to marked limitation in the activities of daily living) remained unchanged, whereas 8 improved. Responder and nonresponder patients did not differ in regard to demographic and clinical features. Following eye closure, either voluntary or involuntary, responder patients were able to raise eyelids a few seconds after the command. Moreover, BT-induced improvement was accompanied by a reduction of the frequency of the episodes of involuntary drooping of the eyelids. Responder patients remained under treatment with 10 U BT per eye. They received a total of 107 treatment sessions with a mean follow-up of 2.7 years (SD, 1.5) and a mean of 10.7 treatment sessions per patient (SD, 4.6). Onset of improvement was noticed after a mean of 4.2 days (range 3–7 days) and the mean duration of effect was 2.3 months (range 2–3 months). Overt ptosis was never observed, whereas mild lacrimation lasting 2–5 weeks was reported in 15% of treatment sessions. The 2 patients who did not respond to pretarsal administration of 10 U BT (table 1: cases 1 and 6) remained unchanged even after increasing pretarsal BT up to 20 U and in spite of adequate weakness of the pretarsal OO (revealed by difficulty in occluding the palpebral fissure gently). One of these patients (table 1: case 6) experienced complete remission of scAEO following discontinuation of flunarizine (see above).

Review of the Literature

In reviewing the literature from 1965 to 1996, we found 11 patients with isolated scAEO [3, 4, 8, 9, 17, 18] in a total of approximately 200 reported cases. Detailed clinical description was lacking in 3 patients [9]. In the remaining 8 cases (table 2), age at onset was between 13 and 64 years (mean, 52.1; SD, 19.9), duration of symptoms was between 1 and 8 years (mean, 4.5; SD, 2.2), and there was a female preponderance of 3:1. Four patients reported antecedent events [4, 9, 17] including eye diseases ($n = 2$), facial weakness ($n = 1$) and depression ($n = 1$). In addition to inability to open eyes on command, episodes of involuntary drooping of the eyelids without any ongoing OO contraction were described in 4 cases [3, 4, 17]. EMG recordings of OO and LPS on attempted eye opening were available in 4 cases [3, 4, 8], with abnormalities being defined as excessive muscle activity limited to the pretarsal OO ($n = 2$) or failure to initiate or sustain LPS activity ($n = 2$).

Isolated scAEO completely resolved following treatment with *l*-dopa in 2 cases [17]. Seven patients were treated with BT according to different injection protocols: 3 cases experienced BT treatment inducing global OO weakening [8], but results were poor; 3 other cases were treated with BT injections at the junction of preseptal and pretarsal OO [9], but improvement was modest leaving them with considerable residual disability; finally, BT injections in the orbital OO and frontal muscles were of benefit in a male patient [18].

Discussion

scAEO has mainly been described in association with diseases affecting the extrapyramidal system [2–11] or, less frequently, the right hemisphere [12–14]. scAEO developing in the absence of any CNS disease is generally considered very rare: to our knowledge, only 11 such patients have been described over a 30-year period [3, 4, 8, 9, 17, 18]. Thus, the origin, nature and clinical features of isolated scAEO are uncertain.

To further investigate these issues, we looked for isolated scAEO among 150 consecutive outpatients with excessive bilateral eye closure referred to our movement disorder clinic over a 9-year period. According to Lepore and Duvoisin's [2] criteria, scAEO was diagnosed in 30 cases (20%), whereas 120 patients were followed for typical BS without discernible scAEO. Twenty scAEO patients (13.4%) suffered from extrapyramidal disorders, including dystonia and parkinsonism, the remaining 10 patients (6.6%) had no clinical or radiological evidence of CNS disease. Clinical-demographic features of patients with isolated scAEO, including mean age at onset in the 6th decade and female preponderance, did not differ from cases in the literature [3, 4, 8, 9, 17, 18]. Thus, our sample was probably representative of isolated scAEO.

In another outpatient series of 207 cases, Krack and Marion [9] observed 3 patients with isolated scAEO (1.4%), 29 with scAEO and extrapyramidal disorders (14%) and 175 with typical BS. The higher frequency of isolated scAEO in our than in Krack and Marion's population (6.6 vs. 1.4%) may have different explanations. First, the percentage of patients with isolated scAEO may change over time because of the development of other disorders such as dystonic BS. In our series, however, this was unlikely. In fact, patients complaining of isolated scAEO did not develop BS or other CNS diseases over 3–12 years, whereas coexistence of BS and scAEO was noted 0.5–2 years after the onset of eyelid discomfort. Second, prior underreporting of isolated scAEO may be due to misdiagnosis of a psychiatric disorder. Accordingly, 3 of our patients and 1 in the literature [8] reported antecedent psychiatric disturbances, i.e. anxiety and depression. However, the 20% incidence of anxiety and the 10% incidence of depression seen in our series are not likely to be of significance because a similar frequency of antecedent psychiatric disturbances was found in patients affected by other eyelid motor disorders of physical origin such as typical BS and hemifacial spasm [prior anxiety, 20 and 22% respectively; prior depression, 15 and 13% respectively; personal obs.]. In addition, treatment of anx-

ety and depression did not cure scAEO. The tentative conclusion is that isolated scAEO is due to a physical disorder rather than to a conversion reaction similar to 'hysterical blindness' but manifested instead by eye closure. Third, our patient population was from a regional referral center for movement disorders instead of a quaternary referral center. Therefore, our statistics may be closer to the true prevalence rates.

Apraxia has been defined by Geschwind [22] as a disorder of execution of learned movements that cannot be accounted for either by weakness, incoordination, or sensory loss. By definition, primary pathways related to eyelid motor activities are intact in scAEO [2]. In addition, patients with isolated scAEO have no clear evidence of CNS diseases. Although these considerations seem to justify the use of the term apraxia in isolated scAEO, the occurrence of episodes of involuntary drooping of the eyelids raises the possibility of abnormal regulation of eyelid motor function. Transient failure to sustain lid elevation was not included in the definition of AEO as given by Goldstein and Cogan [1] and Lepore and Duvoisin [2]. Nonetheless, it was also described in patients with scAEO and parkinsonism [3, 5], and in 4/8 cases with isolated scAEO reported in the literature [3, 4, 17]. Thus, inability to initiate and failure to sustain lid elevation are probably expressions of the same disturbance.

Four patients in the literature were investigated by EMG [3, 4, 8]. Overactivity of the pretarsal part of the OO or failure to initiate or sustain LPS activity were observed during the episodes of lid closure. Interestingly, similar abnormalities were described in patients with scAEO and extrapyramidal disorders [3, 5, 6, 8]. We did not perform EMG recordings of eyelid muscles, but the results of BT treatment further suggest that eyelid motor control may be abnormal in isolated scAEO. BT administration close to the pretarsal OO reduced both frequency and duration of the episodes of lid closure and improved the activities of daily living in 8/10 patients with isolated scAEO, whereas orbital/preseptal injections had no effect. At variance with our findings, most previous reports failed to observe any significant effect of BT on isolated scAEO [8, 9]. Differences in the injection protocol may, at least in part, explain the disagreement. Although BT can diffuse to neighboring muscles causing clinical or subclinical changes of neuromuscular transmission, our injection protocol probably induced selective weakening of the pretarsal OO. In extrapolation from rat data [23], in fact, we estimated that injecting 10 U BT/0.1 ml saline resulted in an area of paralysis of approximately 35–50 mm². This is comparable with the area occupied by the pretarsal OO,

and, accordingly, overt ptosis was never encountered. In previous reports [8, 9], BT was not specifically directed to the pretarsal OO. Thus, insufficient BT diffusion to the pretarsal OO and/or possible spread to the LPS muscle might have negatively influenced the outcome. Interestingly, application of BT into multiple sites of the OO, including its pretarsal portion, was effective in scAEO associated with, or triggered by, BS [6, 15, and personal obs.]. Furthermore, pretarsal BT dramatically improved scAEO in 3 of our 6 parkinsonian patients [personal obs.]. These findings suggest that similar mechanisms may underlie scAEO regardless of the clinical setting in which it occurs.

Because the LPS and pretarsal OO muscles are reciprocally involved in a number of spontaneous and reflex activities [24], weakening of the latter can, theoretically, affect LPS tone. Thus, BT responder patients may suffer from overactivity of the pretarsal OO, or, alternatively, from involuntary inhibition of LPS tonic activity. Supporting the latter view, Aramideh et al. [6] described 4 patients with BS who initially failed to respond to orbital/preseptal BT injections, but later improved with pretarsal injection: these patients were found by EMG to have both involuntary LPS inhibition and BS. LPS inhibition possibly associated with a disturbed reciprocal relationship of LPS and pretarsal OO muscles may be the most likely explanation in the patients who did not respond to BT despite of adequate pretarsal weakness.

If isolated scAEO is associated with an eyelid motor dysfunction, what are the clues to its origin? Dewey and Marangore [17] described 2 patients in whom AEO developed in the absence of any other CNS signs and resolved following treatment with *l*-dopa. This suggests an extrapyramidal dysfunction as possible explanation for isolated scAEO. Supporting this view, a few points can be made. First, development of isolated scAEO in one of our patients following prolonged exposure to flunarizine, and sustained remission when the drug was stopped, was in favor of a causal relationship between isolated scAEO and flunarizine, a drug known to induce extrapyramidal reactions [25]. Second, 4 of our 10 patients and 2/8 cases in the literature experienced diseases or irritations of the eyes prior to the onset of their scAEO. In another case scAEO followed prednisone-responsive bilateral facial weakness [17]. Overall, local injury to the eyes or face preceded the eyelid motor disturbance in 7/18 cases (39%). This is unlikely to be coincidental and adds to an increasing number of reports suggesting that local injury can trigger topographically related extrapyramidal movement disorders in predisposed subjects [26]. Because scAEO

onset may be prolonged or difficult to detect, local injury to the eyes or face may accompany or follow the eyelid motor disturbance without influencing the risk of scAEO. The presence of sensory tricks (*geste antagonistique*) in patients with isolated scAEO makes further contribution to the hypothetical extrapyramidal involvement, since tricks may be common in dystonia as well as in parkinsonism [27]. Finally, family history of cranial dystonia in one of our patients suggests a familial, possibly genetic, vulnerability of the extrapyramidal system. Familial clustering of isolated scAEO in another patient further supports the possibility of a genetic contribution, even though familial clustering may be coincidental or due to shared environmental factors.

Based on the above considerations, it is highly tempting to conclude that apraxia may not be the correct descriptive term, even when scAEO occurs without any other CNS disease. The results of our survey, namely those of BT treatment, suggest that isolated scAEO may be caused by a range of disorders involving motor activities in pretarsal OO and LPS muscles. A correlative EMG-BT study may be advised to further investigate the mechanism(s) underlying isolated scAEO, and to provide a correct definition of this underestimated, chronic, and frequently disabling cause of excessive eye closure.

Acknowledgements

The authors thank Mr. Donato Salamanno for computer-assisted review of the literature.

References

- 1 Goldstein JE, Cogan DG: Apraxia of lid-opening. *Arch Ophthalmol* 1965;173:155-159.
- 2 Lepore FE, Duvoisin RC: Apraxia of eyelid opening: An involuntary levator inhibition. *Neurology* 1985;35:423-427.
- 3 Aramideh M, Ongerboer de Visser BW, Devriese PP, Bour LJ, Speelman JD: Electromyographic features of levator palpebrae superioris and orbicularis oculi muscles in blepharospasm. *Brain* 1994;117:27-38.
- 4 Aramideh M, Ongerboer de Visser BW, Devriese PP, Bour LJ, Speelman JD: Clinical and electromyographic features of levator palpebrae superioris muscle dysfunction in involuntary eyelid closure. *Mov Disord* 1994;9:395-402.
- 5 Aramideh M, Ongerboer de Visser BW, Koelman JHTM, Speelman JD: Motor persistence of orbicularis oculi muscle in eyelid-opening disorders. *Neurology* 1995;45:897-902.
- 6 Aramideh M, Ongerboer de Visser BW, Brans JWM, Koelman JHTM, Speelman JD: Pretarsal application of botulinum toxin for treatment of blepharospasm. *J Neurol Neurosurg Psychiatry* 1995;59:309-311.
- 7 Brusa A, Meneghini S, Piccardo A, Stoehr R: Apraxia of lid opening. *Ital J Neurol Sci* 1981;4:367-370.
- 8 Elston JS: A new variant of blepharospasm. *J Neurol Neurosurg Psychiatry* 1992;55:369-371.
- 9 Krack P, Marion MH: 'Apraxia of lid opening', a focal eyelid dystonia: Clinical study of 32 patients. *Mov Disord* 1994;9:610-615.
- 10 Lepore V, Defazio G, Acquistapace D, Melpignano C, Pomes L, Lambert P, Livrea P, Ferrari E: Botulinum, a toxin for the so-called apraxia of lid opening. *Mov Disord* 1995;10:526-527.
- 11 Smith D, Ishikawa T, Dhawan V, Winterkorn JS, Eidelberg D: Lid opening apraxia is associated with medial frontal hypometabolism. *Mov Disord* 1995;10:341-344.
- 12 Algoed L, Janssens J, Vanhooren G: Apraxia of eyelid opening secondary to right frontal infarction. *Acta Neurol Belg* 1992;92:228-233.
- 13 De Renzi E, Gentilini M, Bazolli C: Eyelid movement disorders and motor impersistence in acute hemispheric disease. *Neurology* 1986;36:414-418.
- 14 Johnston J, Rosenbaum D, Picone C, Grotta J: Apraxia of eyelid opening secondary to right hemisphere infarction. *Ann Neurol* 1989;25:622-624.
- 15 Jankovic J: Apraxia of eyelid opening (letter). *Mov Disord* 1995;10:686.
- 16 Golbe LI, Davis PH, Lepore FE: Proposal for a clinical definition of blepharokolysis: Reply. *Mov Disord* 1991;2:183-188.
- 17 Dewey RB, Maraganore DM: Isolated eyelid-opening apraxia: Report of a new levodopa-responsive syndrome. *Neurology* 1994;44:1752-1754.
- 18 Katz B, Rosenberg JH: Botulinum therapy for apraxia of eyelid opening. *Am J Ophthalmol* 1987;103:718-719.
- 19 Defazio G, Livrea P, Guanti G, Lepore V, Ferrari E: Genetic contribution to idiopathic adult-onset blepharospasm and cranial-cervical dystonia. *Eur Neurol* 1993;33:345-350.
- 20 Fahn S: The assessment of primary dystonias; in Munsat TL (ed): *The Quantification of Neurologic Deficit*. Boston, Butterworths, 1989, pp 242-245.
- 21 Lindeboom R, De Haan R, Aramideh M, Speelman JD: The blepharospasm disability scale: an instrument for the assessment of functional health in blepharospasm. *Mov Disord* 1995;10:444-449.
- 22 Geschwind N: The apraxias: Neural mechanisms of disorders of learned movement. *Am Sci* 1975;63:188-195.
- 23 Shaari CM, Sanders I: Quantifying low location and dose of botulinum toxin injection affect muscle paralysis. *Muscle Nerve* 1993;16:964-969.
- 24 Porter JD, Burns LA, May PJ: Morphological substrate for eyelid movements: Innervation and structure of primate levator palpebrae superioris and orbicularis oculi muscles. *J Comp Neurol* 1989;287:64-81.
- 25 Micheli F, Pardal MF, Gatto M, Torres M, Paradiso G, Parera IC, Giannula R: Flunarizine- and cinnarizine-induced extrapyramidal reactions. *Neurology* 1987;37:881-884.
- 26 Jankovic J: Post-traumatic movement disorders: Central and peripheral mechanisms. *Neurology* 1994;44:2006-2014.
- 27 Hallett M: Is dystonia a sensory disorder? *Ann Neurol* 1995;38(2):139-140.

Copyright: S. Karger AG, Basel 1998. Reproduced with the permission of S. Karger AG, Basel. Further reproduction or distribution (electronic or otherwise) is prohibited without permission from the copyright holder.

Copyright: S. Karger AG, Basel 1998. Reproduced with the permission of S. Karger AG, Basel. Further reproduction or distribution (electronic or otherwise) is prohibited without permission from the copyright holder.