

Case report

Posthemiplegic focal limb dystonia: A report of two cases¹

Hülya Apaydin, Sibel Özekmekçi *, Naz Yeni

Department of Neurology, Medical School of Cerrahpaşa, Istanbul University, Istanbul, Turkey

Received 2 June 1997; received in revised form 31 July 1997; accepted 24 November 1997

Abstract

Posthemiplegic focal limb or hemidystonias are rare movement disorders usually due to vascular lesions of the contralateral basal ganglia. The pathogenesis of posthemiplegic dystonia is unknown and its management is usually difficult. In this paper, we report two patients who suffered from a single limb dystonia and hemidystonia, respectively. In the latter patient, hemidystonia developed due to an ischaemic cerebrovascular accident 2 or 3 months after the recovery of hemiplegia. Computed tomography and magnetic resonance imaging scans showed evidence of contralateral putamen and thalamus infarcts. © 1998 Elsevier Science B.V. All rights reserved.

Keywords: Hemiplegia; Dystonia; Basal ganglia lesion

1. Introduction

Dystonia is an abnormal movement characterized by sustained muscle contractions, frequently causing twisting and repetitive movements or abnormal postures [1]. Although dystonias are usually regarded as idiopathic, nearly 80–90% of mono or hemidystonias have been attributed to the lesions of contralateral thalamus or basal ganglia, involving infarcts, hemorrhages, arteriovenous malformations, tumours, abscesses or multiple sclerosis plaques [1–9]. Dystonias due to vascular occlusions or hemorrhages usually occur some time after the improvement in hemiplegia [3,4,7,9]. Two cases presented here developed dystonia 2 and 3 months after hemiplegia.

* Corresponding author. Present address: Bilim Sol. Dost Apt. No:8, D: 8, Erenköy 81070, Istanbul, Turkey. Tel.: +90 212 5861517; fax: +90 212 6320050.

¹ This study was presented in Focus on Dystonia as a poster presentation in Rome in March 1994.

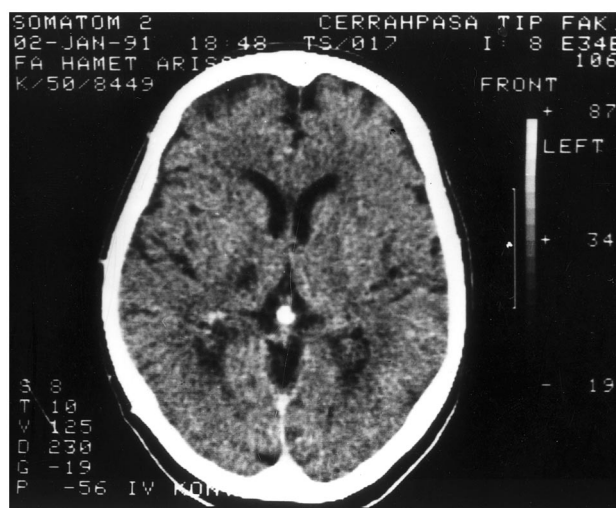


Fig. 1. Case 1. CT scan showing a hypodense lesion on the right thalamic region.

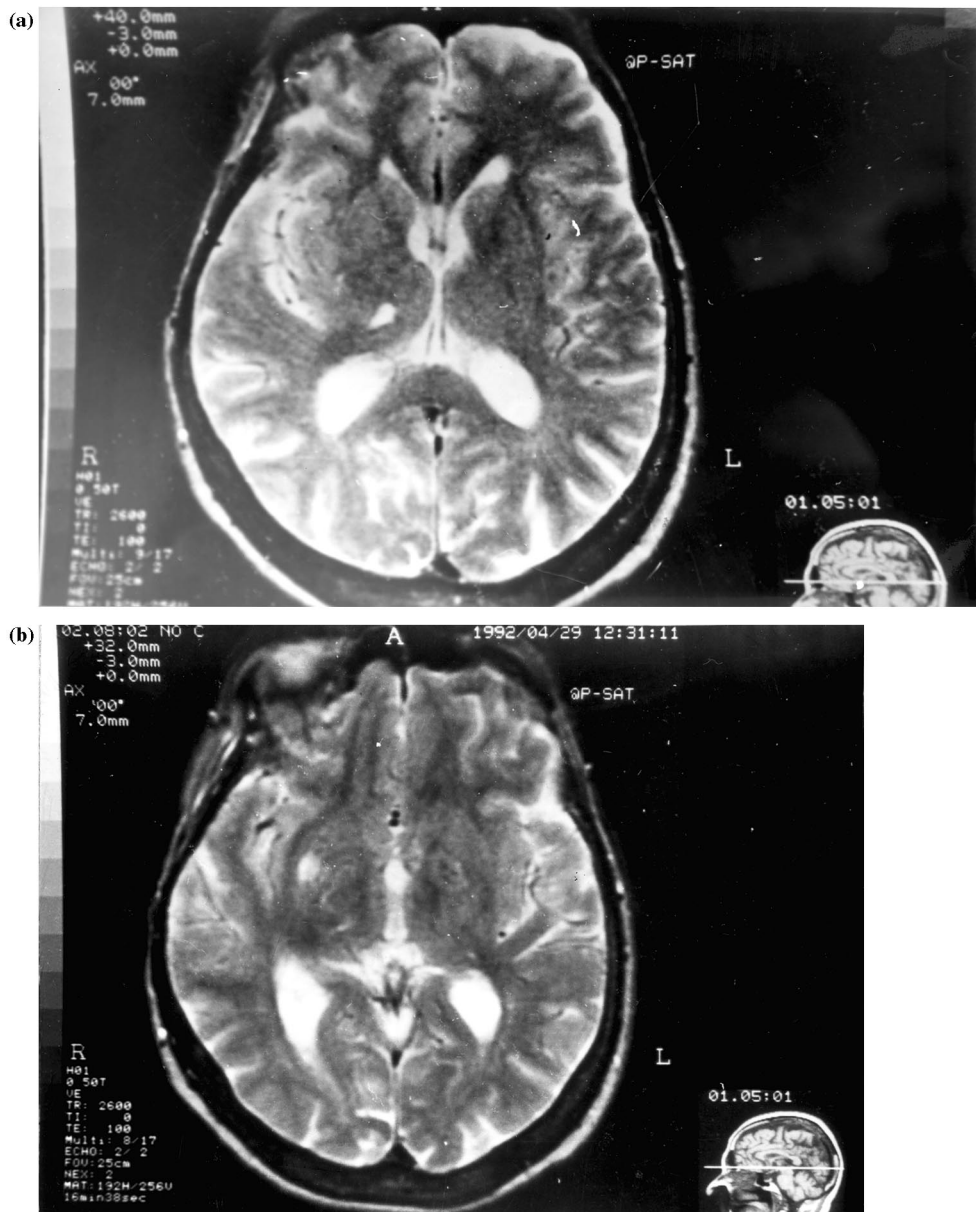


Fig. 2. T2-weighted MRI (TR = 2600, TE = 100) scan showing a hyperintense lesion in the right thalamic region (a) and in the right putamen (b).

2. Case report

2.1. Case 1

A 70-year-old woman acutely developed a left-sided weakness and numbness. Neurological examination revealed a flaccid left hemiparesis, hypoalgesia in the left maxillary area and the left arm and mild pyramidal dysarthria. The woman experienced long-standing arterial hypertension and had a smoking habit of half-pack a day for about 40 years.

Results of routine laboratory tests and cardiovascular examination were normal. Cranial CT showed a hypodense area of 1.5 cm in diameter in the right thalamic region and diffuse cortical atrophy (Fig. 1).

Recovery was noted by the 5th day of admission, after which she became ambulatory without support. Her hemiparesis considerably subsided 1 month later, whereas hyperpathia in the face and the arm developed. She developed involuntary movements in her left arm 3 months later, which were irregular, repetitive, partially slow, arrhythmic, undulatory and twisting type. The frequency and amplitude of these movements increased and some dystonic tremor and myoclonic jerks were added when held forward. She was unable to hold an object with her left hand. The follow up CT did not differ from those of the initial one. MR imaging showed signs of lacunar infarcts on the right thalamus and putamen (Fig. 2a,b).

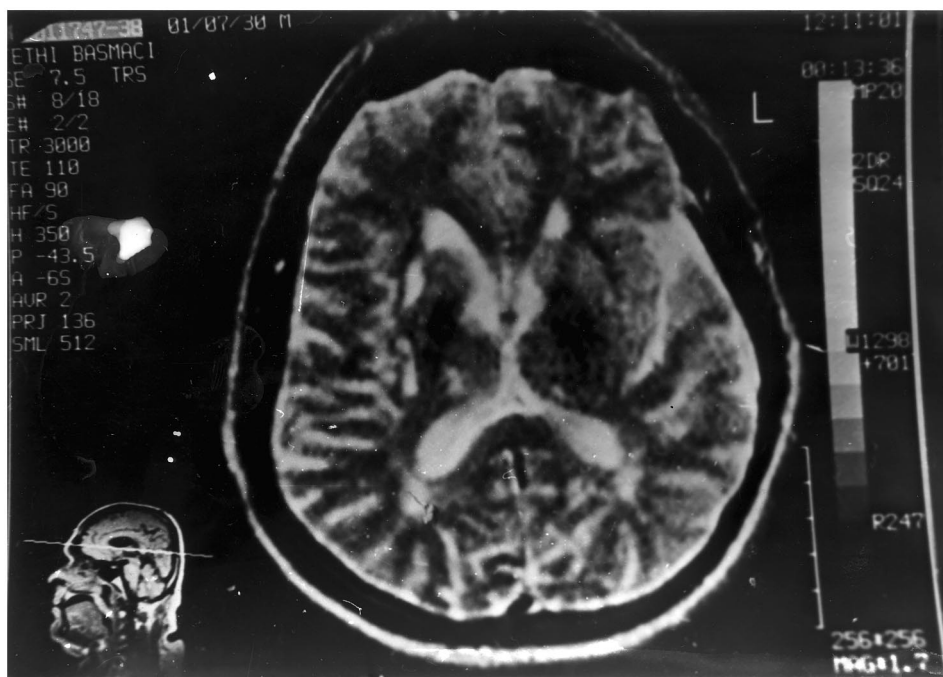


Fig. 3. Case 2. T2-weighted MRI (TR = 3000, TE = 110) scan showing hyperintense lesions in the right putamen and the thalamus.

The woman received Sinemet (carbidopa/levodopa) up to 75/750 mg daily, which was ineffective. Thereafter, she was given carbamazepine (CBZ), 400 mg t.i.d. and trihexyphenidyl 7.5 mg/day for her hyperpathia and dystonic movements, respectively. CBZ was increased up to 900 mg/day and the intensity and the extent of paresthesias reduced. Whereas trihexyphenidyl was discontinued because of adverse effects at doses 10 mg b.i.d., tetrabenazine was introduced up to 100 mg/day. Dystonic contractions reduced proximally 7 months later, but there was no change in those of the forearm muscles. At this time we remarked that her hemiparesis had totally disappeared.

2.2. Case 2

A 63-year-old man was admitted to the clinic with acutely developed left-sided weakness. On examination, a moderately severe left hemiparesis involving the face and left hemisensory impairment were evident. He had arterial hypertension for 5 years for which he did not receive any regular treatment. He had been smoking more than a packet of cigarettes a day for about 40 years. MR imaging of the brain showed signal hyperintensity in the right putamen and the thalamus consistent with an ischemic lesion (Fig. 3). He was started on antiplatelet therapy. Within 2 months, his hemiparesis subsided considerably, but he developed left-sided hyperpathy involving the face and also dystonic contractions at rest in the left arm and leg, which consisted of extension of the leg with inversion of the foot, and pronation of the forearm together with extension and

abduction of the fingers. Sinemet (carbidopa/levodopa) up to 75/750 mg daily, and baclofen up to 80 mg daily were ineffective. Minimal improvement was observed with clonazepam at doses 6 mg/day.

3. Discussion

We reported two cases with posthemiplegic focal and hemidystonia developed a few months after ischemic strokes due to thalamic and putaminal infarcts. Dystonia resulting from thromboembolic diseases of the basal ganglia and thalamus is relatively a rare complication [2,6,7]. Dystonias of vascular origin are mostly unilateral and generally follow a hemiplegia due to completed strokes [6,10], but occasionally they may follow a transient ischemic attack [3,11]. It is noticed that there is an interval between the first event and dystonia varying from a few weeks to 4 years [3,7,9–11] or even 9 years [12]. In our cases, dystonia occurred after 2 and 3 months following the stroke. Marsden et al. described 15 patients with posthemiplegic dystonias in 13 of whom dystonia delayed 2 months to 4 years after hemiplegia, and in the remaining two, dystonia developed simultaneously with hemiplegia [3]. Burton et al. reported a case of posthemiplegic dystonia developed 9 months after the primary event [4]. The cause of delay in dystonia occurrence following a stroke is not clear. However, it has been suggested that the impulses generated from the basal ganglia are transported mostly via the intact fibres of the corticospinal tract. If dystonia results from basal ganglia lesions, it is likely that dysto-

nia may occur at the same time as hemiplegia, but its clinical presentation is subsequent to the recovery of the corticospinal tract. It has been noted that the corticospinal tract might be preserved in dystonia cases [6]. However, the preventive role of hemiplegia in the delayed appearance of dystonia is controversial [3]. Burke et al. suggested that this delay in dystonia appearance is due to the gradually evolving aberrant neuronal sprouting stimulated by the primary lesion [13].

In our patients, the brain CT and MRI revealed some lesions compatible with infarcts in the thalamus and the putamen. In previous reports, in cases with posthemiplegic focal or hemidystonia, the site of the radiological lesions had been localized in the contralateral putamen and occasionally at the head of the caudate nucleus and the thalamus [2–4,6,7,14]. Marsden et al. suggested the putamen was involved in most of the cases [3]. Evidence from post-mortem examinations supported this observation [4,13]. On the other hand, Glatt and Nausieda described two patients with hemidystonia in whom basal ganglia were not involved, but cerebral lobes and the thalamus suggesting dystonic movement disorders could arise from some abnormalities out of the basal ganglia [7]. Recently, Lee and Marsdens review of reported cases with focal dystonia or hemidystonia showed that thalamus, especially posterior, posterolateral or paramedian parts were the exact sites of lesions [9]. Leherichy et al. noticed that the ventral intermediate and the ventral caudal nuclei of the thalamus were involved in such cases [15]. Although thalamic lesions themselves can cause dystonia, stereotaxic lesions placed in the thalamus have been used to treat dystonia. The sites of lesions in the thalamus causing dystonia explained above are different from the target for surgery which is ventrolateral thalamic nucleus [9]. Occasionally, hemidystonia can develop following the striatopallidal lesions [9,15]. In this situation, it was thought that secondary retrograde degeneration of thalamo-striatal neurons might result in thalamic atrophy. Sometimes lesions of both the thalamus and globus pallidus might produce dystonia [9]. Nardocci et al. in their report concerning 13 patients suggested that lesions of the striatum might induce contralateral dystonia which support the theory of striato-pallido-thalamic disconnection [12].

Bucher et al. showed that patients with dystonic syndromes had isolated lesions on globus pallidus internus (GPi) in T2-weighted MR images. They speculated that lesions in the GPi resulted in a loss of inhibitory pallidal projections to the thalamus, which might explain the hyperkinetic signs [8]. In another study, regional cerebral blood flow was measured with ($H_2^{15}O$) PET in five patients with acquired hemidystonia due to structural lesions of the basal ganglia or

posterior thalamus. The authors noticed that acquired hemidystonia was a syndrome of thalamofrontal disinhibition due to structural disruption of basal ganglia inhibitory control. In this study on movement of the dystonic arm primary and accessory motor areas showed greater activation than normal controls. In addition to this, frontal activation during movement of the unaffected limb was also abnormal in acquired hemidystonia [16]. The ischemic lesions at the so-called localizations are caused mostly by the occlusion of the lenticulostriate or thalamogeniculate arteries [10].

The dystonia types produced by thalamic infarcts were contralateral hemidystonia, focal or segmental dystonia [9], and rarely paroxysmal kinesigenic dystonic choreoathetosis [17]. Infrequently, thalamic infarcts extending into the upper brain stem caused blepharospasm and lesions in the subthalamic region produced hemidystonia with torticollis [9]. Previously, it was proposed that dystonia types due to the lesions of the thalamus, caudate nucleus or lentiform nucleus found to be similar [3,4]. However, recently it was noticed that lesions associated with dystonic spasms were located in the striatopallidal complex, and those with myoclonic dystonia were in the thalamus contralateral to the dystonia [15]. In our patients, all types of dystonic movements were observed. Symptomatic dystonia usually occurs in one arm or both in one arm or leg, and is rarely seen in one leg alone. Takahashi et al. reported a case of posthemiplegic dystonia in the right lower extremity [14].

Our patients developed hyperpathia as described in the Déjerine-Roussy syndrome which results from the occlusion of the thalamogeniculate branch of the posterior cerebral artery. In this syndrome, lacunar infarction involves mainly the ventral posterolateral and ventral posteromedial nuclei [18]. Both of the presented cases had thalamic infarctions. Hyperpathia may appear later up to several months like in our patients or may begin at the onset of the syndrome [18]. It was speculated that the origin of the hyperpathia might be beyond the areas that are normally controlled by the descending pain-inhibitory system [19]. On the other hand, dystonia and hyperpathia may appear together at the same time and in the same patient as in ours. The reason of this condition is that aforementioned structures responsible for hyperpathia are almost the same as, or in close relation with, those of dystonia.

Medical therapy of posthemiplegic dystonia usually does not result in a satisfactory outcome. Medications employed in symptomatic and idiopathic dystonias do not differ. We could not utilize botulinum-A toxin injections in the patients on financial grounds, though it is generally an accepted medical approach, leading to more favourable results.

References

- [1] Fahn S, Marsden CD, Calne DB. Classification and investigation of dystonia. In: Marsden CD, Fahn S, editors. *Movement Disorders*, vol. 2. London: Butterworth, 1987:332–58.
- [2] Russo LS. Focal dystonia and lacunar infarction of the basal ganglia: a case report. *Arch Neurol* 1983;40:61–2.
- [3] Marsden CD, Obeso JA, Zarranz JJ, Lang AE. The anatomic basis of symptomatic hemidystonia. *Brain* 1985;108:463–83.
- [4] Burton K, Farrell K, Li D, Calne DB. Lesions of the putamen and dystonia: CT and magnetic resonance imaging. *Neurology* 1984;34:962–5.
- [5] Coleman RJ, Quinn NP, Marsden CD. Multiple sclerosis presenting as adult onset dystonia. *Mov Disord* 1988;4:329–32.
- [6] Pettigrew LC, Jankovic J. Hemidystonia: a report of 22 patients and a review of the literature. *J Neurol Neurosurg Psychiatry* 1985;48:650–7.
- [7] Glatt SL, Nausieda PA. Posthemiplegic dystonia: radiographic and pharmacologic analysis. *Neurology* 1984;34(Suppl 1):290–1.
- [8] Bucher SF, Seelos KC, Dodel RC, Paulus W, Reiser M, Oertel WH. Pallidal lesions: structural and functional magnetic resonance imaging. *Arch Neurol* 1996;53:682–6.
- [9] Lee MS, Marsden CD. Movement disorders following lesions of the thalamus or subthalamic region (review). *Mov Disord* 1994;9:493–507.
- [10] Demierre B, Rondot P. Dystonia caused by putamino-capsulo-caudate vascular lesions. *J Neurol Neurosurg Psychiatry* 1983;46:404–9.
- [11] Weiner WJ, Lang AE. Symptomatic dystonia. In: Weiner WJ, Lang AE, editors. *Movement Disorders*. Mount Kisco, NY: Futura, 1989:419–56.
- [12] Nardocci N, Zorzi G, Grisoli M, Rumi V, Broggi G, Angelini L. Acquired hemidystonia in childhood: a clinical and neuroradiological study of 13 patients. *Pediatr Neurol* 1996;15:108–13.
- [13] Burke RE, Fahn S, Gold AP. Delayed-onset dystonia in patients with static encephalopathy. *J Neurol Neurosurg Psychiatry* 1980;43:789–97.
- [14] Takahashi K, Moshizuki H, Yoshino H, Imahi H, Mizuno Y. Post-hemiplegic dystonia with a discrete lesion in the postero-lateral part of the contralateral putamen. *Rinsho-Shinkeigaku* 1991;31(6):662–5.
- [15] Lehericy S, Vidailhet M, Dormont D, Piérot L, Chiras J, Mazetti P, Marsault C, Agid Y. Striatopallidal and thalamic dystonia: a magnetic resonance imaging anatomoclinical study. *Arch Neurol* 1996;53:241–50.
- [16] Ceballos-Baumann AO, Passingham RE, Marsden CD, Brooks DJ. Motor reorganization in acquired hemidystonia. *Ann Neurol* 1995;37:746–57.
- [17] Camac A, Greene P, Khandji A. Paroxysmal kinesigenic dystonic choreoathetosis associated with a thalamic infarct. *Mov Disord* 1990;5:235–8.
- [18] Mohr JP. Lacunes. In: Barnett HJM, Mohr JP, Stein BM, Yatsu FM, editors. *Stroke: Pathophysiology Diagnosis and Management*, 2nd ed. New York: Churchill Livingstone, 551 p.
- [19] Dehen H, Willer JC, Cambier J. Pain in thalamic syndromes: electrophysiological findings in man. In: Bonica JJ, Lindblom V, Iggo A, editors. *Advances in Pain Research and Therapy*, vol. 5. New York: Raven Press, 1983:935–40.