

Brief Communication

CROSSED CEREBRO-CEREBELLAR DIASCHISIS IN A PATIENT WITH MELAS WITH APHASIA BUT WITHOUT HEMIPARESIS

N.I.L.J. BOHNEN, M. BERAN-KOEHN, B. MULLAN and J.R. FULGHAM

Departments of Neurology and Nuclear Medicine, Mayo Clinic, Rochester MN 55905

(Received in final form 18 January 1997)

We describe a 25 year old woman diagnosed with MELAS during an acute stroke-like episode. Global aphasia, migraine-like headaches and hemi-anopsia were her main clinical features. MR imaging revealed extensive cortical and subcortical left hemispheric signal abnormalities. [Tc-99m]ECD SPECT scanning revealed crossed cerebocerebellar diaschisis. Aphasia in the absence of gross hemiparesis can be related to cross-cerebellar diaschisis in MELAS.

Keywords: Aphasia; cerebellum; diaschisis; MELAS; SPECT; stroke.

INTRODUCTION

Mitochondrial myopathy associated with Lactic Acidosis and Stroke-like episodes (MELAS) is a form of mitochondrial encephalomyopathy that may present with stroke-like episodes, seizures, myopathy, and optic atrophy in children or young adults (Hirano & Pavlakis, 1994). The term "diaschisis" refers to disturbance of function in an area remote from the site of a primary brain lesion (Meyer, Obara & Muramatsu, 1993). Baron et al. (1990) observed a parallel reduction in blood flow and oxygen use using PET in the cerebellar hemisphere contralateral to a supratentorial cerebral infarction and coined the term "crossed cerebellar

Correspondence to Dr. N. Bohnen, Department of Neurology and Division of Nuclear Medicine, The University of Michigan Medical Center, B1G412 University Hospital, Ann Arbor, Michigan 48109-0028.

diaschisis". It is probably caused by disruption of the corticopontinecerebellar pathways and is commonly seen in stroke patients with major motor deficits. It occurs less frequently in non-motor deficit stroke.

CASE DESCRIPTION

A 25-year-old woman presented with episodes of headache associated with homonymous vision field defects. Her previous medical history was significant for long standing hearing loss, short body status, and oral contraceptive medication. Initial MR imaging revealed increased T2 signal in the right occipital lobe that subsequently cleared. A new episode with headache and contralateral hemianopsia revealed increased T2 signal in the left occipital lobe extending into the posterior temporal and parietal lobe. Signal changes were more prominent in the cortex. Subsequently, patient was found to be in a withdrawn, depressed state and was transferred to Mayo Medical Center.

Clinical examination revealed a young slender woman of short body habitus with a surgically corrected micrognathia and minimal facial dysmorphic features. Neurologic examination revealed an alert woman with mixed sensory more than expressive aphasia; pupils were equal in size and reactive to light; fundoscopic examination showed bilateral optic atrophy. Patient was able to walk. Coordination was preserved; reflexes were brisk with a right sided Babinsky response in the absence of hemiparesis. MRI examination with FLAIR sequences revealed extensive increased signal in the left temporal, occipital and parieto-occipital lobes with mild mass effect and minimal radiologic evidence of uncal herniation. Minimal signal changes were seen in the medial right cerebellar hemisphere as well. Leptomeningeal enhancement was confined to the left occipital lobe. EEG revealed bi-occipital and left temporal slowing without epileptiform changes. Muscle biopsy findings revealed succinate dehydrogenase deficiency consistent with MELAS. Mitochondrial DNA analysis revealed not a specific defect.

The SPECT study were performed following intra-venous injection of 21.4 mCi of Tc-99m Ethylene Cysteine Dimer (ECD) in darkened room with the patient's eyes closed and the ears unplugged. Imaging was performed on a dual headed SPECT camera (Elscent Helix) equipped with ultrahigh-resolution fan beam collimators and acquired in a 128×128 matrix. There were 120 views at 3 degrees intervals for 15 seconds per view using a circular orbit. The energy setting was at 140 keV with a 15–20% window. The reconstruction was performed with a standard filtered backprojection algorithm, rebinned into 64×64 matrix with a 2X zoom, attenuated correction applied and viewed in the usual 3 orthogonal planes. The reconstructed system resolution was approximately 7mm

FWHM and the pixel size was 4.4mm. Both color- and gray-scale images were used for qualitative visual interpretation.

The study shows a large area of significantly decreased perfusion in the left temporal, parietal and occipital lobes. At the edges of the defects there is focally increased perfusion particularly at the fronto-parietal junction. Perfusion to the left basal ganglia is increased compared to the right. The areas of increased perfusion may related to blood flow to brain compressed by edema as luxury perfusion is said not to occur with Tc-99m ECD. Cerebellar perfusion is asymmetric with reduction on the right cerebellar hemisphere in keeping with crossed cerebellar diaschisis. Thalamic perfusion may be minimally reduced on the left [Fig. 1].

DISCUSSION

Reports of SPECT studies in patients with MELAS are scarce and indicate early enhanced perfusion followed later by are of low perfusion at the sites of the

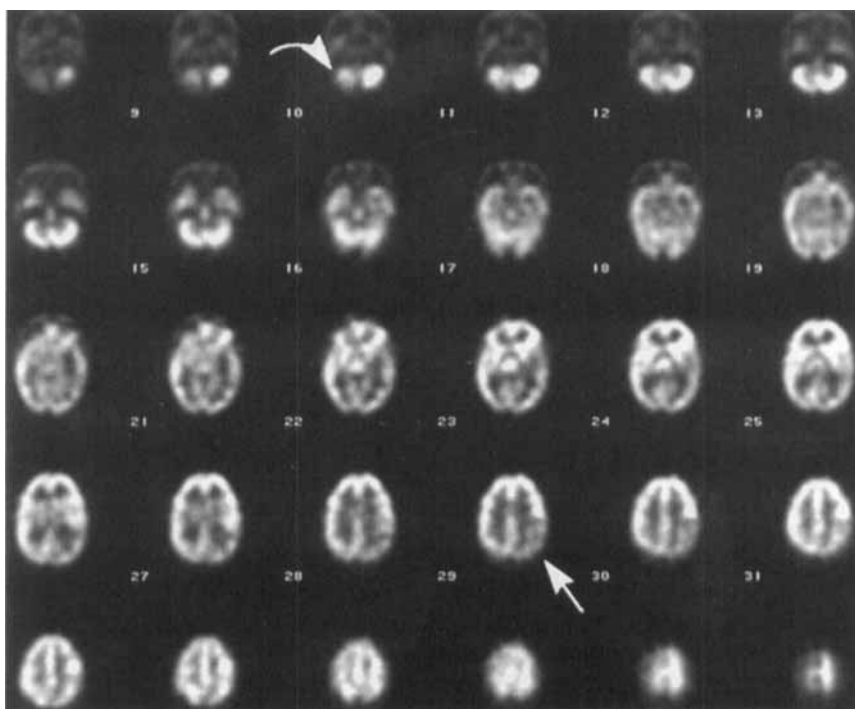


FIGURE 1 SPECT perfusion study shows crossed right cerebellar diaschisis and reduced radiotracer activity in the left temporal and occipital lobes.

reported stroke-like imaging abnormalities (Gropen et al., 1994; Fujii et al., 1995).

Crossed cerebellar diaschisis most often occurs with a hemiparesis, indicating functional damage to motor projection pathways from cortex to cerebellum (Meyer et al., 1993). Barker et al. (1991) studied the effect of behavioral activation on cerebral and cerebellar glucose metabolism in healthy volunteers when performing a verbal memory task. This PET study revealed asymmetric metabolic activation which was opposite in direction within the cerebral and cerebellar hemispheres. This coupled metabolic activation of one cerebellar hemisphere and areas within the opposite cerebral hemisphere represents the inverse of crossed cerebellar diaschisis phenomenon commonly observed in supratentorial lesions. Overall, these authors found that the predominant supratentorial activation was within the left hemisphere and is likely due to the left hemisphere's dominance for language function.

With respect to MRI data and diaschisis, Stübgen (1995) reported a case with focal motor seizures and extensive right hemispheric signal abnormalities and mild left medial cerebellar signal changes that resolved 6 weeks later. This may have been the first report of MRI evidence of diaschisis.

The presence of prominent crossed cerebellar diaschisis in our patient with severe aphasia but without apparent hemiparesis further illustrates the importance of the cerebellum in behavioral functioning. Botez and colleagues (1991) postulated at least 3 main anatomical pathways which could be involved in crossed cerebellar diaschisis. One of these arises from the posterior parietal association cortices to the basis pontis and could have been involved in our patient. Further studies are needed to clarify the role of the cerebellum in relation to behavioral functioning.

References

- Barker, W. W., Yoshii, F., Loewenstein, D. A., Chang, J. Y., Apicella, A., Pascal, S., Boothe, T. E., Ginsberg, M. D. & Duara, R. (1991). Cerebrocerebellar relationship during behavioral activation: a PET study. *Journal of Cerebral Blood Flow and Metabolism*, **11**, 48–54.
- Baron, J. C., Bonsser, M. G., Comar, D. & Castaigne, P. (1980). Crossed cerebellar diaschisis in human supratentorial brain infarction. *Transactions of the American Neurological Association*, **105**, 459–461.
- Botez, M. I., Léveillé, J., Lambert, R. & Botez, T. (1991). Single photon emission computed tomography (SPECT) in cerebellar disease: Cerebello-cerebellar diaschisis. *European Neurology*, **31**, 405–412.
- Fujii, T., Okuno, T., Ito, M., Hattori, H., Mutoh, K., Go, T., Shrirasaka, Y., Shirasishi, H., Iwasaki, Y. & Asato, R. (1995). ¹²³I-IMP SPECT findings in mitochondrial encephalomyopathies. *Brain and Development*, **17**, 89–94.
- Gropen, T. I., Prohovnik, I., Tatemichi, T. K. & Hirano, M. (1994). Cerebral hyperemia in MELAS. *Stroke*, **25**, 1873–1876.
- Hirano, M. & Pavlakis, S. G. (1994). Mitochondrial myopathy, encephalopathy, lactic acidosis, and stroke-like episodes (MELAS): current concepts. *Journal of Child Neurology*, **9**, 4–13.
- Meyer, J. S., Obara, K. & Muramatsu, K. (1993). Diaschisis. *Neurological Research*, **15**, 362–366.
- Stübgen, J-P. (1995). Crossed cerebellar diaschisis related to recurrent focal seizures. *Epilepsia*, **36**, 316–318.