

Selective Kana Jargonagraphia Following Right Hemispheric Infarction

Ritsuo Hashimoto, Yasufumi Tanaka, and Mitsuo Yoshida

Department of Neurology, Jichi Medical School, Tochigi, Japan

A strongly right-handed Japanese man showed an unusual writing disorder associated with Broca-type aphasia after suffering a right hemispheric infarction. Writing with his right hand produced a fluent output in contrast to his nonfluent speech. The patient's agraphia disproportionately affected the writing of kana (Japanese syllabograms), leaving relatively intact the writing of kanji (Japanese ideograms). His kana agraphia, consisting of substitutions, intrusions, transpositions, and deletions, became apparent as the number of syllables in target words increased. Quantitative analysis of the substitutions in terms of their phonological similarity to the target revealed that most of the substitutions were phonologically dissimilar. Those errors were distributed almost identically for familiar and novel words. Moreover, the errors were observed asymmetrically across the target: more errors occurred near the end than at the beginning of a word. The kana agraphia in association with fluent writing output resulted in kana jargonagraphia. These observations suggest that our patient's selective kana jargonagraphia is best explained by selective damage to the hypothesized kana graphemic buffer and by disinhibition of the motor engrams of writing behavior, both of which resulted from right hemispheric damage.

© 1998 Academic Press

Key Words: crossed aphasia; kanji and kana; jargonagraphia; graphemic buffer.

INTRODUCTION

Writing is a highly complex function that combines linguistic, acoustic, praxic, space-constructural, visual, and motor components. Various forms of agraphia that result from a disturbance of the writing process have been described (Roeltgen, 1993).

Crossed dextral aphasia is a relatively rare condition defined as aphasia in

We thank Mr. Masami Todoriki (Photographic Center, Jichi Medical School) for assistance in the preparation of figures. We also thank Drs. Ryoko Kurihara and Kunihiro Ikeguchi (Department of Neurology, Jichi Medical School) for referring the patient to us.

Address correspondence and reprint requests to Ritsuo Hashimoto, Department of Neurology, Jichi Medical School, 3311-1 Yakushiji, Minamikawachi, Tochigi 329-04, Japan. Fax: 81+285-44-5118.

a right-handed patient induced by a right hemispheric lesion (Yanell, 1981). Agraphia in individuals with crossed dextral aphasia differs from that seen in aphasic individuals with left hemispheric lesions (Brown & Wilson, 1972; Yanell, 1981; Henderson, 1983; Alexander et al., 1989; Imura et al., 1959; Kishida et al., 1976; Yokoyama et al., 1981; Endo et al., 1982; Washimi et al., 1987; Ihori et al., 1994). Alexander et al. (1989) reported that jargonagraphia is a feature of the anomalous type (nonmirror type) of crossed aphasia. However, the mechanism of jargonagraphia remains unknown. We evaluated a strongly right-handed Japanese man who developed crossed Broca's aphasia with severe kana (Japanese syllabograms) agraphia, resulting in jargonagraphia. We investigated the level of his dysfunction within the framework of a component model of the writing process.

CASE REPORT

TM was a 59-year-old, right handed, university-educated Japanese man. On June 18, 1994, he developed left hemiparesis and became mute. He was referred to our hospital 2 h after the onset of the stroke. Atrial fibrillation had been diagnosed when he was 55 years old. A hyperthyroid condition had been diagnosed 2 months before the infarction and he had been receiving propylthiouracil.

On admission, his blood pressure was 136/70 in association with absolute arrhythmia. He was awake, but did not speak spontaneously. A neurological examination revealed weakness of the left arm and leg. Evaluation of the cranial nerves showed no abnormalities except for a left central facial weakness. He was able to indicate yes or no answers to simple verbal questions using his unparalyzed right arm. Left hemihypesthesia was noted for touch, pain, and position sense. Deep tendon reflexes were symmetrical, with a left extensor plantar response.

A computed tomogram of the brain (CT) obtained 3 days after admission revealed an extensive low-density area in the right hemisphere consistent with an infarct in the territory of the right middle and anterior cerebral arteries. There were no low-density areas in the left hemisphere. The results of laboratory tests, including tests of thyroid function, were normal.

He remained completely mute for 2 weeks after admission. After 2 weeks, he was able to utter some words consisting of two or three syllables.

TM had no history of neurologic illness, developmental disorders, or traumatic head injuries. He was fully dextral (laterality quotient: 100), as determined by the Edinburgh Handedness Inventory (Oldfield, 1971). None of his parents, siblings, or children was left-handed.

Neuropsychological Examinations

A battery of neuropsychological tests was started on July 19, 1 month after the stroke. TM was observed closely for 2 months in the hospital. During

this period, his neuropsychological symptoms remained unchanged. He was attentive, cooperative, and oriented to time, place, and person. Motor imper-sistence was not observed during tasks such as keeping his eyes closed, tongue protrusion, and lateral gaze in either direction. Hemispatial neglect was not apparent during tasks such as drawing a daisy, bisecting lines, and checking scattered lines drawn on a piece of paper. He exhibited mild constructional apraxia, as determined by his performance on the tasks of copying a cube and the Rey-Osterrieth complex figure. His digit span, determined by asking him to point to the written number corresponding to a spoken number, was four digits forward and two digits backward. His visual memory span (Wechsler Memory Scale-Revised subset) was six tappings forward and five backward.

TM showed signs of buccofacial apraxia. He was unable to whistle, hiss, pantomime blowing out a lit match, cough, cluck his tongue, or puff his cheeks out in response to verbal commands. His performance on these tasks did not improve when he attempted to imitate the examiner's behavior, although some of these movements were performed spontaneously. His errors were related to poor execution of the task and substitution of correct but inappropriate movements. Nonrepresentational movements of the orofacial musculature, such as opening both eyes quickly, closing one eye at a time, and moving the lower jaw from side to side, were also impaired both in response to verbal commands and in attempts at imitation. He was able to use his right arm to pantomime saluting, beckoning, waving good-bye, combing his hair, brushing his teeth, sawing a board, and hammering a nail in response to verbal commands and in imitation of the examiner's movements.

Language Function

TM's spontaneous speech was nonfluent, hesitant, and effortful. His pronunciation was usually unclear and paraphasic, although occasionally correct. He was not able to read aloud, but his verbal comprehension was well preserved. His achievement on the Token Test was 95% for auditory and 92% for visual presentation of commands. The Standard Language Test for Aphasia (Takeda, 1977) showed that his auditory and reading comprehension for both kana and kanji was well preserved (Table 1). He showed severe speech disturbances in confrontation naming, repetition, reading, and narration, resulting from impaired articulation and literal paraphasia. These findings suggested that he had Broca's aphasia. In contrast to his nonfluent speech output, his writing output was fluent, with well-formed characters. He often tried to write down what he wanted to say to compensate for his speech difficulties. He could write some words correctly in kanji, but his kana writing was completely jargonagraphic, resulting in poorly organized syntactic structures. A confrontation writing and dictation test showed that he exhibited selective kana agraphia, in which he was able to write kanji

TABLE 1
Results of the Standard Language Test for Aphasia (SLTA)

Testing condition	Maximum possible score	Patient's score
Auditory comprehension		
Word recognition	10	10
Sentence recognition	10	10
Oral commands	10	6
Kana recognition	10	10
Speech		
Confrontation naming	20	3
Word repetition	10	1
Description of activities	10	0
Narrative	6	1
Animal naming	15	1
Oral reading		
Kanji words	5	0
Kanas	10	1
Kana words	5	0
Sentences	5	0
Sentence repetition	5	0
Reading comprehension		
Kanji word recognition	10	10
Kana word recognition	10	10
Sentence recognition	10	9
Written commands	10	8
Writing		
Written naming (kanji)	5	5
Written naming (kana)	5	2
Narrative writing	6	2
Dictation		
Kanas	10	10
Kanji words	5	5
Kana words	5	1
Sentences	5	2
Calculation	20	8

well but was unable to write kana. Although he was able to write an isolated kana letter correctly, he had difficulty with words consisting of more than two kana letters.

To elucidate the characteristics of the dissociation between kana and kanji writing, we prepared five sets of one- to five-syllable stimulus words. Each set consisted of 10 words with an equal number of syllables (Tanaka et al., 1987). The words were selected so that transcription with either kanji or kana was possible. In the Japanese script system, a kana letter represents one syllable and can be pronounced in only one way, whereas a kanji represents one or more syllables, depending on its use, and may be pronounced

in a number of different ways (Iwata, 1984). Therefore, the number of kana letters in a kana-written word equals the number of syllables in the word, while the number of kanji letters in a kanji-written word corresponds to a variable number of syllables. We selected kanji in which one to three syllables corresponded to 1-kanji words, four syllables to 2-kanji words, and five syllables to 3-kanji words.

TM was asked to transcribe dictated words into kanji and then into kana, beginning with one-syllable words and proceeding to words with more syllables. He was also asked to transcribe nonsense syllables (nonwords) into kana. He showed excellent kanji writing, regardless of the number of syllables in a word. In contrast, his rate of success with kana decreased as the number of syllables increased (Fig. 1A). TM's ability to copy kana words, kana nonwords, and kanji words was tested 5 days later and was found to be perfect. However, he had difficulty reproducing kana words and nonwords on a delayed copying task, in which he was asked to reproduce a target word 10 s after visual presentation (Fig. 1B). When TM's transcription ability was examined by asking him to transcribe a word into kanji 10 s after its presentation in kana, and vice versa, he was able to transcribe kana words into kanji without difficulty, but he was unable to transcribe kanji words into kana correctly. His rate of success with kana decreased as the number of syllables increased (Fig. 1C). Examples of the patient's writing are shown in Fig. 2. He also had marked difficulty with a spelling task that involved the sorting of kana anagrams. Because of his severe speech difficulties, his oral spelling could not be evaluated.

Dictation, delayed copying, and transcription errors consisted of substitutions, insertions, deletions, and transpositions. However, there were no illegible or incorrectly formed letters. TM's errors on kana words resulted in nonwords (nonlexical items). The number of types of errors increased as the number of syllables in the target words or nonwords increased (Tables 2 and 3). Errors were less frequent at the beginning of words and nonwords than in subsequent syllables (Fig. 3). The patient made errors in 65 (43%) of 150 syllables of dictated words and in 83 (55%) of 150 syllables of dictated nonwords. Errors in dictated words included 48 substitutions (74%), 5 insertions (8%), 11 deletions (17%), and 1 transposition (2%). Errors in dictated nonwords included 53 substitutions (64%), 3 insertions (4%), 15 deletions (18%), and 12 transpositions (14%). Therefore, the distribution of error types was similar in word and nonword dictation. We further evaluated the substitution errors in terms of their phonological similarity to the targets. A substitution was considered phonologically similar if it had a vowel or consonant in common with the target. Of the 48 substitutions that occurred in dictated words, 10 (21%) were phonologically similar and 38 (79%) were dissimilar. Of the 53 substitutions in nonword dictation, 21 (40%) were similar and 32 (60%) were dissimilar.

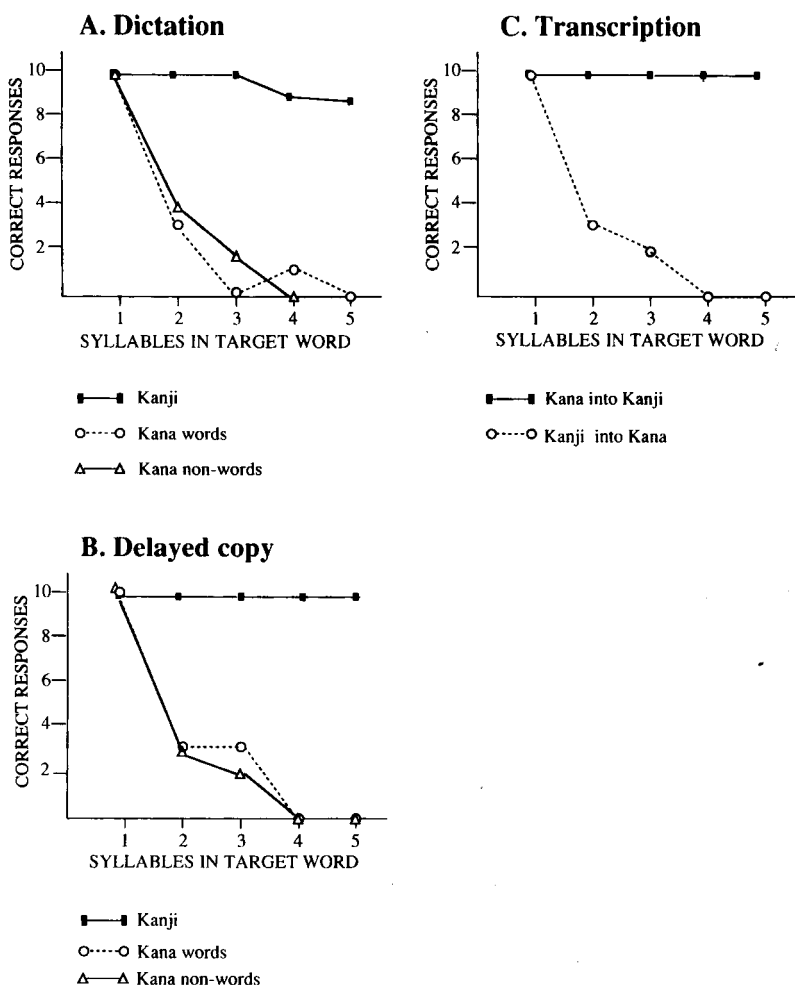


FIG. 1. (A) Dictation into kanji and kana. (B) Delayed copy. (C) Transcription.

Neuroanatomical Study

Serial brain CT scans performed during TM's hospital stay showed no changes in the hypodense area in the territory of the right middle and anterior cerebral arteries. No abnormal densities were observed in the left hemisphere (Fig. 4). When the CT scans were plotted onto standard templates according to the method of Damasio and Damasio (1989), the involved areas in the right hemisphere were found to be the medial part of the superior frontal gyrus, the anterior cingulate gyrus, the precentral gyrus, the posterior part

	<u>Target words</u>		<u>Patient's attempt</u>	
	Kanji	Kana	Kanji	Kana
Visit	見学	けんがく ke-n-ga-ku	見学	けんけんた ke-n-ge*-n†-ta*
Arithmetic	算数	さんすう sa-n-su-u	算数	さんけん sa-n-ke*-n*
Music	音楽	おんがく o-n-ga-ku	音楽	おんが o-n-ge*-†
Greenhouse	温室	おんしつ o-n-si-tsu	温室	おんつけ o-n-tsu**-ke*
Official	役人	やくにん ya-ku-ni-n	役人	やくひゃん ya-ku-hya*-n
* substitution error † insertion error ‡ deletion error ** transposition error				

FIG. 2. Examples of a four-syllable dictation into kanji and kana. There were no errors in kanji transcription, but several types of errors occurred in kana transcription.

of the superior and middle frontal gyri, the posterior part of the inferior frontal gyrus (pars opercularis), the insula, the postcentral gyrus, the superior parietal lobule, the supramarginal gyrus, and the angular gyrus.

DISCUSSION

TM demonstrated mainly three types of neuropsychological abnormalities after right hemispheric infarction: selective kana jargonagraphia, Broca's aphasia, and buccofacial apraxia. TM had no previous history of brain damage or family history of left-handedness. CT showed that the infarction was confined to the right hemisphere. These findings indicate that this patient was one of the rare cases of crossed dextral Broca's aphasia. TM had an extensive lesion over the suprasylvian area of the right hemisphere, and such a large lesion in a patient with standard aphasia with a left hemispheric lesion would be expected to produce some degree of comprehension difficulty. However, comprehension of both spoken and written language was well pre-

TABLE 2
Errors in Kana Writing of Dictated Words

Error types	Target word			
	Two letters (<i>n</i> = 10)	Three letters (<i>n</i> = 10)	Four letters (<i>n</i> = 10)	Five letters (<i>n</i> = 10)
Single-letter errors				
Substitution	7	2	2	1
Insertion	0	1	0	0
Deletion	0	0	0	1
Multiple-letter errors				
Multiple substitutions	0	6	2	3
Deletion and substitution	0	1	2	1
Substitution and insertion	0	0	1	1
Multiple substitutions and insertion	0	0	2	0
Transposition and substitution	0	0	0	1
Multiple deletions	0	0	0	1
Multiple deletions and substitution	0	0	0	1

TABLE 3
Errors in Kana Writing of Nonwords

Error types	Target nonword			
	Two letters (<i>n</i> = 10)	Three letters (<i>n</i> = 10)	Four letters (<i>n</i> = 10)	Five letters (<i>n</i> = 10)
Single-letter errors				
Substitution	4	0	0	0
Insertion	0	1	0	0
Deletion	0	1	0	0
Multiple-letter errors				
Multiple substitution	2	4	3	0
Deletion and substitution	0	1	1	2
Substitution and insertion	0	1	0	0
Multiple substitution and deletion	0	0	0	1
Transposition and substitution	0	0	1	0
Transposition and multiple substitution	0	0	4	0
Multiple deletion and multiple substitution	0	0	0	2
Transposition and substitution and deletion	0	0	1	3
Neologism ^a	0	0	0	2

^a Neologism, kana strings that had no letters corresponding to the target.

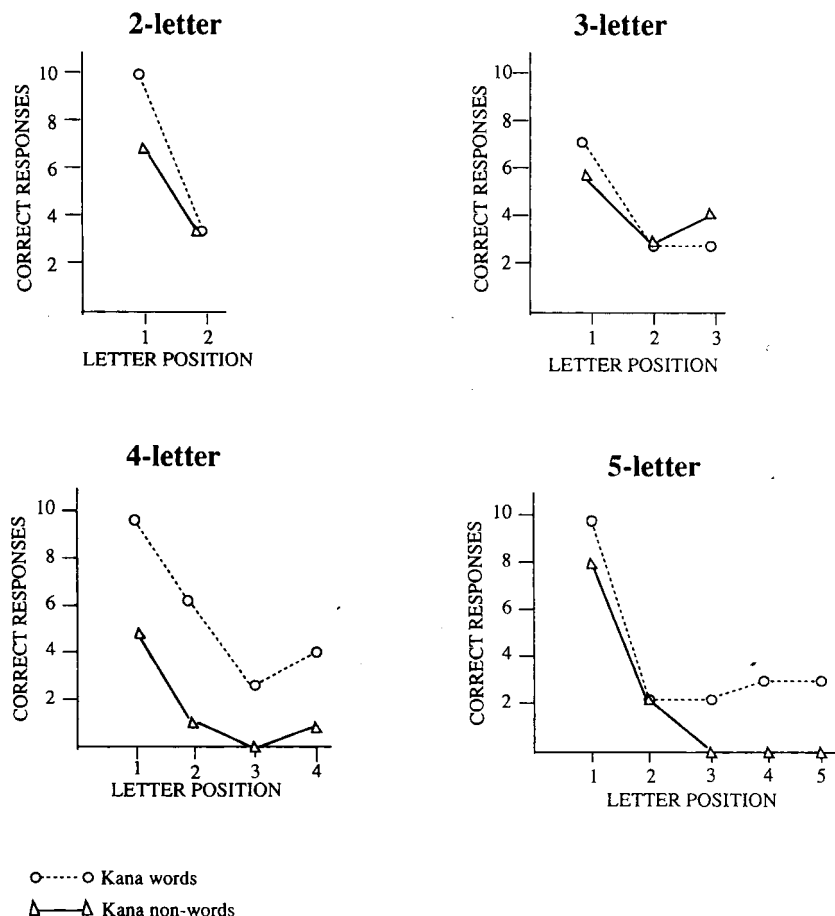


FIG. 3. Effect of letter position on kana errors.

served. In addition, TM exhibited characteristics that were inconsistent with classic aphasia in that his speech was nonfluent, but his writing was fluent. These findings suggest that TM had the anomalous (nonmirror) type of crossed aphasia (Alexander et al., 1989).

A particularly intriguing feature of the present case was the patient's writing disorder, namely, selective kana jargonagraphia. There are five previous reports of Japanese individuals with jargonagraphia in association with crossed aphasia. Broca's aphasia was diagnosed in 3 of these 5 patients (Imura et al., 1959; Yokoyama et al., 1981) and amnesic (Washimi et al., 1987) or Wernicke's aphasia (Ihori et al., 1994) in the remaining 2 patients. Alexander et al. (1989) reviewed 34 cases of crossed aphasia and found that 11 of 34 patients with various types of aphasia showed jargonagraphia,

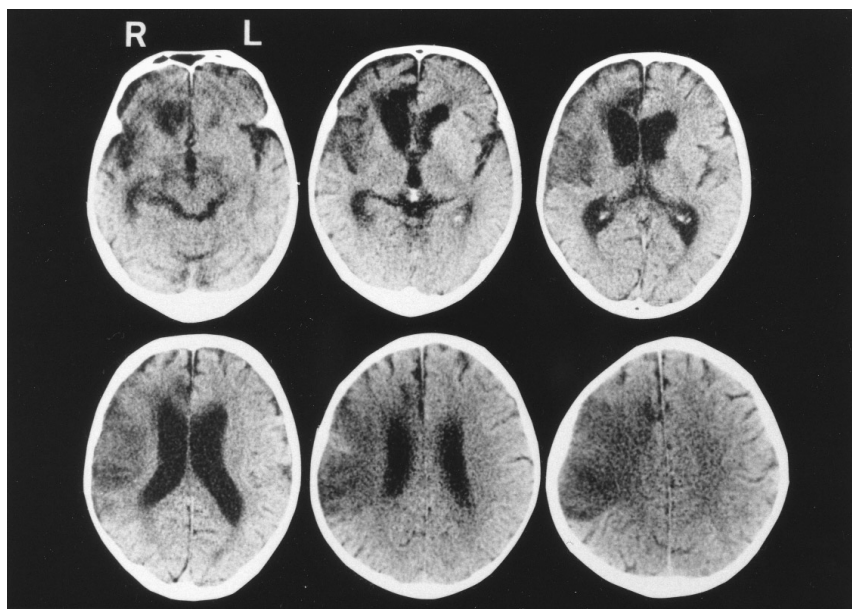


FIG. 4. CT scans performed 55 days after the onset of the stroke. A low-density area was observed in the territory of the right middle and anterior cerebral arteries.

suggesting that the type of aphasia is not primarily responsible for the appearance of jargonagraphia in patients with crossed aphasia. Jargonagraphia appears to be more frequent in patients with crossed aphasia than in patients with standard aphasia (Alexander et al., 1989; Ihori et al., 1994). These observations suggest that jargonagraphia results from a specific mechanism related to crossed aphasia.

Yokoyama et al. (1981) described two patients with crossed dextral aphasia whose neuropsychological profiles were very similar to our patient's profile. Both of their patients showed Broca-type aphasia and exhibited a striking dissociation between speech output and writing output: their speech was hesitant and effortful while their writing was fluent. Their patients also had kana jargonagraphia, but did not exhibit any type of apraxia. Yokoyama et al. hypothesized that when the right hand starts writing, the activity of the left motor area subserving the graphic motor engrams may become disinhibited from the control of the speech-dominant right hemisphere, resulting in autonomic-free operation of the left motor area and producing jargonagraphia. In other words, right hemispheric injury may lower the response threshold of writing behaviors, thereby creating a situation in which a subject tends to respond to targets with incomplete information. This hypothesis could explain the occurrence of jargonagraphia in any type of crossed aphasia and the dissociation between spoken and written output (Ihori et al., 1994).

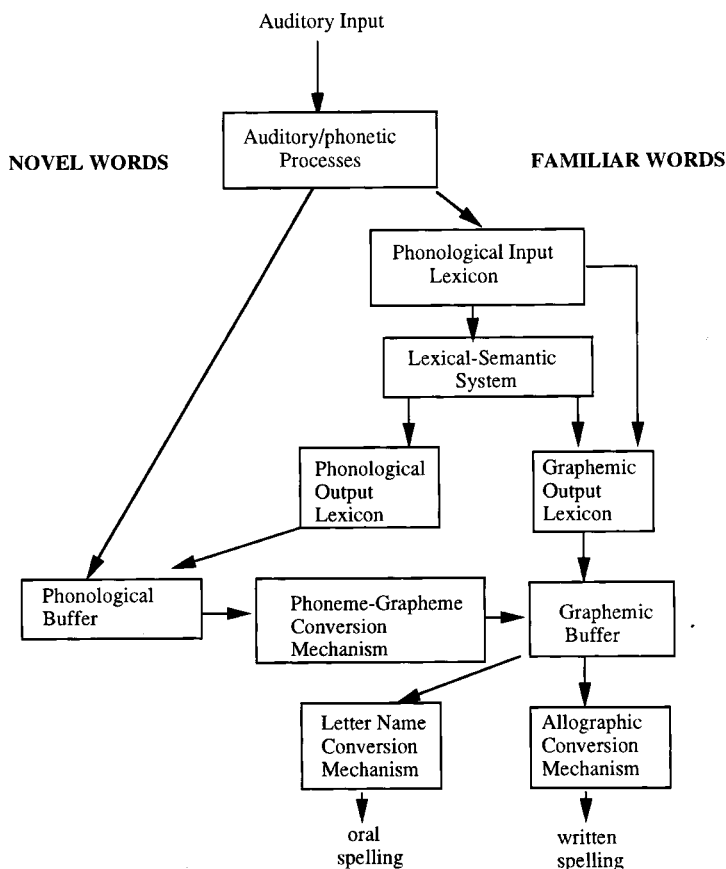


FIG. 5. Diagrammatic representation of a model of the spelling process "Reprinted from *Cognition*, 26 Caramazza et al., The role of the graphemic buffer in spelling: Evidence from a case of acquired dysgraphia, 59–85, 1987 with kind permission of Elsevier Science - NL, Sara Burgerhartstraat 25, 1055 KV Amsterdam, The Netherlands."

However, it does not explain the other features of TM's dysgraphia, in particular, the length effect and the dissociation between kana and kanji writing.

In recent years, investigations of cognitive disorders have been directed to formulate a detailed model of the component structure of a particular cognitive system which, when "lesioned" appropriately, functions in such a way to generate the patterns of cognitive impairments observed in brain-damaged patients (Caramazza et al., 1986). Caramazza and colleagues (Caramazza et al., 1986, 1987; Hillis & Caramazza, 1989) developed a diagrammatic representation of a model of the spelling process that corresponds to the various patterns of acquired dysgraphia observed clinically (Fig. 5). In a patient with crossed aphasia, such as TM, cognitive and linguistic neural

networks may be distributed so diversely across the hemispheres that an injury to one hemisphere could produce selective damage to the principal components of the writing process. Thus, dysgraphia associated with crossed aphasia is a good candidate for analysis of the level of dysfunction in terms of a component model of the spelling process.

TM showed comparable difficulties in written naming, delayed copying, and spelling-to-dictation in kana, suggesting that his dysgraphia was not due to damage to the input mechanism. More importantly, he demonstrated marked impairment of his kana writing ability as the number of syllables of the targets increased. This length effect suggests the presence of damage in a site working as a buffer. His errors, consisting of substitutions, deletions, transpositions, and insertions, were distributed almost identically for familiar and novel words. Quantitative analysis of the substitutions in terms of their phonological similarity to the targets revealed that phonologically dissimilar substitutions predominated in both word and nonword dictation. These observations suggest that his kana dysgraphia cannot be explained by lexical or phonological factors. The graphemic buffer is the hypothesized site at which the output of the linguistic systems converges. Therefore, damage to the graphemic buffer is assumed to result in similar errors in both oral and written spelling and in familiar words and nonwords; the length of a stimulus should be the only factor that influences the appearance of errors (Caramazza et al., 1987; Hillis & Caramazza, 1989; Lesser, 1990). Because of TM's speech disturbance, we were unable to analyze similarities or disparities between oral and written spelling. However, he had marked difficulty on a task involving the sorting of kana anagrams as well as writing, suggesting that the source of the dysfunction was at a level above these output modes. Based on these considerations, we believe that selective damage to the graphemic buffer is the most plausible explanation for TM's kana dysgraphia.

TM showed a dissociation in his ability to write kana and kanji. He was able to transcribe words into kanji even when the words required up to three kanji characters. Does this fact suggest that there are separate graphemic buffers for kana and kanji? A case of crossed Wernicke's aphasia described by Ihori et al. (1994) is interesting in this respect. Their patient exhibited jargonagraphia in both kanji and kana in the early days of his illness. His kanji jargonagraphia consisted of either nonexistent characters resulting from a derangement of combinations of radicals or parts of radicals of kanji or nonexistent words composed of single or plural kanji not related semantically, phonetically, or graphically to the target words. This observation suggests that a kanji grapheme is not necessarily an entire character and that a radical or part of a radical may function as a grapheme, unlike with kana, in which a single letter is assumed to act as a grapheme. Their patient's kanji writing, but not his kana jargonagraphia, gradually improved, supporting the theory that separate graphemic buffers exist for kana and kanji.

Finally, spelling errors were most common at the endings of words in the

present case. Wing and Baddely (1980) have suggested that a predominance of spelling errors at word endings may reflect an abnormally rapid decay of graphemic representations stored in the graphemic buffer. Our patient may have had a deficit affecting the rate of decay of kana graphemic information in the buffer whereby his ability to process word endings was affected to a greater degree than his ability to process the beginnings of words, resulting in the predominance of errors at word endings and an increase in the number and types of errors as the number of syllables increased.

This is the first report that evaluates selective kana jargonagraphia in terms of a component model of spelling process. Our patient's selective kana jargonagraphia appeared to be best explained by selective damage to a hypothesized kana graphemic buffer and by disinhibition of the motor engrams of writing behavior, both of which resulted from right hemispheric damage. Although the concept of a graphemic buffer has been proposed as an explanation of certain types of dysgraphia, the number of case studies is limited (Roeltingen, 1993). To clarify the structure and nature of a graphemic buffer, further studies are needed.

REFERENCES

- Alexander, M. P., Fischette, M. R., & Fisher, R. S. 1989. Crossed aphasics can be mirror image or anomalous. *Brain*, **112**, 953–973.
- Brown, J. W., & Wilson, F. R. 1972. Crossed aphasia in a dextral. *Neurology*, **23**, 907–911.
- Caramazza, A., Miceli, G., & Villa, G. 1986. The role of the (output) phonological buffer in reading, writing, and repetition. *Cognitive Neuropsychology*, **3**, 37–76.
- Caramazza, A., Villa, G., & Romani, C. 1987. The role of the graphemic buffer in spelling: Evidence from a case of acquired dysgraphia. *Cognition*, **26**, 59–85.
- Damasio, H., & Damasio, A. R. 1989. *Lesion analysis in neuropsychology*. New York: Oxford Univ. Press.
- Endo, K., Kurashima, H., Yanagi, H., Tsukada, Y., & Makishita, H. 1982. A comparison of the localization of higher cortical functions in crossed dextral aphasia and sinistral aphasia. *Shitsugosyo Kenkyu*, **2**, 341–350. [in Japanese]
- Henderson, V. W. 1983. Speech fluency in crossed aphasia. *Brain*, **106**, 837–857.
- Hillis, A. E., & Caramazza, A. 1989. The graphemic buffer and attentional mechanisms. *Brain and Language*, **63**, 208–235.
- Ihori, N., Kashiwagi, T., Kashiwagi, A., & Tanabe, H. 1994. Jargonagraphia in kanji and kana in a Japanese crossed Wernicke's aphasic. *Brain and Language*, **47**, 197–213.
- Imura, T., Akazawa, K., Hotta, S., & Nihonmatsu, S. 1959. A case of crossed aphasia. *Seishin Shinkeigaku Zasshi*, **61**, 1035–1043. [in Japanese]
- Iwata, M. 1984. Kanji versus kana: Neuropsychological correlates of the Japanese writing system. *Trends in Neurosciences*, **7**, 290–293.
- Kishida, K., Tsuruoka, H., Otsuka, A., Tsukuda, I., & Uemura, G. 1976. Aphasia and localization of brain lesions. Part 3. Crossed aphasia in dextral—Report on four cases. *Rinsho Shinkeigaku*, **16**, 677–686. [in Japanese]
- Lesser, R. 1990. Superior oral to written spelling: Evidence for separate buffers? *Cognitive Neuropsychology*, **7**, 347–366.

- Oldfield, R. C. 1971. The assessment and analysis of handedness: The Edinburgh Inventory. *Neuropsychologia*, **9**, 97–113.
- Roeltgen, D. P. 1993. Agraphia. In K. M. Heilman & E. Valenstein (Eds.), *Clinical neuropsychology*, 3rd ed. Oxford Univ. Press.
- Takeda, K. 1977. Standard language test of aphasia: Detailed description of construction of aphasia test in Japanese. *Shinkei Kenkyu No Shinpo (Tokyo)*. **21**, 1002–1013. [in Japanese]
- Tanaka, Y., Yamadori, A., & Murata, S. 1987. Selective kana agraphia: A case report. *Cortex*, **23**, 679–684.
- Washimi, Y., Makishita, H., Miyasaka, M., Fujita, T., & Yanagisawa, N. 1987. Crossed aphasia with jargonagraphia due to right putaminal hemorrhage: A study by ^{133}Xe single photon emission CT. *Rinsho Shinkeigaku*. **27**, 12–18. [in Japanese]
- Wing, A. M., & Baddely, A. D. 1980. Spelling errors in handwriting: A corpus and a distribution analysis. In U. Frith (Ed.), *Cognitive processes in spelling*. New York/London: Academic Press.
- Yanell, P. R. 1981. Crossed dextral aphasia: a clinical radiological correlation. *Brain and Language*, **12**, 128–139.
- Yokoyama, K., Okubo, M., Doseki, K., & Yamadori, A. 1981. Jargonagraphia in crossed motor aphasia. *Rinsho Shinkeigaku*, **21**, 961–967. [in Japanese]