

Endovascular treatment of mural-type vein of Galen malformations

VAN V. HALBACH, M.D., CHRISTOPHER F. DOWD, M.D., RANDALL T. HIGASHIDA, M.D.,
PETER A. BALOUSEK, M.D., SAMUEL F. CIRICILLO, M.D., AND MICHAEL S. B. EDWARDS, M.D.

Departments of Radiology, Neurointerventional Section, and Neurosurgery, University of California at San Francisco, San Francisco, California; and Department of Pediatric Neurological Surgery, Sutter Medical Systems, Sacramento, California

Object. In this study the authors report on the results of endovascular treatment for mural-type vein of Galen malformations (VGMs) in a group of infants.

Methods. Eight children (six infants and two neonates) who suffered from symptoms caused by a mural-type VGM were treated by means of endovascular therapy. Their age at the time of treatment ranged from 13 days to 19 months (mean 7.6 months). Two neonates and three infants who presented with hydrocephalus and increased head circumference, one of whom was stabilized with a shunt, underwent elective closure of the malformations 3, 4, 6, 6, and 13 months later, respectively. Two patients presented with hemorrhage; one had an intraventricular hemorrhage (IVH) on the 1st day of life and one, a 5-month-old infant, suffered a large parenchymal hemorrhage and an IVH; both patients were immediately cured by means of endovascular techniques. One child presented with a seizure and cortical venous drainage that were treated immediately. Eleven separate treatment sessions were conducted; eight via transarterial femoral access and the remaining three via a transvenous approach. Two patients were treated by using transfemoral transvenous embolization with fibered coils, and one patient required a transtorcular transvenous approach to permit complete closure of the fistula with electrolytically detachable coils. The embolic devices used included silk suture emboli (three patients), electrolytically detachable coils (three patients), and fibered platinum coils (seven patients). In seven patients, complete closure was demonstrated on postembolization arteriographic studies. The eighth patient had stagnant flow in a giant 6-cm varix treated with arterial and venous coils but has not yet undergone follow-up studies. Late follow-up arteriography was performed in four patients at times ranging from 11 to 24 months postprocedure. In one patient, thrombosis of the malformation and shrinkage of the varix were confirmed on follow-up computerized tomography scanning. The remaining three patients have not yet undergone follow-up angiographic examination. Two asymptomatic complications occurred, including separation of the distal catheter, which was removed with a snare device, and a single platinum coil that embolized to the lung, producing no symptoms in 101 months of clinical follow up. The follow-up period ranged from 3 to 105 months, with a mean of 52 months.

Conclusions. Endovascular therapy is the treatment of choice for mural-type VGMs and offers a high rate of cure with low morbidity.

KEY WORDS • vein of Galen malformation • platinum microcoil • embolization • mural-type malformation • arteriovenous malformation • children

Vein of Galen malformations (VGMs) are recognized as a rare cause of morbidity and mortality in the neonate and less commonly in infants.^{1,7-13,15} Neonates usually present with high-output cardiac failure, which is most often fatal despite medical therapy.^{8,10} Conversely, patients with VGM who present in infancy may have mild or no heart failure but usually present with developmental delay, hydrocephalus, and seizures.^{1,2,10,11,15} Lasjaunias and colleagues^{2,11,12} have proposed that VGMs be subclassified into two distinct types: choroidal and mural. Mural-type VGMs receive arterial supply from the collicular and posterior choroidal vessels that may be uni-

lateral or bilateral and drain into the median prosencephalic vein. Clinically, mural-type malformations present in infants with macrocephaly or failure to thrive and who have mild cardiac symptoms.^{2,11,12} We report on the results of therapy in eight children with mural-type VGMs that were treated with a combination of newer embolic agents: silk sutures, fibered platinum microcoils, and electrolytically detachable platinum coils.

Clinical Material and Methods

Between July 1986 and October 1997, 34 children with

Endovascular treatment of VGMs

TABLE 1
Summary of clinical characteristics in eight children treated for VGMs*

Case No.	Symptoms at Presentation	Age at Presentation	Age at Initial Treatment	Treatment	No. of Sessions	Clinical Follow Up (mos)
1	increasing HC, Parinaud's syndrome	2 mos	5 mos	TA coils, silk	2	101
2	increasing HC	prenatal	14 mos	TA coils, silk	1	90
3	hemorrhage	5 mos	5 mos	TA silk	1	90
4	increasing HC, seizure	19 mos	19 mos	TA & TT coils	2	51
5	mild CHF at birth, increasing HC	birth	5 mos	TA & TV coils	2	42
6	hemorrhage	birth	13 days	TV coils	1	35
7	increasing HC, Parinaud's syndrome, seizure	prenatal	6 mos	TA coils	1	4
8	increasing HC	4 mos	6 mos	TA coils	1	3

* CHF = congestive heart failure; HC = head circumference; TA = transarterial; TT = transtorcular; TV = transvenous.

VGMs were treated using endovascular techniques by our group at the University of California at San Francisco Medical Center. Twenty-six of these lesions were classified as choroidal-type VGMs by using the scheme proposed by Lasjaunias and colleagues,^{2,11,12} and eight (24%) were characterized as mural-type VGMs and are the subject of this publication.

Eight children (six infants and two neonates) who had mural VGMs were treated using a variety of interventional techniques including transarterial embolization (seven patients), transfemoral transvenous embolization (two patients), and transtorcular embolization (one patient), and combinations of embolic materials including silk suture emboli and fibered and nonfibered platinum microcoils. Table 1 summarizes these data as well as the age at presentation, age at treatment, number of treatment sessions and route, and duration of the clinical follow-up period.

Presenting Symptoms

Five of the children initially presented with increasing head circumference and hydrocephalus. One of the cases of hydrocephalus was detected in utero, and the child

underwent placement of a ventriculoperitoneal (VP) shunt at birth, which permitted a delay in endovascular therapy until the 14th month. A second child (Case 1) developed increasing head circumference and intermittent Parinaud's syndrome (Fig. 1) at 8 weeks of age. Because the child was developing normally otherwise with no seizures or cardiac symptoms, endovascular therapy was delayed until 5 months of age. A third child was noted to have ischemic changes on serial magnetic resonance (MR) images and received treatment at 6 months of age after suffering a seizure. The fourth child was noted to have congestive heart failure at birth and was successfully treated with medical therapy. He was noted to have increasing head circumference and was treated initially at 5 months of age. The fifth child was noted to have hydrocephalus at 4 months of age.

Two children presented with hemorrhage. The first was a neonate who presented at birth with a seizure and in whom computerized tomography (CT) scanning revealed a large intraventricular hemorrhage (IVH) with partial thrombosis of the prosencephalic vein. A second infant presented at 5 months of age with seizures and hemiparesis from a deep parenchymal hemorrhage and IVH (Fig.

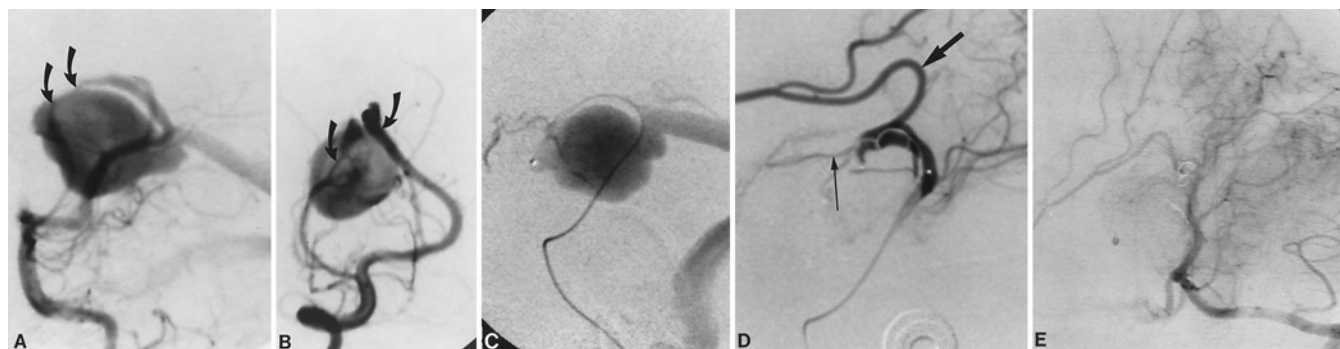


FIG. 1. Case 1. A and B: Left vertebral arteriogram, anteroposterior (A) and lateral (B) projections, demonstrating two separate connections (curved arrows) between the lateral posterior choroidal branches of the PCA and the midline prosencephalic vein. C: Arteriogram showing selective microcatheter injection after placement into the distal fistula (see corresponding arteriogram [B]). D: Postembolization selective arteriogram obtained after placement of platinum coils and silk suture into the fistula site, demonstrating complete fistula closure. Note reflux into the distal anterior cerebral artery (straight black arrow) through the limbic arcade and continued patency of the medial posterior choroidal artery (long thin arrow). E: Left vertebral injection arteriogram, lateral projection, obtained 14 months postprocedure demonstrating persistent and complete closure of the VGM.

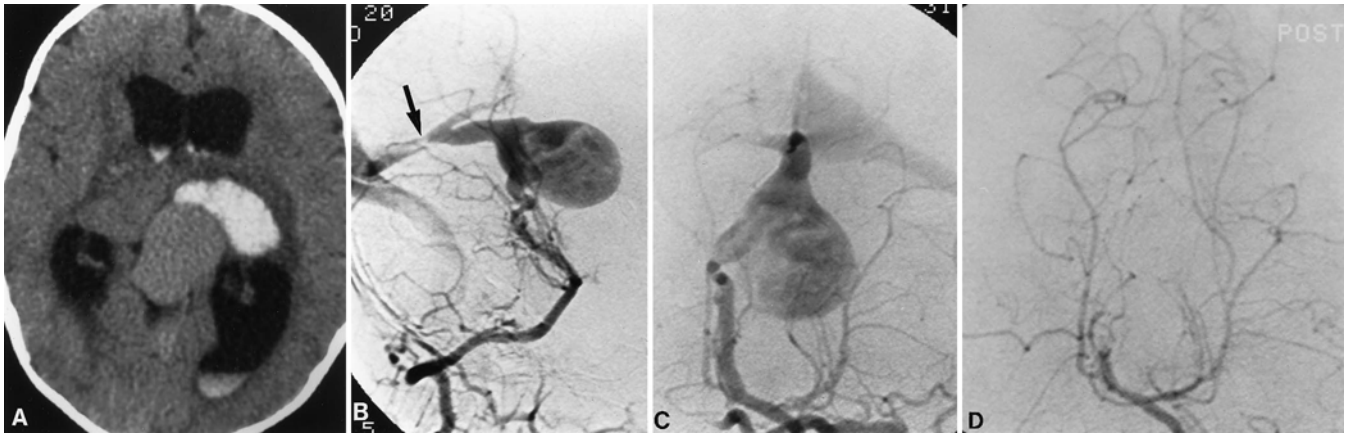


FIG. 2. Case 3. A: Unenhanced CT scan demonstrating acute hemorrhage in the right thalamus and internal capsule with IVH. B and C: Left vertebral injection arteriograms, lateral (B) and anteroposterior (C) projections, demonstrating a mural-type VGM supplied by a single enlarged lateral posterior choroidal artery. A high-grade stenosis is present in the draining falcine sinus (*straight arrow*). D: Left vertebral arteriogram, Towne's projection, obtained after embolization with silk suture, demonstrating complete obliteration of the fistula site. Complete and persistent closure of the VGM was confirmed on a 12-month follow-up arteriogram.

2A) from a previously unsuspected VGM. Emergency endovascular treatment resulted in a complete cure in both children.

One child presented with a grand mal seizure and was noted to have bulging scalp veins, a loud intracranial bruit, and increasing head circumference. Angiographic studies demonstrated thrombosis of both transverse sinuses and diversion of flow into collateral scalp veins from the VGM.

All eight patients were evaluated by a pediatric cardiologist and all were believed to have mild cardiomegaly and mild or no overt cardiac failure.

Radiographic Features

Arterial Supply. The number of arterial connections ranged from one (Fig. 2B) to four. Two children harbored a solitary connection. In all eight patients the blood supply came from posterior choroidal vessels arising from the posterior cerebral artery (PCA) and in two patients additional supply arose from the superior cerebellar artery.

Venous Anatomy. The prosencephalic vein involved ranged in size from 12 to 60 mm, with a mean of 33 mm. A straight sinus was present in four patients and the veins drained through a falcine sinus in two. One patient had both a straight and falcine sinus. Six of the eight patients exhibited a downstream stenosis in the straight sinus (five cases) or both transverse sinuses (one case). Both patients who presented with hemorrhage had a severe stenosis involving the straight sinus (Fig. 2B), and one of these patients exhibited partial thrombosis of the prosencephalic vein.

Timing of Treatment

All eight patients underwent radiographic evaluation of the malformation before receiving definitive therapy. This included CT or MR examination, intraarterial digital subtraction angiography, and transfontanelle cerebral and cardiac ultrasound. The five patients who presented with in-

creasing head circumference were otherwise developmentally normal, and their initial radiographic evaluation failed to reveal any ominous findings. Therefore, the initial therapy was delayed 3, 4, 6, 6, and 13 months, respectively. One of these patients, Case 7, had new ischemic changes noted on serial MR images, suffered a seizure, and was treated at 6 months of age. The two patients who presented with hemorrhage were treated within 2 weeks of presentation. The last child presented with seizures, was noted to have thrombosis of both transverse sinuses and cortical reflux, and was treated immediately to eliminate the risk of hemorrhage.

Endovascular Treatment

All endovascular procedures were performed via a transarterial femoral access by using a No. 4 French diagnostic or guiding catheter that was placed through a No. 4 French femoral sheath and introduced by means of a micropuncture system. Systemic anticoagulation was achieved with the administration of a 70 U/kg bolus of porcine heparin sulfate with 35 U/kg given every hour thereafter. The response to the heparin boluses was monitored, and an activated clotting time was obtained before, during, and after administration of the heparin doses with the aid of a Hemochron machine.

Transarterial Embolization Technique

The guiding catheter was placed in the distal vertebral artery (VA), and a variable-stiffness microcatheter and microguidewire were navigated through the guiding catheter into the large-caliber feeding vessel just proximal to the vessel's entry into the dilated prosencephalic venous pouch. Radiopaque markers of a known diameter were placed on both sides of the skull before arteriographic studies were obtained to permit calculation of the magnification factor on each individual run and to allow precise measurement of the feeding vessel and varix. Once a desirable position in the distal feeding vessel was achieved and confirmed with selective arteriographic im-

Endovascular treatment of VGMs

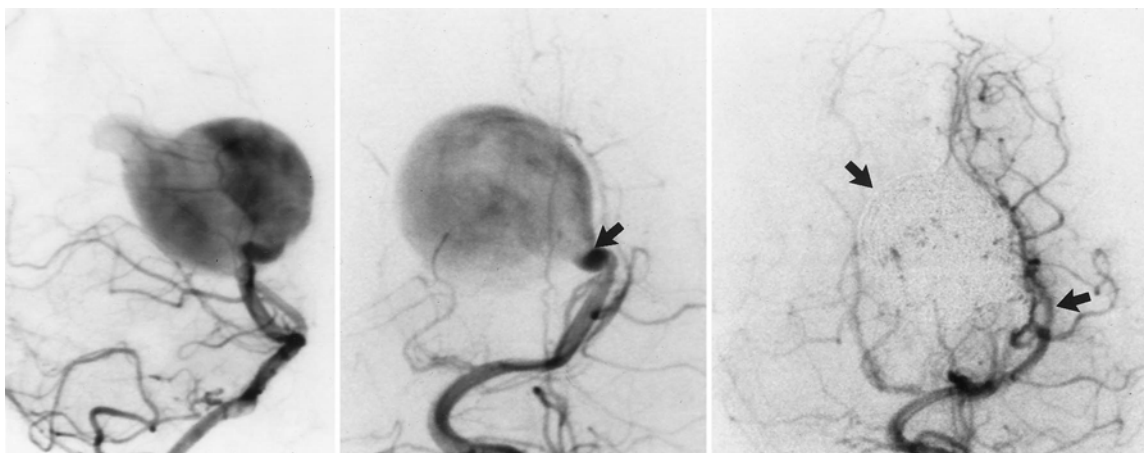


FIG. 3. Case 7. *Left and Center:* Left VA injection arteriograms, lateral projection (*left*) and Towne's projection (*center*), demonstrating a large vessel arising from the PCA communicating with the prosencephalic vein. A second smaller connection was demonstrated from the right PCA. The point of the fistula is localized by a *short straight arrow*. *Right:* Left VA injection arteriogram, Towne's projection, postembolization demonstrating complete closure of the fistula by means of multiple electrolytically detachable fibered and pushable platinum coils (*short straight arrows*) placed in the prosencephalic vein and left fistula.

ages, then embolization was performed using the following technique. Platinum fibered microcoils with a diameter slightly larger than the caliber of the distal feeding vessel were chosen. In the first two cases, additional embolization was performed with silk suture emboli to enhance the thrombogenicity of the platinum coils. In one case silk suture alone was used as an embolic agent. In the last four cases, advances in coil design permitted complete occlusion of the feeding vessels with no need for silk suture as an adjunct treatment. In the most recent case, a series of prototype fibered electrolytically detachable coils and standard electrolytically detachable coils were used for occlusion of the feeding vessels. In this last case coils were delivered via transarterial access into the prosencephalic vein and one of two feeding arterial vessels (Fig. 3 *right*).

When cessation of flow was observed in the pedicle of the feeding vessel, the embolization was terminated. The microcatheter and guiding catheters were withdrawn and the systemic anticoagulation was reversed by means of protamine sulfate administered slowly during a 10-minute period.

Transfemoral Transvenous Embolization Technique

In two patients the transarterial embolization attempt was unsuccessful, leading to incomplete obliteration of the malformation. In one patient a large arterial connection was obliterated by means of transarterial embolization techniques; however, the malformation was still supplied by a smaller connection that could not be accessed through an arterial route because of excessive tortuosity. In the second case the tortuosity precluded arterial access close to the malformation. Both patients were treated via a transfemoral venous access in the following fashion: a No. 4 French guide catheter was positioned in the dominant internal jugular vein, and through this a variable-stiffness microcatheter was navigated in a retrograde fashion through the torcula into the draining falcine or straight

sinus and into the prosencephalic vein draining the malformation. Customized fibered platinum coils matching the diameter of the prosencephalic vein were delivered with the aid of a coil-pushing wire. Sequentially smaller fibered coils were delivered into the prosencephalic vein until thrombosis of the varix was achieved.

Transtorcular Embolization Technique

In a single case, transarterial embolization resulted in occlusion of the dominant supply to the malformation, but a smaller second feeding vessel could not be accessed via this route. This infant suffered occlusion of both transverse sinuses that could not be accessed via a transfemoral venous approach. Therefore, assisted by a team of pediatric neurosurgeons, we placed a catheter via a transtorcular approach and delivered electrolytically detachable nonfibered platinum coils into the venous pouch, producing complete thrombosis of the malformation.

Sources of Supplies and Equipment

The No. 4 French guiding catheters were purchased from Cordis Corp., Miami Lakes, FL, and Medtronic MIS, Sunnyvale, CA, and the femoral sheaths were obtained from Cordis Corp. The No. 4 French diagnostic catheters and micropuncture system were acquired from Cook, Inc., Bloomington, IN. The heparin sulfate was purchased from Elkins-Sinn, Inc., Cherry Hill, NJ. The clotting time was measured with a Hemochron machine obtained from International Techidyne, Edison, NJ. The microcatheters (Tracker model) were purchased from Target Therapeutics, Fremont, CA. The microguidewires (Rapid Transit model) were obtained from Cordis Corp. Fibered microcoils were acquired from Cook, Inc., and Target Therapeutics. Prototype fibered and standard electrolytically detachable coils were purchased from Target Therapeutics. The coil-pushing wire was obtained from Terumo Inc., Boston Scientific, Watertown, MA.

Results

Eleven endovascular procedures were performed in eight patients in whom mural-type VGMs were diagnosed. Complete angiographically confirmed closure was documented in seven patients on postembolization angiograms, and subsequent CT and MR examinations revealed thrombosis and shrinkage of the varix in six cases. In a single case of a 60-mm prosencephalic vein treated by using both transarterial and transvenous techniques, stagnant flow was noted on the postembolization arteriogram. A follow-up arteriogram has not yet been obtained, but 37 months later the child remains neurologically intact on clinical examination.

Four children underwent follow-up arteriographic evaluation (range 11–24 months postprocedure) in which complete closure of their malformation was confirmed. Three children have not yet undergone follow-up arteriographic examination. The parents of one child refused the late follow-up arteriographic study; however, serial delayed CT scans have shown thrombosis and shrinkage of the varix. The child remains free of symptoms.

The patients in Cases 2 and 3, both of whom required numerous silk suture emboli to achieve closure of the malformation, developed postprocedure fevers as high as 39°C that lasted several days and abated spontaneously. Complete workups including blood and urine cultures, chest radiographs, and cerebrospinal fluid culture in one patient proved negative for infection. Our experience with silk suture embolization in other patients has shown us that transient postprocedure fevers related to the use of this agent are quite common. After the development of more thrombogenic platinum coils, we did not have to use silk suture as an embolic material in the last five patients.

Two children underwent VP shunt placement at 1 and 14 months before endovascular treatment. Thirteen months after successful endovascular treatment, one child developed a malfunction in a shunt placed at birth that was revised, resulting in resolution of his symptoms. All eight patients showed stabilization of their head circumference, and none required delayed VP shunt placement.

The child who presented at birth with seizures and a large IVH is developmentally delayed at 2 years of age. Another child, who had a parenchymal hemorrhage, initially presented with a dense hemiparesis and has only a mild residual leg weakness and mild restriction of upward gaze 84 months posttreatment. The remaining six children are intellectually and developmentally normal. The clinical follow-up period ranged from 3 to 105 months (mean 52 months).

Operative Complications

There were two asymptomatic complications. In one patient, the distal catheter became detached in the distal VA during delivery of a long prototype coil. An endovascular snare wire (Cook Inc.) was used to remove the coil and distal catheter with no difficulty. In the second patient, a single 3-mm coil passed through the prosencephalic vein and lodged in a peripheral pulmonary vein, producing no symptoms. He remains free of symptoms at 101 months of follow up.

Illustrative Cases

Case 1

This infant was noted to have an enlarging head circumference and progressive intermittent Parinaud's syndrome at 8 weeks of age. At 1 month of age an MR examination revealed a VGM. On subsequent arteriographic studies (Fig. 1A and B) two large-caliber connections between the posterior choroidal vessels and the midline dilated prosencephalic vein were confirmed. Because the child was developing normally and showed no signs of congestive heart failure we elected to delay therapy until the age of 5 months. At that time, a microcatheter was navigated to the largest fistula site via a transarterial access (Fig. 1C) and several fibered platinum coils followed by pieces of silk suture were delivered to the fistula site, producing complete closure of this connection (Fig. 1D). A single coil migrated through the fistula at the time of embolization and lodged in a lower lobe pulmonary arterial branch, producing no symptoms. The infant did well clinically with stabilization of his head circumference and resolution of the Parinaud's syndrome. A second embolization was performed at 11 months of age in which small fibered coils were used to occlude the remaining smaller fistulous connections. We confirmed complete closure of the malformation on a postembolization arteriogram and a follow-up arteriogram obtained at 14 months (Fig. 1E). The child has developed normally and at the age of 8 years remains neurologically intact with no symptoms.

Case 3

This healthy infant developed seizures and an acute hemiparesis at 5 months of age. A CT scan revealed a parenchymal hemorrhage (Fig. 2A) into the left thalamus and internal capsule secondary to a VGM. A mural-type VGM with a severe stenosis in the draining straight sinus (Fig. 2B and C) was demonstrated on arteriographic studies. During advancement of a prototype coil, the distal catheter became detached when the coil was in the distal VA and, therefore, a snare was used to remove it, which was accomplished without difficulty. A second microcatheter was advanced to the fistula site and silk suture was used for embolization until complete thrombosis was observed (Fig. 2D). Complete thrombosis of the prosencephalic vein and resolution of the hydrocephalus were revealed on subsequent MR images. A follow-up arteriogram obtained 15 months later confirmed complete closure of the fistula site. The child has shown gradual neurological improvement since the hemorrhage and has a mild hemiparesis and slight restriction of upward gaze 84 months posttreatment.

Case 7

This 6-month-old boy was diagnosed in utero as having a VGM. He was born prematurely and was hospitalized with failure to thrive but had no cardiac symptoms. He was noted to have increasing head circumference and mild, intermittent Parinaud's syndrome. Serial MR images revealed new ischemic changes at 6 months of age. The infant underwent arteriographic studies, in which two separate fistula connections with the prosencephalic vein

Endovascular treatment of VGMs

were identified (Fig. 3 left). The smaller connection arose from a fetal PCA that was extremely tortuous. Via a transarterial approach, a microcatheter was navigated through the left-sided connection into a dilated 36-mm prosencephalic vein. Electrolytically detachable coils were delivered into the varix initially followed by fibered platinum coils for a total of 50 coils. Electrolytically detachable fibered and nonfibered coils were deposited into the arterial connection just proximal to the fistula and just distal to normal PCA branches (Fig. 3 center). A control post-embolization arteriogram revealed closure of the fistula (Fig. 3 right). The child continues to progress normally.

Discussion

Vein of Galen malformation is a rare condition that almost exclusively affects children. The nomenclature is somewhat imprecise because the abnormal arterial connections are made with the median vein of the prosencephalon, an embryological precursor of the vein of Galen.² The clinical presentation can range from severe high-output congestive heart failure to seizures, macrocephaly, and mental retardation.^{1,2,10,11,15} Lasjaunias and colleagues^{2,11,12} have proposed that VGMs be subdivided into two distinct categories: choroidal and mural types, based primarily on their angioarchitecture. Choroidal VGMs classically demonstrate an abundance of bilateral arterial supply from choroidal arteries, pericallosal arteries, and/or subependymal branches of the thalamoperforating vessels. The connection is extracerebral and subarachnoid, communicating with the anterior aspect of the median vein of the prosencephalon. The choroidal type is more common and typically presents with heart failure in the neonate.^{2,11,12}

Mural-type VGMs harbor a lesser number of connections arising from the collicular or posterior choroidal artery branches, which may be unilateral or bilateral. Patients with mural-type VGMs typically present with macrocephaly or failure to thrive, and cardiac failure is typically mild or absent.^{2,11,12}

Although it was suggested in the earliest reports that VGM had a propensity to produce intracranial hemorrhage, this has recently been challenged. Berenstein and Lasjaunias² (widely regarded to have the most experience in endovascular treatment of VGMs) have not observed hemorrhage in their respective series. They suggest that many of the patients who have been reported to have suffered a hemorrhage from a VGM actually harbor a parenchymal arteriovenous malformation that drains to the vein of Galen, producing dilation of this structure. It is important to note that two patients (25%) in this series presented with bleeding and that both of them had severe downstream stenosis of the draining straight sinus (Fig. 2B).

Lasjaunias, et al.,¹¹ reported on the treatment of 43 children with VGMs, of whom 16 (37%) had the mural type. Two of these mural-type malformations spontaneously thrombosed, and the remaining 14 children were treated in 18 treatment sessions. Nine (64%) were completely cured. Of two reported deaths, one resulted from multiorgan failure and one patient was completely cured by embolization but died as a result of improper therapeutic timing and management.¹¹ Lasjaunias stressed the importance of bucrylate embolization via a transarterial route.

Our results in seven mural-type VGMs show a complete cure in all seven after treatment via both a transarterial and transvenous approach. We agree that the transarterial route is preferable and only use a transvenous approach when treatment via the first route is unsuccessful. This series is unique in that we use fibered and nonfibered platinum coils (in conjunction with silk suture early in the series) rather than liquid adhesives. The improvements in coil design including denser packing ability, more thrombogenicity, and the ability to reposition detachable fibered platinum microcoils have obviated the need for silk suture as an adjunct. We believe that the greater accuracy of fibered coils, as well as the ability to position them via both transarterial and transvenous routes, makes them a superior choice as an embolic agent in the treatment of VGMs. Others have reported success with the transarterial^{4,15} and transvenous^{3-5,15,17} deposition of coils in this condition; nonetheless, in experienced hands, liquid adhesives such as bucrylate have also shown considerable success in treating this disease.^{2,7,11-14}

It is important to note that high morbidity and mortality rates are associated with VGMs and that the morbidity rate is strongly dependent on the age at presentation. Johnston and colleagues¹⁰ reviewed the records of the 232 patients reported on who had this condition. These pooled data showed an overall mortality rate of 56% for both treated and untreated patients. The highest mortality rate (91.4%) was found in neonates and was equally high in those treated surgically or medically. Vein of Galen malformations present less commonly during infancy. However, patients treated surgically still had a 32% mortality rate, and significant levels of morbidity were seen in half of the survivors. Significant advances in surgical techniques have improved these results in the past 10 years.^{16,18} However, the greatest reduction in morbidity and mortality rates associated with this disease has been in patients treated using endovascular techniques.^{2,3-7,11-15,17}

The timing of the first embolization procedure depends on the presenting symptoms. The two children who presented with intracranial hemorrhage were treated on an emergency basis with complete closure of the VGM. The remaining children presented with less catastrophic signs and symptoms, usually consisting of increasing head circumference and hydrocephalus, which allowed definitive treatment to be delayed several months until the risks of angiography, contrast load, and embolization were reduced. However, if the initial angiographic examination disclosed cortical venous reflux or a high-grade stenosis in the draining straight or falcine sinus, this indicated a higher risk for subsequent hemorrhage.

Conclusions

Mural-type VGMs classically present in infancy with macrocephaly, seizures, and, less commonly, hemorrhage. These recalcitrant lesions can be cured by using a variety of embolization techniques. In this series, we achieved complete angiographically confirmed cure with no morbidity or mortality in all eight patients treated by means of platinum coils and/or silk suture emboli placed via both arterial and venous approaches.

References

1. Amacher AL, Shillito J Jr: The syndromes and surgical treatment of aneurysms of the great vein of Galen. **J Neurosurg** **39**: 89–97, 1973
2. Berenstein A, Lasjaunias P: **Arteriovenous Fistulas of the Brain in Surgical Neurangiography**. Berlin: Springer-Verlag, 1992, pp 267–317
3. Casasco A, Lylyk P, Hodes JE, et al: Percutaneous transvenous catheterization and embolization of vein of Galen aneurysms. **Neurosurgery** **28**:260–266, 1991
4. Ciricillo SF, Edwards MSB, Schmidt KG, et al: Interventional neuroradiological management of vein of Galen malformations in the neonate. **Neurosurgery** **27**:22–29, 1990
5. Dowd CF, Halbach VV, Barnwell SL, et al: Transfemoral venous embolization of vein of Galen malformations. **AJNR** **11**: 643–648, 1990
6. Edwards MSB, Hieshima GB, Higashida RT, et al: Management of vein of Galen malformations in the neonate. **Intervent Pediatr** **3**:184–188, 1988
7. Friedman DM, Madrid M, Berenstein A, et al: Neonatal vein of Galen malformations: experience in developing a multidisciplinary approach using an embolization treatment protocol. **Clin Pediatr** **30**:621–629, 1991
8. Garcia-Monaco R, DeVictor D, Mann C, et al: Congestive cardiac manifestations from cerebrocranial arteriovenous shunts. Endovascular management in 30 children. **Childs Nerv Syst** **7**:48–52, 1991
9. Hoffman HJ, Chuang S, Hendrick EB, et al: Aneurysms of the vein of Galen. Experience at The Hospital for Sick Children, Toronto. **J Neurosurg** **57**:316–322, 1982
10. Johnston IH, Whittle IR, Besser M, et al: Vein of Galen malformation: diagnosis and management. **Neurosurgery** **20**: 747–758, 1987
11. Lasjaunias P, Garcia-Monaco R, Rodesch G, et al: Vein of Galen malformation. Endovascular management of 43 cases. **Childs Nerv Syst** **7**:360–367, 1991
12. Lasjaunias P, Rodesch G, Pruvost P, et al: Treatment of vein of Galen aneurysmal malformation. **J Neurosurg** **70**:746–750, 1989
13. Lasjaunias P, Rodesch G, Terbrugge K, et al: Vein of Galen aneurysmal malformations. Report of 36 cases managed between 1982 and 1988. **Acta Neurochir** **99**:26–37, 1989
14. Lasjaunias P, Ter Brugge K, Lopez Ibor L, et al: The role of dural anomalies in vein of Galen aneurysms: report of six cases and review of the literature. **AJNR** **8**:185–192, 1987
15. Lylyk P, Viñuela F, Dion JE, et al: Therapeutic alternatives for vein of Galen vascular malformations. **J Neurosurg** **78**: 438–445, 1993
16. Matjasko J, Robinson W, Eudaily D: Successful surgical and anesthetic management of vein of Galen aneurysm in a neonate in congestive heart failure. **Neurosurgery** **22**:908–910, 1988
17. Mickle JP, Quisling RG: The transtorcular embolization of vein of Galen aneurysms. **J Neurosurg** **64**:731–735, 1986
18. Morgan MK, Johnston IH, Sundt TM Jr: Normal perfusion pressure breakthrough complicating surgery for the vein of Galen malformation: report of three cases. **Neurosurgery** **24**: 406–410, 1989

Manuscript received July 9, 1997.

Accepted in final form February 23, 1998.

Address reprint requests to: Van V. Halbach, M.D., Department of Radiology, Neurointerventional Section, University of California at San Francisco, 505 Parnassus Avenue, Room L352, San Francisco, California 94143-0628.