

SHORT REPORT

Intracranial haemodynamics during attenuated responses to electroconvulsive therapy in the presence of an intracerebral aneurysm

A Viguera, G Rordorf, R Schouten, C Welch, L J Drop

Abstract

Objectives—This report describes successful anaesthesia and electroconvulsive therapy (ECT) in a patient with an unruptured basilar artery aneurysm. ECT is associated with a hyperdynamic state characterised by arterial hypertension, tachycardia, and considerably increased cerebral blood flow rate and velocity. These responses pose an increased risk for subarachnoid haemorrhage when an intracranial aneurysm coexists.

Methods—A 54 year old woman presented for ECT. She had a 20 year history of major depression which was unresponsive to three different antidepressant drugs. There was also an unruptured 5 mm saccular aneurysm at the basilar tip, which had been documented by cerebral angiography, but its size had remained unchanged for the previous four years. After she declined surgical intervention, she gave informed consent for ECT. During a series of seven ECT sessions middle cerebral artery flow velocity was recorded by a pulsed transcranial Doppler ultrasonography system. She was pretreated with 50 mg oral atenolol daily, continuing up to the day of the last ECT and immediately before each treatment, sodium nitroprusside was infused at a rate of 30 µg/min, to reduce systolic arterial pressure to 90–95 mm Hg.

Results—Systolic flow velocity during the awake state ranged from 62–75 cm/s, remaining initially unchanged with sodium nitroprusside infusion. After induction of anaesthesia (0.5 mg/kg methohexitone and 0.9 mg/kg succinylcholine), flow velocities decreased to 39–54 cm/s, reaching maximal values of 90 cm/s (only 20% above baseline) after ECT. These flow velocities recorded post-ECT were considerably below the more than twofold increase recorded when no attenuating drugs were used. Systolic arterial blood pressure reached maximal values of 110–140 mm Hg and heart rate did not exceed 66 bpm. Rapid awakening followed each treatment, no focal or global

neurological signs were apparent, and the patient was discharged in remission.

Conclusion—In a patient with major depression and a coexisting intracerebral saccular aneurysm who was treated with ECT, the combination of β blockade with atenolol and intravenous infusion of sodium nitroprusside prevented tachycardia and hypertension, and greatly attenuated the expected increase in flow velocity in the middle cerebral artery.

(J Neurol Neurosurg Psychiatry 1998;64:802-805)

Keywords: electroconvulsive therapy; blood pressure; hypertension; blood vessels; aneurysm

The two principal therapeutic options for major depression are antidepressant drugs and electroconvulsive therapy (ECT). The current standard practice offers ECT to patients with disabling depressive symptoms or with life threatening depression and urgent need for intervention. In view of an ECT related hyperdynamic state with large increases in cerebral blood flow rate^{1,2} and velocity,³ and arterial hypertension,⁴ the risk of major intracerebral complications is high when an intracranial aneurysm coexists.^{5,6} Case reports are not available showing intracranial haemodynamics during ECT with the use of attenuating drugs.

In a patient with a known 5 mm intracranial aneurysm at the basilar tip we closely monitored arterial pressure and middle cerebral artery (MCA) flow velocity by transcranial Doppler sonography before, during, and after ECT when attenuating drugs were administered. β adrenergic blockade was produced with oral atenolol and intravenous sodium nitroprusside was used to manage the anticipated arterial hypertension.

Case report

A 54 year old woman with a 25 year history of major depression was admitted with recurrent unipolar illness of eight months in duration, which was unresponsive to antidepressants, including venlafaxine, lithium, and fluoxetine. Because a course of ECT had been successful 20 years earlier, she asked to be treated in the same manner. Of special interest was an unruptured intracranial aneurysm, the size of

Department of Psychiatry

A Viguera
R Schouten
C Welch

Department of Neurology

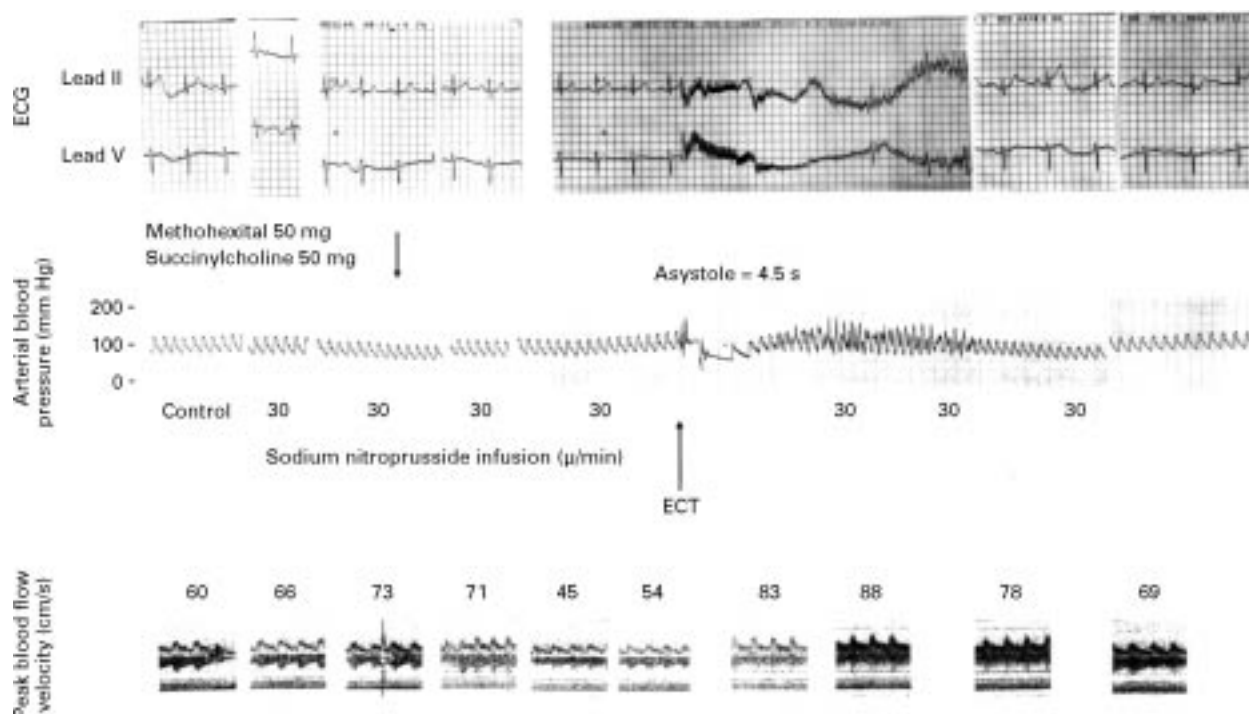
G Rordorf

Department of Anesthesia and Critical Care, Massachusetts General Hospital, and Departments of Anaesthesia, Psychiatry, and Neurology, Harvard Medical School, Boston, Massachusetts 02114, USA
L J Drop

Correspondence to:
Dr L J Drop, Department of Anesthesia, Massachusetts General Hospital, Boston Massachusetts 02114.
Telephone 001 617 724 3278; fax 001 617 726 7536; email drop@helix.mgh.harvard.edu

Received 13 May 1997 and in revised form 6 October 1997

Accepted 20 October 1997



Data obtained with invasive pressure monitoring. Shown in several sections, from left to right are data obtained in the patient awake at baseline, awake but after the start of sodium nitroprusside infusion, after induction of anaesthesia and muscular relaxation (indicated by arrows for methohexitane and succinylcholine), and after application of the ECT stimulus. At the top are ECG traces, below them, corresponding in time, traces of arterial pressure and middle cerebral artery flow velocity. The V lead of the ECG is in the V-5 position. The recording speed used for the arterial trace was 5 mm/s; that for the ECG was 25 mm/s. The last section shows data obtained after the sodium nitroprusside infusion was turned off.

which had not changed over the previous four years. There was no history of headache and no hypertension. She smoked a pack of cigarettes each day. Physical examination showed no focal neurological signs; current blood pressure readings were 110/70 mm Hg. An ECG showed a sinus rhythm of 88 beats/min. A complete blood count and coagulation profile were normal. A cerebral angiogram showed a 5 mm aneurysm at the basilar tip, but the patient firmly declined the surgical intervention recommended by the neurosurgical consultant. She was anxious to receive unilateral ECT, and gave informed consent.

To reduce the tachycardia and hypertension anticipated with ECT,^{4,7} the patient was pretreated with 50 mg atenolol orally a day; this treatment continued up to and including the day of the last ECT. During the two first ECT sessions, arterial pressure was continuously monitored from an indwelling radial artery catheter and recorded on a multichannel direct writing recorder via a calibrated pressure transducer. A long indwelling central venous cannula was inserted via an antecubital vein for accurately metered infusion of sodium nitroprusside. However, because of the risk of complications associated with multiple radial artery cannulations, we recorded non-invasive arterial pressure measurements (Dinamap, Criticon, Tampa, FL, USA) during the subsequent five treatments. For the same reason, central venous cannulation was not used after the second treatment and sodium nitroprusside was then administered via a large bore peripheral venous line. During the third and later treatments, non-invasive blood pressure meas-

urements and leads II and V5 of the ECG were recorded by a patient monitor (SpaceLabs, Redmond-Wash) and a microcomputer with customised software, allowing simultaneous real time display of all data at the bedside both in tabular and graphical formats (*v* time) and data storage. Systolic and mean middle cerebral artery blood flow velocities were measured intermittently with a pulsed 8 mHz Doppler ultrasound probe, which was anchored in a frame strapped on the head to allow a left temporal window at a depth of 40–50 mm from the surface. The emitting area of the transducer was about 10 times that of the cross sectional area of the middle cerebral artery in adults. The signal quality was adjusted according to the typical high pitch sound and the sonographic wave form. Measurements were recorded during the awake state at baseline, during the awake state but after the start of sodium nitroprusside infusion, after induction of anaesthesia, and continuously starting immediately before the application of ECT up until three minutes after the seizure. Because the patient was cooperative while awake and only slight movements of the feet were noted as evidence of a generalised seizure after anaesthesia and muscular paralysis, high fidelity recordings of middle cerebral artery blood flow velocity were obtained.

General anaesthesia was induced with methohexitane (0.75 mg/kg) and muscular paralysis was produced by succinylcholine (0.75 mg/kg), and these drug doses were constant for the series of treatments. The lungs were ventilated with 100% oxygen via a face mask at a rate of 8–10 breaths/min until

spontaneous breathing resumed. With the use of a face mask, end tidal CO₂ values could not be reliably measured. However, in the presence of an endotracheal tube, such manual ventilation may be expected to yield end tidal PCO₂ values ranging from 30–40 mm Hg. Immediately before each treatment sodium nitroprusside was infused by an adjustable infusion pump at a constant rate of 30 µg/min to lower systolic blood pressure from a range of 120–125 mm Hg to 90–95 mm Hg, a 20% change (figure). This vasodilator dose was constant during the series of treatments. Taking the absence of a foot sole reflex as evidence of adequate muscular relaxation, ECT was then administered by a unilateral brief pulse stimulus (average, 55 Ws) which was followed by a modified seizure averaging 40 seconds.

Middle cerebral artery flow velocity measurements together with an invasive pressure recording (figure) were representative for all treatments. In the awake state at baseline systolic blood flow velocity ranged from 62 to 75 cm/s; similar values were observed initially during sodium nitroprusside infusion. After induction of anaesthesia but immediately before ECT, systolic middle cerebral artery blood flow velocity decreased to 39–54 cm/s. After the application of the ECT stimulus peak middle cerebral artery flow velocities reached maximal values of 90 cm/s—that is, not more than 20% above baseline awake values. Immediately after ECT, systolic arterial blood pressure returned to control or only slightly above (range: 110–140 mm Hg); and heart rate did not exceed 66 bpm. Rapid awakening followed each treatment; no focal or global neurological signs were found at any time, and cranial nerve examination remained normal. The patient was discharged in remission after a series of seven treatments.

Discussion

Although the presence of a saccular aneurysm at the basilar tip posed an important risk for major cerebrovascular complications including aneurysm rupture and cerebral vasospasm, we successfully administered ECT to this patient who was unresponsive to three different antidepressant drugs. The intracranial haemodynamic consequences of ECT are unknown when hypertension and tachycardia are attenuated. Without attenuation, however, a previous study conducted in 92 patients has shown that ECT is associated with a more than twofold increase in middle cerebral artery blood flow velocity.³ Such a major increase may be explained by cerebral vascular narrowing caused by greatly increased plasma catecholamine concentrations, by electrical stimulation,⁸ or by increased cerebral blood flow rate,^{1,2} which occurs because of flow-metabolism coupling.⁹ The small increase in middle cerebral artery flow velocity (by only 20%) we consistently observed, therefore, was all the more striking. ECT is known to be associated with a hyperdynamic state, with tachycardia⁴ and increased systolic arterial pressure by 34%⁴ and a twofold increase in

cardiac output.⁷ Such hypertension is of major concern when an intracerebral aneurysm is present, as it causes increased wall stress in the aneurysm. However, although augmented wall stress may lead to aneurysm growth or rupture, and although arterial hypertension is recognised as a risk factor, a direct correlation between aneurysm rupture and acute hypertension is not established.¹⁰ Of a total of 250 postmortem examinations, hypertension was present in 37% when an intracranial aneurysm had ruptured, but in 43% when an intracerebral aneurysm was found incidentally.¹⁰ Nevertheless, because the risk of acute subarachnoid haemorrhage was real in this patient and its rate of growth unpredictable,¹¹ control of blood pressure and heart rate was sought. To reduce blood pressure and hold it steady, we selected sodium nitroprusside because of its short duration of onset and action. Its potent cerebral vasodilator properties may explain the small changes in middle cerebral artery flow velocity despite increased blood flow rate^{1,2} and vascular narrowing⁸ expected with increased blood catecholamine concentrations. In addition, systemic pressure changes were small and pretreatment with atenolol by mouth resulted in minimal changes in heart rate. It is recognised that in the current patient no hypertension was present before ECT and therefore, that the drug regimen instituted and the successful outcome we found may not apply to all patients with intracranial aneurysms presenting for ECT.

This case report raises two principal questions. Firstly, what conditions predict intracranial aneurysm rupture? The answer is that predictors are unreliable. Studies in patients with asymptomatic aneurysms have established bleeding rates of 2.0%¹² and 1.5% a year.¹³ Risk factors include cigarette smoking, use of oral contraceptives, and possibly chronic hypertension. Aneurysm size (smaller $v > 10$ mm in diameter) is also a risk factor for bleeding.¹⁴ Although no bleeding occurred in 102 patients with intracranial aneurysms with diameters < 10 mm,¹⁴ small asymptomatic aneurysms may bleed.¹¹ Aneurysm enlargement is a strong predictor for rupture.¹⁵

Secondly, what mechanisms are involved in aneurysm rupture? The answer is elusive. It is well established that wall stress in an aneurysm is augmented by increased blood pressure. However, Weir¹⁶ proposed that development or growth of a saccular aneurysm may be related to disintegration or focal weakness of the elastic layer secondary to ceaseless pounding of the arterial pulse wave. Such a mechanism may explain the location of saccular aneurysms at the apices of vascular bifurcations, where structural fatigue may be produced by the dissipation of kinetic energy or turbulence, which develops with excessive flow velocity.¹⁷ Thus flow velocity may be a determinant of stress at the site of the aneurysm.¹⁷ However, this case report shows that its anticipated sharp increase³ did not occur with a regimen of β blockade and sodium nitroprusside. Further study of intracranial and systemic

haemodynamics under conditions of hyperdynamic states and different attenuating drugs will be necessary to establish the safety of ECT in the presence of intracranial aneurysms.

We thank Mr Glen Pelikan from SpaceLabs (Redmond, Washington) for the use of the SpaceLabs PCEXpress patient monitor.

- 1 Plum F, Posner JB, Troy B. Cerebral metabolic and circulatory responses to induced convulsions in animals. *Arch Neurol* 1968;18:1–13.
- 2 Posner JB, Plum F. Cerebral metabolism during electrically induced seizures in man. *Arch Neurol* 1969;20:388–95.
- 3 Saito S, Yoshikawa D, Nishihara F, et al. The cerebral hemodynamic response to electrically induced seizures in man. *Brain Res* 1995;673:93–100.
- 4 Castelli I, Steiner LA, Kaufmann MA, et al. Comparative effects of esmolol and labetalol to attenuate hyperdynamic states after electroconvulsive therapy. *Anesth Analg* 1995;80:557–61.
- 5 Fink M. *Convulsive therapy. Theory and practice*. New York: Raven Press, 1979:219.
- 6 Task Force Report of the Am Psychiatric Association. *The practice of electroconvulsive therapy. Recommendations for treatment, training and privileging*. Washington, DC: American Psychiatric Association, 1990:58.
- 7 Wells DG, Davies CG. Hemodynamic changes associated with electroconvulsive therapy. *Anesth Analg* 1987;66:1193–5.
- 8 Johansson B, Somlyo A. Electrophysiology and excitation-contraction coupling. In: Geiger S, ed. *Handbook of physiology. The cardiovascular system*. Vol 2. *Vascular smooth muscle*. Bethesda: American Physiological Society, 1980:301–23.
- 9 Plum F, Duffy TE. The couple between cerebral metabolism and blood flow during seizures. In: Ingvar DH, Lassen NA, eds. *Brain work*. Copenhagen: Munksgaard, 1975:197–214.
- 10 McCormick WF, Schmalstieg EJ. The relationship of arterial hypertension to intracranial aneurysms. *Arch Neurol* 1977;34:285–7.
- 11 Schievink WI, Piepgras DG, Wirth FP. Rupture of previously documented small asymptomatic saccular intracranial aneurysms. Report of three cases. *J Neurosurg* 1992;76:1019–24.
- 12 Rosenkorn J, Eskesen V, Schmidt K. Unruptured intracranial aneurysms. An assessment of the annual risk of rupture based on epidemiological and clinical data. *Br J Neurosurg* 1988;2:369–78.
- 13 Wiebers DO, Whisnant JP, O'Fallon WM. The natural history of unruptured intracranial saccular aneurysms. *N Engl J Med* 1981;304:696–8.
- 14 Wiebers DO, Whisnant JP, Sundt TM, et al. The significance of unruptured intracranial saccular aneurysms. *J Neurosurg* 1987;66:23–9.
- 15 Zack DJ, Russell DB, Miller DR. Fortuitously discovered intracranial aneurysms. *Arch Neurol* 1980;37:37–41.
- 16 Weir B. *Aneurysms affecting the nervous system*. Baltimore: Williams and Wilkins 1987:671–92.
- 17 Sekhar LN, Heros RC. Origin, growth and rupture of aneurysms: a review. *Neurosurgery* 1981;8:248–60.

HISTORICAL NOTE

Schroeder van der Kolk: the soul and epilepsy

Jacobus Schroeder van der Kolk (1797–1862)¹ showed his intellectual abilities when a student at Groningen. He became Professor of Anatomy and Physiology at Utrecht in 1826. More than 100 scientific contributions followed. They were devoted to the management of the mentally ill in asylums to which he had devoted his labours, clinical studies of neurology, lung diseases, blood disorders, embryology, zoology and later in his life he considered philosophical issues of the nature of the soul. His major work was entitled *Body and Soul* in which he described psychic processes and material disorders as the outcome of a higher spirit (*spiritus animalis*).

His writings, evolved from primitive Galenic ideas, have to be seen in their historical context; but throughout he emphasised the miraculous aspects of natural history, and of life itself. He initiated investigations of the causes of disease using morbid anatomy, publishing an important work *Anatomy of the Cord and Medulla*.

Van der Kolk performed autopsies and used a primitive microscope on the brains of epileptics. His conclusions were given in the Sydenham Lecture of 1859, *On the minute structure and functions of the medulla oblongata and the proximate causes and rational treatment of*

epilepsy. He found “dilatation of the veins which appeared filled with blood in the cortex, medulla and spinal cord”. The medulla “showed a fatty degeneration with albuminous intracellular fluid.” Those who bit their tongues during a fit had dilated vessels feeding the hypoglossal nucleus whereas those without a bitten tongue had dilated vessels of the vagal nucleus.

“The first cause of epilepsy . . . is exalted sensibility and excitability of the medulla oblongata. . . .” These caused the medulla to be “liable to discharge upon itself” and these discharges caused spasms in blood vessels leading to hyperaemia followed by involuntary reflex movements” Frequent or repeated fits caused inflammation of the cortex leading to “incurable dementia” due to “thickening and dilatation of blood vessels.”²

This problem of the prime seat of the epileptic fit was a major source of controversy.^{3,4} The distinguished American neurologist Hammond cited van der Kolk’s work in his *A treatise on the diseases of the nervous system* (1871), and claimed “no one has been more thorough in the search for the essential cause of epilepsy than he.”

continued on page 812