

Benjamin B. Fulmer^a
Stephanie C. Dillard^b
Elizabeth M. Musulman^c
Cheryl A. Palmer^b
Jerry Oakes^a

^a Division of Neurosurgery, and

^b Department of Pathology, University of Alabama at Birmingham,

^c Department of Pathology, The Children's Hospital of Alabama, Birmingham, Ala., USA

Two Cases of Cerebral Aneurysms in HIV+ Children

Abstract

Two cases of fusiform cerebral aneurysms in human immunodeficiency virus (HIV) positive children are presented. To our knowledge, only 9 patients with this association have been reported. One of our patients represents the first report of a patient with an aneurysm associated with varicella-zoster vasculitis. One patient presented with a subarachnoid hemorrhage, Hunt-Hess grade IV, and posed difficult surgical management. The other patient suffered a cerebral infarct with a resulting hemiparesis. The first patient had a ventriculostomy placed, initially improved, and subsequently died from rebleeding. The second patient improved with medical management. AIDS arteriopathy, and specifically fusiform aneurysms, are being increasingly reported. The various presentations of this surgically challenging entity in light of other AIDS-related syndromes pose difficult management decisions. On occasion, the intracranial aneurysm may be the initial form of presentation as was present in our first patient.

Key Words

AIDS
Aneurysm, fusiform
HIV, pediatric

Introduction

Various types of cerebrovascular arteriopathy are increasingly being described in the acquired immunodeficiency syndrome (AIDS) patient population. Pathologic findings include fibrosis, vasculitis, calcification and aneurysms, all of which may lead to cerebral infarction and/or hemorrhage. To this date, only 9 reported cases of children infected with the HIV virus who have been found to have intracerebral aneurysms were found in our search [1–6]. This type of patient poses difficult management issues, from both a medical and a surgical standpoint. Because of their rarity, this association may elude the diagnostician's differential diagnosis.

We present 2 cases of intracerebral aneurysms in HIV-positive children. In the 1st case, the patient presented with subarachnoid hemorrhage. In the 2nd, aneurysms

were found during the workup of cerebral infarction. In both cases, the circle of Willis was affected in multiple areas by fusiform aneurysmal dilatation.

Case Reports

Case 1

A 6 year-old female who was previously considered to be healthy presented with a 3-day history of cough, nausea, vomiting, and fever. One day prior to admission she complained of headache and was reported to have had a seizure. The morning of admission she became increasingly lethargic.

On physical examination the patient weighed 19.5 kg. Her pulse was 152/min, blood pressure was 99/57 mm Hg, and she was afebrile. She had been intubated. Her pupils were 6 mm and unreactive on the right and 5 mm and sluggishly reactive on the left. She had bilateral third nerve palsies and a symmetric grimace. She localized to painful stimuli briskly bilaterally. The remainder of the patient's physical

KARGER

Fax +41 61 306 12 34
E-Mail karger@karger.ch
www.karger.com

© 1998 S. Karger AG, Basel
1016–2291/98/0281–0031\$15.00/0

This article is also accessible online at:
<http://BioMedNet.com/karger>

W. Jerry Oakes, MD
The Children's Hospital of Alabama, 1600 7th Avenue South
Suite 400, ACC Building
Birmingham, AL 35233 (USA)
Tel. +1 205 939 9653, Fax +1 205 939 9972, E-Mail Jerry.Oakes@ccc.uab.edu

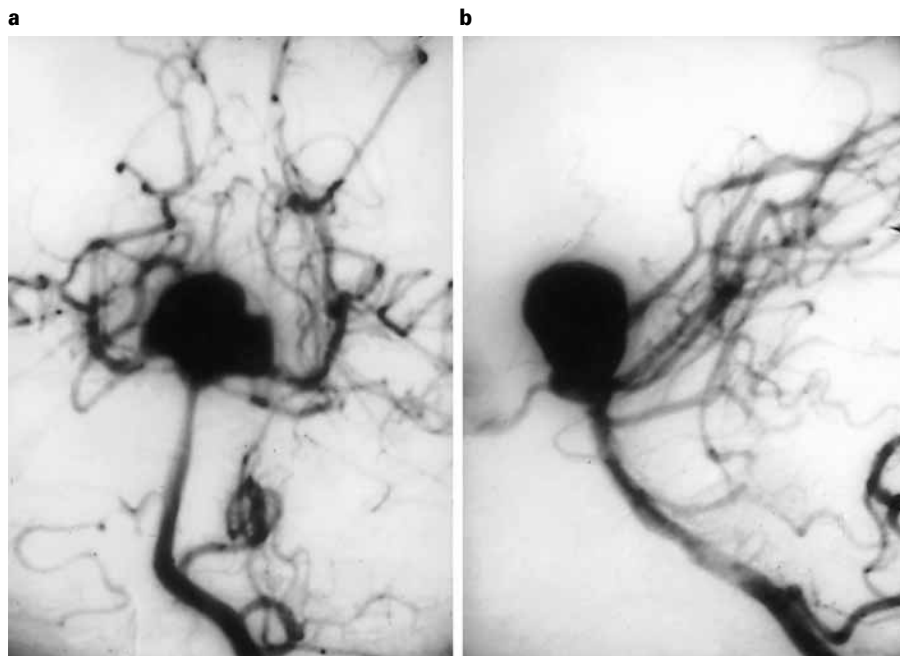


Fig. 1. A-P (a) and lateral (b) arteriogram of the posterior circulation in patient 1 revealing a large basilar tip aneurysm with fusiform dilatation of the trunk, bilateral superior cerebellar arteries and posterior cerebral arteries.

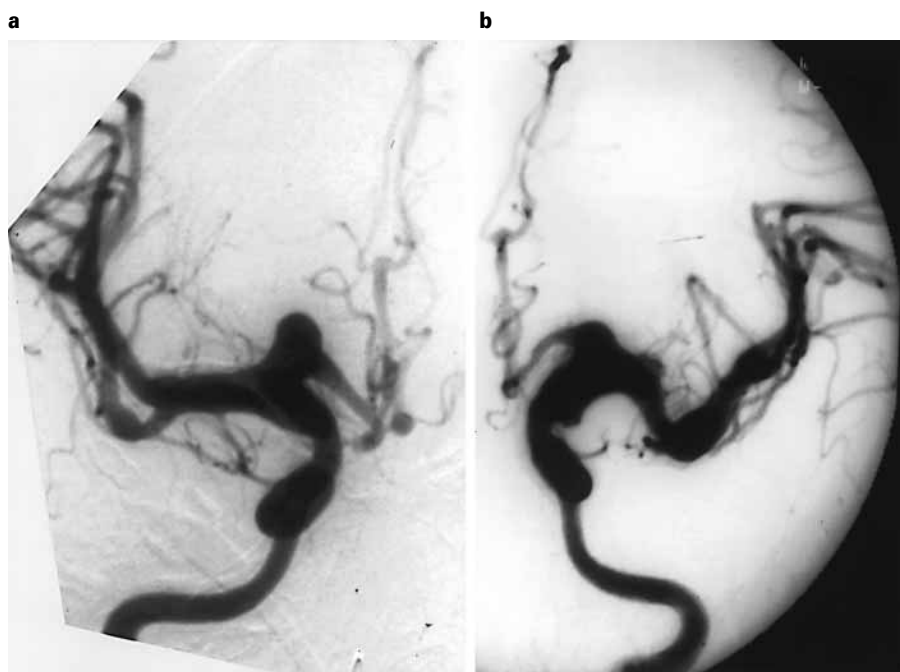


Fig. 2. AP arteriogram of the right (a) and left anterior (b) circulation in patient 1 revealing fusiform dilatation of the internal carotid, anterior cerebral arteries and middle cerebral arteries.

examination was unremarkable except for one left posterior cervical lymph node.

Computerized tomography (CT) of the head revealed bilateral subarachnoid hemorrhage (SAH) with moderate panventricular hemorrhage. She had acute hydrocephalus and a suspected basilar artery aneurysm.

This patient was therefore admitted with a Hunt-Hess grade IV SAH and a Fisher grade IV CT scan. The opening pressure from a ventriculostomy was 25 mm Hg. The next hospital day she followed commands but her third nerve persisted. An arteriogram was per-

formed which revealed a large basilar tip aneurysm with fusiform dilatation of the trunk, bilateral superior cerebellar arteries, and bilateral posterior cerebral arteries (fig. 1). The anterior circulation injections showed fusiform aneurysms of both internal carotid arteries including the middle cerebral arteries and anterior cerebral arteries (fig. 2).

The patient was vigorously hydrated, with a central venous pressure of 10 mm Hg. Intracranial pressure (ICP) was maintained in the normal range by ventriculostomy drainage, and the cerebral perfusion pressure was maintained at 70–80 mm Hg. Plans were being made for surgical intervention when suddenly on the 4th hospital day

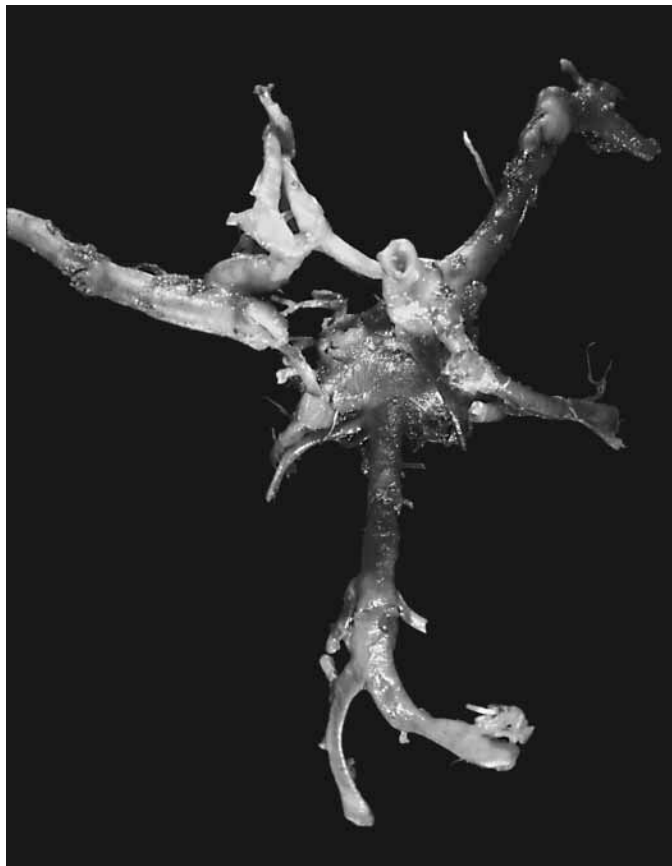

Fig. 3. Gross dissection of the circle of Willis, revealing fusiform dilatation in both the anterior and posterior circulation.

the ICP exceeded 100 mm Hg. The ventriculostomy expressed frank blood. CT revealed increased SAH with a casted ventricular system. Shortly thereafter, physical examination revealed brain death. Permission for an autopsy was obtained.

Just after this patient's second event, an HIV test was reported as positive. Subsequent testing of the mother found her also to be HIV+. The patient's mother denied any history of significant past illness.

Pathology. At autopsy, the brain was edematous, weighing 1,135 g. Diffuse subarachnoid hemorrhage was present bilaterally, most notably over the occipital and parietal lobes, extending to the undersurface of the brain encasing the circle of Willis. Coronal sectioning revealed extensive intraventricular hemorrhage with diffuse distension of the ventricular system with clotted blood. There was a 2.0-cm hematoma present in the midportion of the midbrain extending to involve the cephalad portion of the pons. Upon dissection of the circle of Willis, an aneurysm measuring $2.2 \times 2.1 \times 1.6$ cm was identified at the junction of the basilar arteries, and an area of rupture was present in the midline of the aneurysmic dome (fig. 3). In addition, bilateral aneurysmal dilatations were present involving the bifurcations of the internal carotid arteries with the anterior and middle cerebral arteries, with each dilatation measuring at least 0.6 cm in diameter.

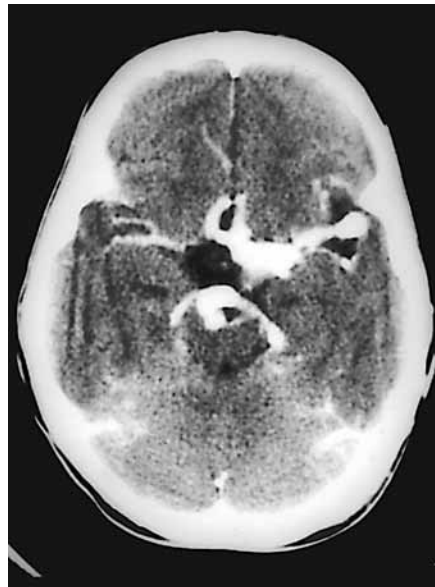


Fig. 4. Contrast-enhanced CT in patient 2 revealing fusiform dilatation of much of the circle of Willis.

Histologically, the brain parenchyma showed diffuse anoxia and multinucleated giant-cell HIV encephalitis. The dilated cerebral vessels contained intimal thickening with fibroblast proliferation and a lymphocytic infiltrate, medial thinning and rarefaction of the elastic lamina, all features similar to previously described HIV-associated pediatric cerebral aneurysms [1, 6–8]. Immunohistochemistry for HIV antigens was indeterminate, most likely due to fixation artifact. Immunohistochemical stains directed against varicella-zoster virus (VZV) showed staining of the dilated vessels as well as smaller vessels within the brain parenchyma. VZV-associated vasculopathies have been described in AIDS patients, with some lesions of so-called 'noninflammatory vasculopathy' demonstrating marked intimal proliferation which produces occlusion of the affected vessel and resulting infarction. Occlusion was not present in the current case, and aneurysms associated with VZV infection of the brain have not been described [6].

Case 2

An 11-year-old girl who was known to be HIV-positive had already been treated for associated illness including pulmonary *Mycobacterium avium intracellulare* pneumonia and cytomegalovirus. She presented to her primary physician with failure to thrive, fever and left-sided weakness one year after being found to be HIV+.

Physical examination revealed her to be small for her age (height and weight less than 5th percentile). Vital signs were normal. Neurologic examination revealed an awake, alert and fully oriented child with a mild left hemiparesis (4/5). Her speech and the remainder of her exam were grossly normal.

CT scan of the head with contrast revealed fusiform dilatation of many areas of her circle of Willis (fig. 4). She had no evidence of hemorrhage but did have a small basal ganglia/internal capsule infarction on the right.

The patient's hemiparesis nearly resolved over the next 2 months. She lived 3 more years without further neurologic deficit. Eventually she expired from other AIDS-related complications. An autopsy was not performed.

Discussion

AIDS arteriopathy is being increasingly recognized, and greater numbers of HIV-positive children are presenting with cerebrovascular accidents and/or hemorrhage. Fibrosis, calcification, aneurysms, emboli and vasculitis/vasculopathy have all been described in these patients [2, 3, 6, 9–11]. There is increasing evidence of direct involvement of HIV virus particles within the vessel walls [1, 2, 10–12]. One series of 380 pediatric patients who were HIV+ found the incidence of radiographically proven stroke to be just under 1% [9]. While subacute AIDS encephalitis is a well-recognized consequence of advanced disease [5], vascular involvement provides yet more insight into the aggressive, widespread nature of the virus.

As mentioned previously, we found only 9 reported cases of intracranial aneurysms in HIV-positive patients, all of whom were children [1–6]. There have been isolated reports of aneurysms outside of the cranium such as in the common carotid or the aorta [7].

Fusiform aneurysms are well known to pose difficult surgical management decisions. In case 1, surgical options

were being considered before the patient sustained a terminal rehemorrhage. In case 2, the aneurysms were never directly symptomatic, so neurosurgical consultation was never sought. Fusiform aneurysms are defined as dilatation and elongation of a blood vessel. They can bleed, cause cranial nerve deficits, or result in dissection and infarction [6, 8]. On occasion, they can often be treated by wrapping with various materials or reconstitution of the lumen by fenestrated clips. If the involved vessels' supply is tolerant, they may be trapped. Overall, these options are often unsatisfactory. In our 1st case, with extensive disease of the circle of Willis, there was no perfect answer.

Another remarkable feature of our 1st case is the VZV. CNS VZV vasculopathy in AIDS has only been described in one report of 4 patients [13] and two single patient reports [14, 15], none of whom were children. In these cases, marked intimal proliferation produced luminal occlusion, but an inflammatory vasculitis was not described. Occlusion was not present in our 1st case, and aneurysms associated with VZV infection have not been reported.

These 2 cases may prove to be illustrative of a clinical picture that will become more easily recognized. In the child that presents with fusiform aneurysmal involvement of the intracranial vessels, HIV-induced vasculopathy should be considered and may be the initial manifestation of clinical AIDS.

References

- 1 Kure K, Park Y, Kim T, Lyman W, Lanton G, Lee S, Cho S, Belman A, Weidenheim K, Dickson D: Immunohistochemical localization of an HIV epitope in cerebral aneurysmal arteriopathy in pediatric acquired immunodeficiency syndrome (AIDS). *Pediatr Pathol* 1989;9:655–667.
- 2 Lang C, Jacobi G, Kreuz W, Hacker H, Herrmann G, Keul H, Thomas E: Rapid development of giant aneurysm at the base of the brain in an 8-year-old boy with perinatal HIV infection. *Acta Histochem Suppl* 1992;42:83–90.
- 3 Moriarty D, Haller J, Loh J, Fikrig S: Cerebral infarction in pediatric acquired immunodeficiency syndrome. *Pediatr Radiol* 1994;24:611–612.
- 4 Park Y, Belman A, Kim T, Kure K, Llena J, Lantos G, Bernstein L, Dickson D: Stroke in pediatric acquired immunodeficiency syndrome. *Ann Neurol* 1990;28:303–311.
- 5 Phillippet P, Blanche S, Sebag G, Rodesch G, Griscelli C, Tardieu M: Stroke and cerebral infarcts in children infected with human immunodeficiency virus. *Arch Pediatr Adolesc Med* 1994;148:965–970.
- 6 Shah S, Zimmerman R, Rorke L, Vezina L: Cerebrovascular complications of HIV in children. *AJNR* 1996;17:1913–1917.
- 7 Sinzobahamvya N, Kalangu K, Hamel-Kalinowski W: Arterial aneurysms associated with human immunodeficiency virus (HIV) infection. *Acta Chir Belg* 1989;89:185–188.
- 8 Weir B: Aneurysms Affecting the Nervous System. Baltimore, Williams & Wilkins, 1987.
- 9 Friedman D, Rapoport R, Ketonen L, Kiebertz K, Jensen M, Brant-Zawadzki M: FORUM: Routine use of contrast-enhanced MR scans in AIDS (letter). *AJNR* 1993;14:1324–1328.
- 10 Joshi V, Pawel B, Connor E, Sharer L, Oleske J, Morrison S, Marin-Garcia J: Arteriopathy in children with acquired immune deficiency syndrome. *Pediatr Pathol* 1987;7:261–275.
- 11 Kiebertz K, Eskin T, Ketonen L, Tuite M: Opportunistic cerebral vasculopathy and stroke in patients with the acquired immunodeficiency syndrome. *Arch Neurol* 1993;50:430–432.
- 12 Bode H, Rudin C: Calcifying arteriopathy in the basal ganglia in human immunodeficiency virus infection. *Pediatr Radiol* 1995;25:72–73.
- 13 Gray F, Belec L, Leses MC, Chretien F, Ciardi A, Hassine D, Flament-Saillour M, de Truchis P, Clair B, Scaravilli F: Varicella-zoster virus infection of the central nervous system in the acquired immune deficiency syndrome. *Brain* 1994;117:987–999.
- 14 Eidelberg D, Sotrel A, Horoupian D, Neumann P, Pumarola-Sune T, Price R: Thrombotic cerebral vasculopathy associated with herpes zoster. *Ann Neurol* 1986;19:7–14.
- 15 Morgello S, Block G, Price R, Petito C: Varicella-zoster virus leukoencephalitis and cerebral vasculopathy. *Arch Pathol Lab Med* 1988;112:173–177.

Copyright: S. Karger AG, Basel 1998. Reproduced with the permission of S. Karger AG, Basel. Further reproduction or distribution (electronic or otherwise) is prohibited without permission from the copyright holder.