

Infarction in the territory of the anterior cerebral artery

Article abstract—Infarction in the anterior cerebral artery (ACA) territory is an uncommon cause of stroke. The clinical findings of ACA infarctions are not fully characterized but include contralateral hemiparesis, urinary incontinence, transcortical aphasia, agraphia, apraxia, and executive dysfunction. We report a patient with a large right ACA infarction, who in addition to previously reported findings also had a complete hemiplegia, profound sensory neglect, and micrographia.

NEUROLOGY 1998;51:620–622

Lisa A. Klatka, DO; Mark H. Depper, MD; and Ann M. Marini, MD, PhD

Infarction in the territory of the anterior cerebral artery (ACA) is uncommon, comprising 0.6% to 3% of cerebral infarctions.¹ The clinical findings of ACA infarctions are not clearly delineated. We report a patient who developed prominent neurobehavioral and motor deficits after a unilateral infarction involving the territory of the right ACA posterior to the anterior communicating artery.

Case report. An 82-year-old right-handed woman was admitted to the hospital for chest pain and shortness of breath. The day after admission, she was noted to have slurred speech, urinary incontinence, and weakness of the left side. Examination revealed a blood pressure of 146/80 mm Hg; heart rate was 76 bpm and regular. She was alert and fully oriented. Her head and eyes were deviated to the right. There was no spontaneous speech or motor activity and she was slow to respond to questioning. She was able to list all the months backwards. Speech was mildly dysarthric but fluent. Naming and repetition were intact; she was able to follow simple commands but not a three-step command. She was able to recall three items after 5 min-

utes without cuing. She displayed profound neglect on a line bisection task (figure 1A) and extinction to double simultaneous stimulation. On copying tasks, she tended to neglect the left side of the stimulus; the detail of the non-neglected half was impaired also (see figure 1, B and C). Clock drawing was also impaired (see figure 1D). There was perseveration on copying repetitive patterns (figure 2, A and B).

There was a dense left hemiplegia, with the arm and leg affected more than the face. On finger-to-nose testing, motor perseveration was evident. Deep tendon reflexes were increased in the left arm and leg, and a Babinski sign was present on the left.

Complete blood count, chemistries, and coagulation studies were normal. MRI scanning of the brain showed a subacute infarction in the region of the right ACA, including the parafalcine portions of the frontal and parietal lobes (figure 3). The most midline portions of the hemispheric surfaces of these lobes were also infarcted. The occipital lobe and the most anterior portion of the frontal lobe were spared. A small area of hyperintensity was seen in the anterior portion of the right internal capsule. This

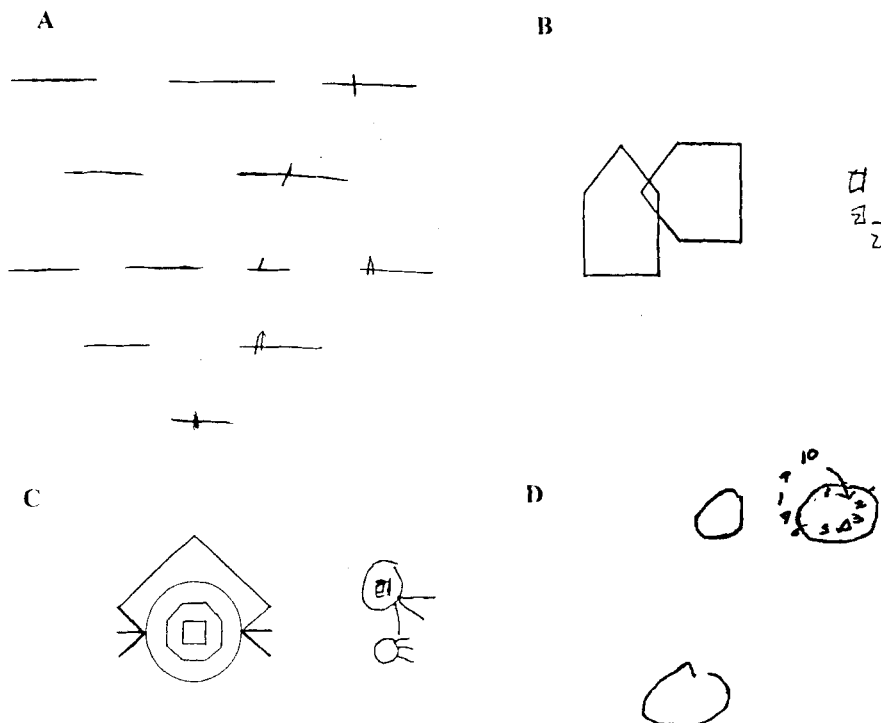


Figure 1. Line bisection task (A) and constructions (B and C) show severe neglect of the left side of the models. Clock-drawing task (D) is disorganized and demonstrates perseverative errors. Micrographia is seen in all drawings.




Figure 2. Alternating programs (A) and multiple loops (B). Samples and copies show perseverative errors and micrographia.

lesion was also seen on CT scanning on the day of the stroke and was thought to represent a remote lacunar infarction. The basal ganglia were not affected.

Discussion. The clinical spectrum of infarction in the territory of the ACA is variable. ACA infarctions vary in size and may involve different areas within the ACA territory. Branch occlusions of the ACA result in findings that depend on the location and extent of the infarction. When one ACA is occluded distal to the anterior communicating artery, the clinical syndrome usually consists of a sensorimotor deficit of the contralateral leg, with less involvement of the arm and sparing of the face.²⁻⁴ Bogousslavsky et al.¹ reported a hemiparesis in 26 of 27 patients with ACA infarctions, seven of whom had the face, arm, and leg involved equally and one in whom the leg was spared entirely. Our patient had a complete left hemiplegia, however. Hemiplegia usually indicates bilateral ACA infarction.⁵ A definitive explanation for the profound hemiplegia is lacking but the infarction included the premotor area of the cortex, which has been shown to predominantly affect the proximal and trunk musculature; usually, a limb-kinetic

apraxia is present also.⁶ The finding of executive dysfunction also correlates with premotor involvement.¹ It is possible that the hemiplegia results from the new infarction in the premotor area, along with a limb-kinetic apraxia in conjunction with the old infarction of the anterior limb of the internal capsule.

Infarctions in the ACA distribution include disorders of motivation, language, praxis, executive function, and spatial distribution of attention. Abulia or apathy has been reported in both right-sided and left-sided infarctions.¹ Aphasia, agraphia, and apraxia have all been associated with a lesion affecting the supplementary motor area.⁷ Micrographia has not been previously reported in ACA infarction. Marsden⁸ suggested that the basal ganglia directs premotor cortical areas to execute motoric programs. Because the infarction involved the premotor area, micrographia may result from the inability of the basal ganglia to "direct" these premotor areas. Neglect is uncommonly reported in ACA infarctions^{1,7}; dominant-hemisphere infarctions produce motor neglect,¹ whereas nondominant-hemisphere lesions result in sensory neglect.^{1,7} The severity of the neglect syndrome in these cases is not consistently documented. There are no reports of impaired copying.

Our patient had an infarction of the right ACA territory, including the parafalcine and midline hemispheric portions of the right frontal and parietal lobes. The affected portion of the brain corresponds to the vascular distribution of the ACA found in anatomic studies.⁹ Sparing of the most anterior and inferior portions of the frontal lobe suggests preserved flow to the orbitofrontal and frontopolar arteries, the first two major branches of the ACA.¹⁰ Our patient shared some features with previously reported patients with ACA infarctions, including urinary incontinence, abulia, sensory neglect, and executive dysfunction. We also observed a complete left hemiplegia, impaired copying, and micrographia, which have not been previously reported. As indicated, involvement of the premotor area on MRI and the old infarct are the most likely source of the hemiplegia. The impaired copying seen in our patient sug-

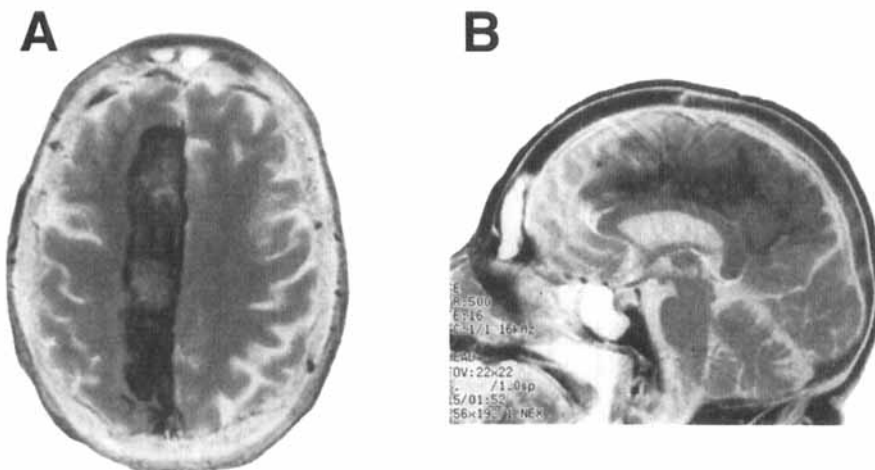


Figure 3. T1-weighted axial spin-echo MRI (A) demonstrates a subacute infarction of the right cerebral hemisphere in the distribution of the anterior cerebral artery. Enhancing edematous tissue in the frontal and parietal lobes is present in a parasagittal distribution. T1-weighted sagittal spin-echo image (B) just to the right of midline demonstrates that the infarct spares the most anterior (orbitofrontal and frontopolar) portions of the frontal lobe and the occipital lobe.

gests involvement of the parietal lobe—again supported by MRI findings and the presence of profound neglect. Micrographia is likely explained by the loss of connection between the basal ganglia and the premotor cortex.

The complete syndrome of ACA infarction is not known. An ACA territory infarct could be mistaken for an infarction in the territory of the middle cerebral artery because many of the features such as aphasia, neglect, and visuospatial impairment are similar. The findings in our patient should assist in clarifying the complete syndrome of infarction in the ACA territory.

Disclaimer. The opinions or assertions contained herein are the private views of the authors and are not to be construed as official or as reflecting the views of the Department of the Army or the Department of Defense.

From the Departments of Neurology, Walter Reed Army Medical Center, Washington, DC, and Uniformed Services University of the Health Sciences (Drs. Klatka and Marini), Bethesda, MD; and the Department of Radiology (Dr. Depper), Walter Reed Army Medical Center, Washington, DC.

Address correspondence and reprint requests to Dr. Ann M. Marini, Walter Reed Army Medical Center, Room 6243, 6900 Georgia Avenue NW, Washington, DC 20307.

References

1. Bogousslavsky J, Regli F. Anterior cerebral artery territory infarction in the Lausanne stroke registry. Clinical and etiologic patterns. *Arch Neurol* 1990;47:144–150.
2. Watson RT, Fleet S, Gonzalez-Rothi L, Heilman K. Apraxia and the supplementary motor area. *Arch Neurol* 1986;43:787–792.
3. McNabb AW, Carroll WM, Mastaglia FL. “Alien hand” and loss of bimanual coordination after dominant anterior cerebral artery territory infarction. *J Neurol Neurosurg Psychiatry* 1988;51:218–222.
4. Alexander M, Schmitt MA. The aphasia syndrome of stroke in the left anterior cerebral artery territory. *Arch Neurol* 1980;37:97–100.
5. Borggreve F, De Deyn PP, Mariën P, Cras P, Dierckx A. Bilateral infarction in the anterior cerebral artery vascular territory due to an unusual anomaly of the circle of Willis. *Stroke* 1994;25:1279–1281.
6. Freund H-J, Hummelsheim H. Lesions of premotor cortex in man. *Brain* 1985;108:697–733.
7. Brust JCM, Plank C, Burke A, Guobadia MMI, Heaton E. Language disorder in a right-hander after occlusion of the right anterior cerebral artery. *Neurology* 1982;32:492–497.
8. Marsden CD. What do the basal ganglia tell premotor cortical areas? In: *Motor areas of the cerebral cortex*. Ciba Foundation Symposium 132. Chichester, England: Wiley, 1987:282–300.
9. Van der Zwan A, Hillen B, Tulleken CAF, Dujovny M, Dragovic L. Variability of the territories of the major cerebral arteries. *J Neurosurg* 1992;77:927–940.
10. Osborne AG. *Introduction to cerebral angiography*. Philadelphia: Harper Row, 1980:185–237.

Ischemic strokes secondary to vitamin B₁₂ deficiency-induced hyperhomocystinemia

Article abstract—A 45-year-old woman sustained two ischemic cerebral infarctions 16 years after ileal resection for Crohn’s disease. Her evaluation showed an elevated random serum homocystine level, a low serum vitamin B₁₂ level, and an increased mean corpuscular volume (MCV) without anemia. A methionine-loading test resulted in a marked increase in the homocystine levels 2, 4, and 6 hours after the load. A Schilling test demonstrated a malabsorption of vitamin B₁₂. Vitamin B₁₂ injections normalized her fasting homocystine level and her MCV. She has had no recurrent strokes during a year follow-up.

NEUROLOGY 1998;51:622–624

LaRoy P. Penix, MD

The patient is a 45-year-old right-handed woman referred for evaluation of two prior ischemic cerebral infarctions. She was admitted to her local hospital in March 1996 after sudden-onset left homonymous hemianopsia. A CT scan showed an ischemic infarct in the right occipital lobe. A transthoracic echocardiogram showed no cardioembolic source. She was started on aspirin, 325 mg/d, and discharged. She presented to the hospital 1 month later after a sudden onset of expressive aphasia and right upper extremity weakness. A CT scan showed the old right occipital infarction and a mild hypodensity in the left frontal lobe consistent with an acute ischemic infarction.

Repeat CT scanning 3 days later yielded the left frontal infarction in the superior division of the middle cerebral artery (figure 1). A carotid duplex ultrasound study showed moderate stenosis of the origin of the right internal carotid artery. A transesophageal echocardiogram showed normal left ventricular wall motion, no atrial septal defects, and normal left atrium and atrial appendage. Coagulation studies showed normal levels of protein S, protein C, and antithrombin III. Tests for autoimmune disorders, lupus inhibitor, and anticardiolipin antibodies were normal. She was started on ticlopidine hydrochloride, 250 mg twice daily, and discharged. She was

Neurology[®]

Infarction in the territory of the anterior cerebral artery

Lisa A. Klatka, Mark H. Depper and Ann M. Marini

Neurology 1998;51;620-622

DOI 10.1212/WNL.51.2.620

This information is current as of August 1, 1998

Updated Information & Services	including high resolution figures, can be found at: http://www.neurology.org/content/51/2/620.full.html
References	This article cites 8 articles, 1 of which you can access for free at: http://www.neurology.org/content/51/2/620.full.html##ref-list-1
Citations	This article has been cited by 2 HighWire-hosted articles: http://www.neurology.org/content/51/2/620.full.html##otherarticles
Permissions & Licensing	Information about reproducing this article in parts (figures, tables) or in its entirety can be found online at: http://www.neurology.org/misc/about.xhtml#permissions
Reprints	Information about ordering reprints can be found online: http://www.neurology.org/misc/addir.xhtml#reprintsus

Neurology® is the official journal of the American Academy of Neurology. Published continuously since 1951, it is now a weekly with 48 issues per year. Copyright . All rights reserved. Print ISSN: 0028-3878. Online ISSN: 1526-632X.

