

M. G. Häusler¹
V. Th. Ramaekers¹
J. Reul²
R. Meilicke³
G. Heimann¹

Early and Late Onset Manifestations of Cerebral Vasculitis Related to Varicella Zoster

¹Division of Pediatric Neurology and Department of Pediatrics, Departments of ²Neuro-radiology and ³Immunology, University of Aachen, Aachen, Germany

Abstract

Varicella-zoster associated cerebral vasculitis (VZCV) as a cause of cerebral infarction has hitherto been considered a rare condition. Ischemic stroke in previously healthy children has occurred during recovery from chickenpox or has been attributed to virus reactivation among immunosuppressed patients.

The clinical, radiologic and immunologic findings in four children with VZCV will be reported. Clinical manifestations included sudden onset of hemiparesis, motor aphasia and disturbed consciousness in previously healthy children. Only one child had a history of chickenpox six weeks prior to the onset of stroke, whereas a latency period of up to four years between chickenpox and the onset of stroke was found in the other three children. Diagnosis of VZCV was confirmed repeatedly by demonstrating intrathecal production of varicella-zoster IgG antibodies in three children or a four-fold increase of varicella-zoster serum IgA-antibodies in one child. Intrathecal production of antibodies against other

latent viruses and borreliosis could be excluded. PCR for varicella on CSF, performed in two patients, remained negative. No intrathecal production of varicella-zoster antibodies has been found in a control group of twenty clinically healthy children (age range from 2–18 years) with a previous varicella infection.

During follow-up two children recovered completely whereas two children still suffer from serious neurological deficits. Immunological investigations, performed in three children, showed circulating immune-complexes with slightly lowered complement concentrations in two patients. In addition a lowered T-helper/T-suppressor cell ratio of unknown origin was found in three children. These immunological findings will be discussed in the light of the pathophysiology of VZCV.

Key words: Ischemic stroke – Varicella zoster – Vasculitis

Introduction

The incidence of ischemic stroke in childhood has been considered rare in comparison with the adult age group. Although the etiology in many childhood cases can be attributed to a broad spectrum of illnesses including metabolic, cardiac, genetic or acquired conditions, the cause remains unknown in up to 56% of all patients (3, 18, 21, 30, 33).

Cerebral vasculitis as a cause of ischemic stroke has been estimated to occur in about 4–12% of all childhood cases (18, 24). Cerebral vasculitis related to varicella zoster infection (VZCV) has been reported very rarely. Most cases of ischemic stroke after chickenpox have been reported to occur during the convalescence phase. A Japanese study in 1990 suggested that stroke complicates 1:6500 cases of childhood varicella infection (16). The majority of VZCV cases reported in the literature did occur during convalescence from a clinically apparent varicella-zoster virus (VZV) infection. The minority of cases suffered from herpes zoster ophthalmicus or developed stroke and systemic varicella-zoster infection during acute lymphoblastic leukemia (1, 4, 8, 13, 17, 20, 25, 31, 32, 35). Other predisposing factors leading to VZCV in previously healthy children are unknown. Compared with other cases of ischemic stroke in childhood, the prognosis seems to be good.

Since 1994 extensive CSF investigations with regard to specific neurotropic viruses (herpes simplex, varicella zoster, mumps, measles, HIV, rubella and *Epstein-Barr* virus) have been included in the list of putative causes underlying pediatric ischemic stroke. Thereupon the diagnosis VZCV due to reactivated zoster virus was suspected and then confirmed by demonstration of specific intrathecal antibody production in the first two patients (Cases 1 and 3). After this interesting finding a diagnosis VZCV could be established in retrospect in two other patients (28). The paper will present and discuss our findings in more detail.

Patients and methods

Between January 1994 and September 1995 four previously healthy children (between four and fourteen years of age), have been treated for varicella-zoster-associated cerebral vasculitis. There was no evidence for oncological, metabolic, hematological, thromboembolic or cardiovascular disease. A follow-up was available for all children, including clinical examination, transcranial duplex sonography (TCD) and neuroimaging. Neuro-radiological imaging included emergency- and follow-up CCT in all patients. Digital subtraction angiography was performed initially in two and MRI in the remaining two cases (Cases 1 and 4). During follow-up MRI examinations were done in three cases (Cases 1, 3 and 4).

The intrathecal production of antibodies against VZV in cerebrospinal fluid (CSF) was determined by calculation of antibody indices (AI). The antibody index has been calculated according to the following formula:

Received June 5, 1997; revised, accepted March 30, 1998

Neuropediatrics 29 (1998) 202–207

© Hippokrates Verlag Stuttgart

$$AI = \frac{\text{CSF/serum ratio of anti VZV specific IgG}}{\text{CSF/serum ratio of total IgG}}$$

Evaluation of CSF and serum was performed by two different laboratories: laboratory I (AI-I) or laboratory II (AI-II). AI-I values >1.5 or AI-II values >3 prove intrathecal antibody-production in CSF (laboratory-related reference ranges, for detailed description of this method see references 6 and 29). The AI against VZV has also been calculated for the serum and CSF samples drawn from a control group of 20 healthy children (age range between 2 and 18 years) with a clinically and serologically proven varicella infection without complications which had occurred many months or years prior to the time of admission during which a diagnostic lumbar puncture was done to rule out CNS infection or borreliosis. In the patients the specific AI was determined simultaneously for other latent viruses (rubella, coxsackie virus, cytomegalovirus, herpes simplex, mumps and measles) and borreliosis.

Extensive laboratory investigations, including lymphocyte phenotyping by FACS-analysis, have been performed in three children. Reference ranges for lymphocyte subsets were defined according to the findings described in the literature (5, 12, 15).

Results

Case reports

The individual clinical course, treatment and follow-up data are presented in more detail, while the most relevant laboratory findings have been summarized in Table 1.

Case 1

An eight-year-old boy, who had recovered from chickenpox two years previously, was admitted to our hospital because of three transient and short-lasting episodes with impaired speech and vegetative symptoms occurring during meals. On admission his neurological examination was completely normal. A left-sided ischemic lesion of the putamen and nucleus caudatus head was documented by MRI neuroimaging. Transcranial *Doppler* sonography (TCD) revealed raised cerebral blood-flow velocities indicating a significant stenosis of the left medial cerebral artery. On several occasions *Doppler* flow velocity signals from the left

arteria cerebri media were fluctuating probably indicating the occurrence of vasospasm with compromised circulation of the left lenticulostriate arteries. The VZV AI-II of 17.2 was clearly increased. Initial treatment consisted of prednisolone and administration of subcutaneous heparin. After five months steroids were withdrawn and heparin was replaced by acetylsalicylic acid. Despite the absence of further stroke-like events duplex sonography remained abnormal, indicating a persisting narrowing of the vessel lumen of the left medial cerebral artery. On follow-up, MRI documented residual lesions localized to the left putamen and nucleus caudatus head.

Case 2

A four-year-old boy, who had recovered from chickenpox one year before, manifested three short-lasting, transient ischemic attacks with right-sided hemiparesis, aphasia and disturbed consciousness. Although TCD and neurological examination between the attacks were normal, neuroimaging showed left-sided basal ganglia infarction. The VZV AI-II of 8.8 was markedly elevated. During follow-up over one year after discharge from hospital stroke-like episodes did not recur and treatment was not necessary. Clinical examination and TCD remained completely normal. Follow-up MRI showed residual scarring of the left-sided basal ganglia. The VZV AI after one year remained increased at 4.

Case 3

A 16-year-old girl had recovered from chickenpox four years before admission to our hospital. Since the age of three years she was treated with insulin for diabetes mellitus type I elsewhere. However, treatment was not optimal as reflected by the HbA1c level of 13.2%. Additionally, hyperlipidemia and arterial hypertension were present and there was also mild diabetic nephropathy and early neuropathy. She was admitted because of a sudden complete left-sided hemiparesis with impaired vigilance. One week after admission she regained consciousness. Persisting dysarthria, acalculia, retrograde amnesia and impairment of short-term memory reflected significant cognitive dysfunction. On TCD and angiography, a bilateral supraclinoid carotid artery occlusion was found which had resulted in multiple right hemispheric white-matter lesions and an additional lesion in the left internal capsule as detected by MRI (Fig. 1a-d). The bilateral

Table 1 Immunological and serologic data.

	Case 1 Onset	Follow-up	Case 2 Onset	Follow-up	Case 3 Onset	Follow-up	Case 4 Onset	Follow-up
CSF blood-brain-barrier	normal	n.d.	normal	n.d.	discretely disturbed	n.d.	normal	normal
CSF-VZV-PCR	n.d.	n.d.	n.d.	n.d.	negative (twice)	n.d.	n.d.	negative
Intrathecal anti-VZV-antibodies	AI-II positive (17.2)	n.d.	AI-II positive (8.8)	AI-I positive (4.0)	AI-II negative (0.84)	n.d.	AI-I positive (5.3)	AI-I positive (7.2); AI-II positive (3.27)
Anti VZV-IgA in serum	negative	n.d.	n.d.	negative	max. 1:4069	1:1024	n.d.	negative
IgG (g/l)	9.5		6.5	6.86	5.32↓	7.38↓	11.4	12.3
IgM (g/l)	0.91		1.07	1.19	1.63	1.8	1.09	1.78
IgA (g/l)	1.23		0.37	0.33	1.9	1.18	0.78	1.05
C3 (mg/l)	600		600	600	1050	680	720	680
C4 (mg/l)	220		150(↓)	130(↓)	410	140(↓)	180	140(↓)
C1q IgG CIC	negative		negative	negative	negative		negative	negative
C3d IgG CIC	negative		negative	elevated	negative		elevated	elevated
T-cells/μl				1185↓	1062↓	866↓		1752
B-cells/μl				363	235	365		384
CD4/μl (Helper)				573↓	511↓	421↓		864
CD8/μl (Suppressor)				631	552	477		912
Cd4/CD8 ratio				0.91↓	0.93↓	0.88↓		0.95↓

CIC: circulating immune complexes; n.d.: not done

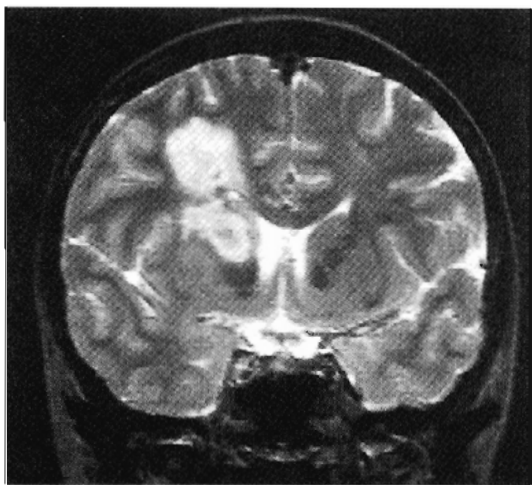


Fig. 1a

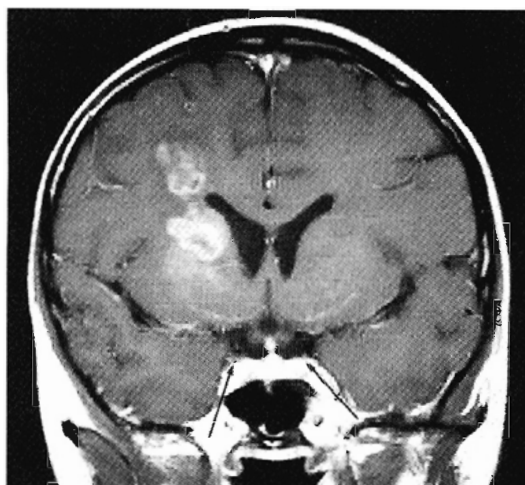


Fig. 1b

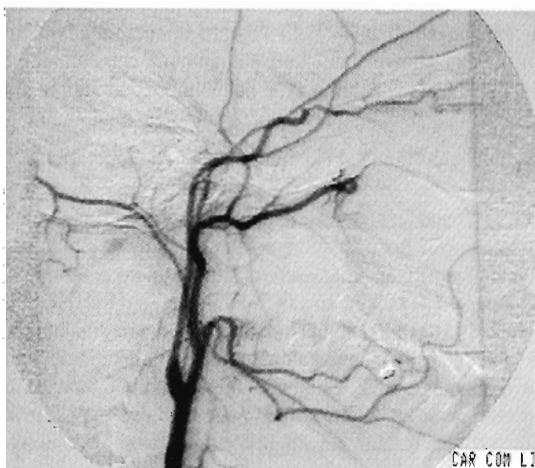


Fig. 1c

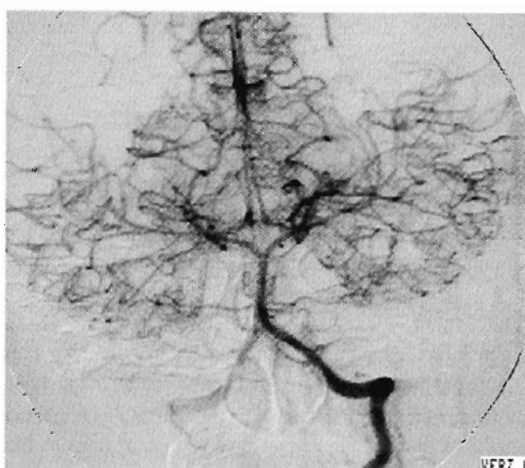


Fig. 1d

Fig. 1a to d Case 3: **a)** (coronal T₂-weighted image) and **b)** (coronal T₁-weighted image) show a high signal lesion in the right basal ganglia and periventricular white matter. The differential diagnosis includes an inflammatory or a vascular lesion. The T₁-weighted image is acquired after intravenous administration of contrast media (Gad-DTPA). It demonstrates a pathological leptomeningeal enhancement which corresponds to the abnormal leptomeningeal collateralization caused by the bilateral occlusion

of the internal carotid artery. Note the small diameter of the lumen of the carotid artery in its cavernous extradural portion (arrows). **c)** and **d)** demonstrates the angiographic findings with bilateral occlusion of the C1 portion of the internal carotid artery and extensive collateral flow via the posterior communicating arteries and the leptomeningeal collaterals, which can explain the abnormal vascular enhancement on MRI scans.

occlusion of the internal carotid arteries was associated with development of significant leptomeningeal collateral circulation, which provided an adequate collateral neovascularisation network as demonstrated by SPECT studies. Serial CSF-examinations showed a discrete disturbance of the blood-brain-barrier. Upon admission CSF-VZV-PCR and AI-II were repeatedly negative. Since a slowly progressive cerebral vasculitis was suspected, treatment was started with subcutaneous heparin and oral prednisolone. During the ensuing two months anti-VZV IgA-antibody levels in serum increased from 1:512 to 1:4096, suggesting VZV-reactivation. Seven months after the onset of stroke she has been put on a low-dose acetylsalicylic acid, lopirine and an appropriate dose of insulin. Despite significant recovery of her hemiparesis ten months after the primary manifestations, her cognitive function still remains impaired. TCD shows further evidence of extensive intracranial arterial stenosis.

Case 4

Six weeks after recovery from chickenpox, an eight-year-old boy developed a complete right-sided hemiparesis and somnolence. Neuroimaging and angiography indicated a left-sided basal ganglia infarction and a circumscribed ipsilateral cortical ischemic lesion in the presence of a long-distance narrowing within the lumen of the left medial cerebral artery and vasospasms within the distal branches (Fig. 2a-c). The AI-I for VZV was raised at 5.3. Low serum but absent CSF-antibody levels for *Borrelia burgdorferi* suggested a recent Borrelia infection. Significant elevation of anti-HSV1- and anti-HSV2 IgG- and IgM antibodies in serum in the absence of CSF antibodies were interpreted as recent HSV-reactivation. The boy was treated with a combination of cephalosporins (10 days), prednisolone (120 days), acetylsalicylic acid (2 days), acyclovir (2 days) and low doses of heparin (10 months). Three days after hospital admission he regained consciousness. Although stroke-like events did not recur, TCD

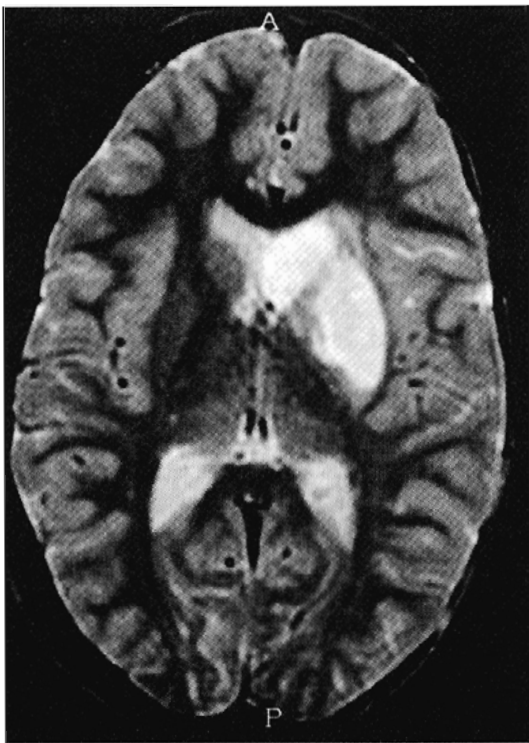

Fig. 2a

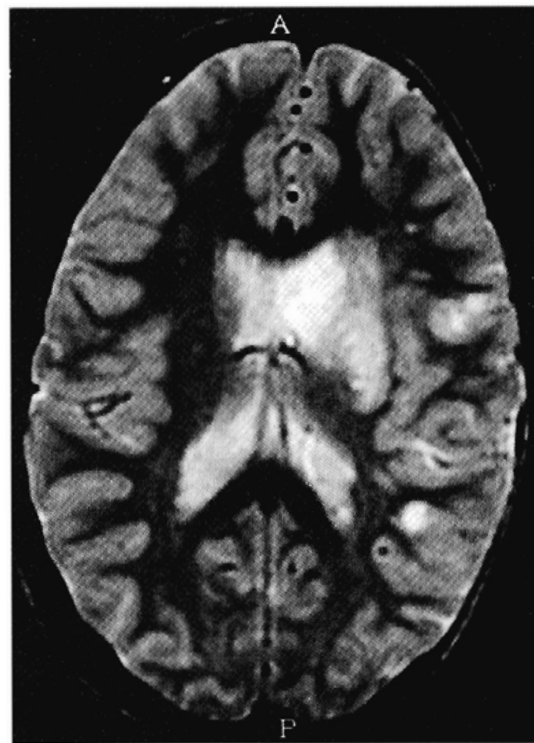


Fig. 2b

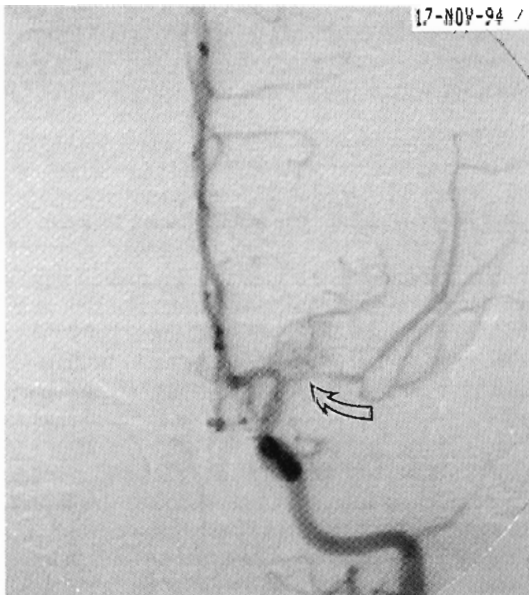


Fig. 2c

Fig. 2a to d Case 4: a) and b) demonstrate the ischemic infarction of the left basal ganglia. A lenticular stroke of this size is usually caused by an occlusion of the middle cerebral artery (MCA). Angiography detects a high-grade stenosis of the MCA (arrow, c) which remains nearly unchanged after

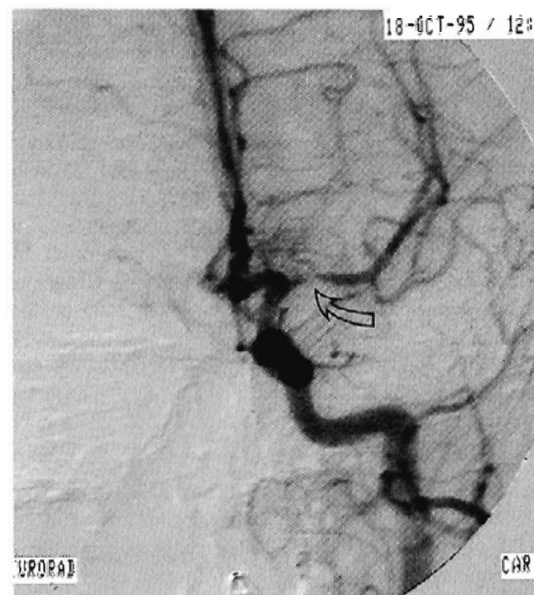

Fig. 2d

one year (d). However, the vasculitic changes visible on several intracranial vessels in c) have disappeared. Now the peripheral vascular territories appear normal, suggesting that the inflammatory process has regressed.

and follow-up angiography, performed eight weeks after admission, suggested a slowly progressive vasculitis confined to the left medial artery and its branches. Now, 14 months later, the persistence of a circumscribed left-sided middle cerebral artery stenosis has been confirmed by angiography (Fig. 2d). Subcutaneous administration of heparin is continued. Right-sided hemiparesis without cognitive impairment persists.

Laboratory investigations

Homocystinuria and inborn errors of metabolism, thrombembolism, cardiovascular abnormalities, infections by other neurotropic infectious agents (including HIV and toxoplasmosis) and coagulation disorders (including antithrombin III, protein C and S deficiency) have been ruled out in all children. Patients 1, 2 and

4 showed normal levels of triglycerides and cholesterol. Initial CSF examination was normal and oligoclonal bands were absent in all children.

On admission and follow-up the AI for VZV was clearly increased in Patients 1, 2 and 4, while in Patient 3 reactivation of VZV was suggested by the four-fold rise of IgA titers. On two occasions CSF analysis using the PCR for VZV was negative. Simultaneous measurements of the AI for measles, rubella, mumps, herpes simplex, cytomegalovirus, coxsackie virus and borreliosis showed negative results thereby excluding intrathecal IgG production for other latent viruses or a generalized reactivation due to for instance failing immune surveillance.

Among the control group of 20 clinically healthy children with previous uncomplicated varicella infection (months to years before the actual lumbar puncture), the maximum value of the AI against VZV was 1.24, thereby excluding intrathecal production of specific VZV antibodies. Immunological investigation in all patients showed negative antinuclear antibodies (ANA), anti-neutrophil cytoplasmic antibodies (ANCA) or anti-phospholipid antibodies. Two children (Cases 2 and 4) had slightly lowered C4-complement values and elevated levels of circulating immune complexes. HLA-typing did not show a common HLA-constellation (Table 2).

In Patients 2 and 3 the absolute count of B- and T-cells was low on several occasions. The absolute count of CD4+-T-helper and CD8+-T-suppressor cells was at the lower range of normal. The calculated CD4+/CD8+ ratio was reduced in Patients 2, 3 and 4. The history of all patients did not reveal clinical evidence for immune dysfunction (Table 1).

Discussion

Compared with adults, ischemic and silent strokes in childhood are rare events with a different etiology. Two of our patients (Cases 1 and 2) only manifested symptoms of transient hemiparesis and speech impairment. Neuroimaging disclosed lesions confined to the basal ganglia which could be explained by ischemia within the territory of lenticulostriate arteries. The two other patients (Cases 3 and 4) suffered from long-lasting neurological and cognitive deficit. In patients with transient symptomatology due to stroke-like events the correct diagnosis may be delayed. Therefore, in the presence of transient symptoms development of basal ganglia lesions should be carefully sought for by combination of *Doppler* studies, EEG- and MR imaging.

All patients had focal EEG slowing and abnormal MRI- or CCT findings. Rapidly fluctuating flow velocity signals detected by transcranial *Doppler* investigations in three patients apparently reflected superimposed vasospasm within inflamed cerebral arterial vessels. The initial CSF cell count, glucose and protein level were normal in all patients. The elevated antibody-index confirmed intrathecal VZV-antibody production in CSF in Patients 1, 2 and 4, suggesting that VZV-associated immunological processes were involved in the vascular alterations. In Patient 3, the elevated and fourfold increase of VZV IgA-antibody levels in serum reflected VZV reactivation. The specific AI for other latent viruses and borreliosis remained negative. Moreover, the control group of 20 children, who had recovered without complications after chickenpox before lumbar puncture, showed negative results for the specific AI against VZV. In adults, VZCV has been described among immunocompromised patients or occurred simultaneously during ophthalmic herpes zoster (2, 14, 22). In childhood, most reported cases followed shortly after chickenpox

as in Case 4. Our most important and new finding in three of our four patients was the very late onset of VZCV after a latency of up to four years following the initial VZV infection. This contrasts with most reports in the literature where ischemic stroke manifests within weeks to four months after chickenpox. The history of our patients indicated that the initial illness ran an uncomplicated course. In none of our children clinical evidence for impaired immune defense mechanisms was present.

None of our patients showed a significant elevation of common markers for autoimmune-vasculitis like ANA, ANCA, or anti-phospholipid-antibodies. The two patients with slightly reduced C4-complement values also showed slightly increased levels of circulating immune complexes in serum. This does not exclude VZV as the etiologic agent but might indicate that active and long-lasting immune processes are contributing to the vasculitis.

The traditional concept of VZV reactivation envisages replication and spread of dormant virus particles in ganglion cells, leading to formation of skin lesions within innervated dermatomes (23). Corresponding with this concept acute VZV reactivation within autonomous or sensory nerves surrounding brain vessels might also promote spread of virus towards intracranial arteries. This can evoke an immediate and specific immune response with local inflammation or final destruction of the vessel wall. The findings on admission of increased intrathecal production of specific antibodies did indeed suggest an immunological response against varicella zoster. Fluctuating blood flow in affected intracranial vessels suggests vasospasm occurring within inflamed arteries. The presence of extensive leptomeningeal collateralization in Case 3, as shown by angiography and SPECT, suggests a slowly progressive and bilateral occlusion of the internal carotid arteries. Although VZV-PCR was negative in Patients 3 and 4, this does not exclude the possibility of active virus replication within their vessel walls.

The literature on post-mortem histopathological examinations after VZCV (7, 9, 10, 14, 19, 34) does not mention common histopathological characteristics. The inflammatory process was characterized by mononuclear infiltrations, histiocytes, giant cells or the formation of granulomas. Arterial wall destruction ranged from intimal proliferation to complete infiltration of the vessel wall with formation of microabscesses and aneurysms. Viral inclusion bodies were found inside the histiocytes and inside the smooth muscular cells of the affected vessels. These reports and our own findings suggest that VZCV is not a homogenous pathophysiological entity. Different predisposing factors might contribute to a variable susceptibility for VZV and lead to different forms of vascular inflammation. Although the expression "varicella-zoster-associated cerebrovasculitis" does imply a histological diagnosis, histopathological proof in our patients could not be obtained since a biopsy from affected intracranial vessels is not possible. *Hankey* (11), who reviewed 100 cases of isolated angiopathy of the central nervous system in children, even proposed that diagnosis of angiitis of the central nervous system should be restricted to histologically proven cases, whereas cerebrovascular processes without histologically confirmed diagnosis should be called angiopathy. In some cases affected leptomeningeal vessels can be used for biopsy, when the diagnosis remains obscure and is warranted for the purpose of treatment. However, in our cases leptomeningeal arteries did not seem to be involved.

In the adult, VZCV has especially been described in immunocompromised patients (9, 14, 26). Although none of our children did have clinical evidence for immune dysfunction, our data

might indicate disturbed immunological surveillance predominantly due to inadequate T-helper cell function. Even long after the acute clinical presentation and after discontinuation of steroid therapy the three investigated patients showed a slightly reduced CD4|CD8 ratio, predominantly caused by an absolute or relative lower count of T-helper cells. In addition Patients 2 and 3 showed lowered absolute counts of B- and T-cells. Together with other factors like diabetes mellitus, arterial hypertension and hyperlipidemia (Patient 3) or recent *Borrelia* infection (Patient 4), these changes might have influenced appropriate immune surveillance and have promoted a common final pathway with inadequate defence against dormant VZV. Finally, the low CD4+|CD8+ ratio as a consequence of ongoing inflammatory activity within affected cerebral vessels, seems unlikely because an increase of CD8+ T-suppressor cells and not a decrease of T-helper cell-counts would have to be expected.

Focusing on ischemic stroke due to vasculitic processes, *Hankey et al* (11) found a better outcome in patients treated with a combination of prednisolone and cyclophosphamide, whereas *Pavlakis and Bourdette* (2, 27) could not establish a correlation between special therapeutic strategies and survival rate. During the acute phase three of our patients (Patients 1, 3 and 4) have been treated with prednisolone and heparin. After varying intervals prednisolone has been discontinued. In two patients (Patients 3 and 4) heparin was replaced by acetylsalicylic acid. Although hemiparesis and cognitive dysfunction persist in two patients (Patients 3 and 4) the clinical course was self-limited. The question whether acyclovir treatment would have been effective cannot be judged from the available data. Acyclovir can only reduce virus replication and not prevent persistence of dormant virus DNA within neuronal cells. If the vasculitis is sustained by autoimmune processes independent from persistence of virus particles, then acyclovir treatment would not be expected to improve outcome. Nevertheless, further studies should help to clarify the incidence of VZCV and the early intervention of acyclovir with respect to outcome of affected patients.

References

- 1 *Bodensteiner, J. B., Hille, M. R., Riggs, J. E.* Clinical features of vascular thrombosis following varicella. *AJDC* 146, 100–102 (1992).
- 2 *Bourdette, D. N., Rosenberg, N. L., Yatsu, F. M.* Herpes zoster ophthalmicus and delayed ipsilateral infarction. *Neurology* 33, 1428–1432 (1983).
- 3 *Dusser, A., Goutières, F., Aicardi, J.* Ischemic strokes in children. *J. Child Neurol.* 1, 131–136 (1986).
- 4 *Eda, I., Takashima, S., Takeshita, K.* Acute hemiplegia with lacunar infarct after varicella infection in childhood. *Brain Dev.* 5, 494–499 (1983).
- 5 *Erkeller-Yuksel, F. M., Deneys, V., Yuksel, B., Hannel, I., Hulstaert, F., Hamilton, C., et al.* Age-related changes in human blood lymphocyte subpopulations. *J. Pediatr.* 120, 216–222 (1992).
- 6 *Felgenhauer, K., Reiber, H.* The diagnostic significance of antibody specificity indices in multiple sclerosis and herpes virus induced diseases of the nervous system. *Clin. Invest.* 70, 28–37 (1992).
- 7 *Fukumoto, S., Kinjo, M., Hokamura, K., Tanaka, K.* Subarachnoid hemorrhage and granulomatous angitis of the basilar artery: demonstration of the varicella-zoster virus in the basilar artery lesions. *Stroke* 17, 1024–1028 (1986).
- 8 *Ganesan, V., Kirkham, F. J.* Mechanisms of ischaemic stroke after chickenpox. *Arch. Dis. Child.* 76, 522–525 (1997).
- 9 *Gray, F., Bélec, L., Lescs, M. C., Chrétien, F., Ciardi, A., Hassine, D., et al.* Varicella-zoster virus infection of the central nervous system in the acquired immune deficiency syndrome. *Brain* 117, 987–999 (1994).
- 10 *Halonen, H., Halonen, V., Donner, M., Iivanainen, M., Vuolio, M., Maekinen, J.* Occlusive disease of intracranial main arteries with collateral networks in children. *Neuropädiatrie* 4, 187–206 (1973).

- 11 *Hankey, G. J.* Isolated angitis/angiopathy of the central nervous system. *Cerebrovasc. Dis.* 1, 2–15 (1991).
- 12 *Heldrup, J., Kalm, O., Prellner, K.* Blood T and B lymphocyte subpopulations in healthy infants. *Acta Paediatr.* 81, 125–132 (1992).
- 13 *Higgins, J. J., Kammerman, L. A., Fitz, Ch. R.* Predictors of survival and characteristics of childhood stroke. *Neuropediatrics* 22, 190–193 (1991).
- 14 *Hilt, D. C., Buchholz, D., Krumholz, A., Weiss, H., Wolinsky, J. S.* Herpes zoster ophthalmicus and delayed contralateral hemiparesis caused by cerebral angitis: diagnosis and management approaches. *Ann. Neurol.* 14, 543–553 (1983).
- 15 *Hulstaert, F., Hannel, L., Deneys, V., Munhyeshuli, V., Reichert, T., de Bruyere, M., et al.* Age-related changes in human blood lymphocyte subpopulations. *Clin. Immunol. Immunopathol.* 70, 152–158 (1994).
- 16 *Ichiyama, T., Houdou, S., Kisa, T., Ohno, K., Takeshita, K.* Varicella with delayed hemiplegia. *Pediatr. Neurol.* 6, 279–281 (1990).
- 17 *Kamholz, J., Tremblay, G.* Chickenpox with delayed contralateral hemiparesis caused by cerebral angitis. *Ann. Neurol.* 18, 358–360 (1985).
- 18 *Keidan, H., Shahar, E., Barzilay, Z., Passwell, J., Brand, N.* Predictors of outcome of stroke in infants and children based on clinical data and radiologic correlates. *Acta Paediatr.* 83, 762–765 (1994).
- 19 *Linneman, C. C., Alvirra, M. M.* Pathogenesis of varicella-zoster angitis in the CNS. *Arch. Neurol.* 37, 239–240 (1980).
- 20 *Liu, C. T., Holmes, G. L.* Varicella with delayed contralateral hemiparesis detected by MRI. *Pediatr. Neurol.* 6, 131–134 (1990).
- 21 *Livet, M. O., Raybaud, C., Pinsard, N.* Aspects diagnostiques des occlusions artérielles cérébrales de l'enfant. *Ann. Pediatr.* 27, 277–285 (1980).
- 22 *Mac Kenzie, R., Forbes, G. S., Karnes, W. E.* Angiographic findings in herpes zoster arteritis. *Ann. Neurol.* 10, 458–464 (1981).
- 23 *Meier, J. L., Straus, S. E.* Comparative biology of latent varicella-zoster virus and herpes simplex virus infections. *J. Infect. Dis.* 166, S13–23 (Suppl 1) (1992).
- 24 *Nagaraja, D., Verma, A., Taly, A. B., Veerendra Kumar, M., Jayakumar, P. N.* Cerebrovascular disease in children. *Acta Neurol. Scand.* 90, 251–255 (1994).
- 25 *Nguyen, P., Reynaud, J., Pouzol, P., Munzer, M., Richard, O., Francois, P.* Varicella and thrombotic complications associated with transient protein C and protein S deficiencies in children. *Eur. J. Pediatr.* 153, 646–649 (1994).
- 26 *Park, Y. D., Belman, A. L., Kim, T. S., Kure, K., Llana, J. F., Lantos, G.* Stroke in pediatric acquired immunodeficiency syndrome. *Ann. Neurol.* 28, 303–311 (1990).
- 27 *Pavlakis, S. G., Gould, R. J., Zito, J. L.* Stroke in children. *Adv. Pediatr.* 38, 151–179 (1991).
- 28 *Ramaekers, V. Th., Reul, J., Häusler, M., Heimann, G.* Varicella-Zoster assoziierte cerebrale Vaskulitis. *Monatsschr. Kinderheilkd.* 144, 981 (Abstract) (1996).
- 29 *Reiber, H.* The discrimination between different blood-CSF barrier dysfunctions and inflammatory reactions of the CNS by a recent evaluation graph for the protein profile of cerebrospinal fluid. *J. Neurol.* 224, 89–99 (1980).
- 30 *Schoenberg, B. S., Mellinger, J. F., Schoenberg, D. G.* Cerebrovascular disease in infants and children: a study of incidence, clinical features, and survival. *Neurology* 28, 763–768 (1978).
- 31 *Shuper, A., Vining, E. P. G., Freeman, J. M.* Central nervous system vasculitis after chickenpox – cause or coincidence? *Arch. Dis. Child.* 65, 1245–1248 (1990).
- 32 *Silverstein, F. S., Brunberg, J. A.* Postvaricella basal ganglia infarction in children. *AJNR* 16, 449–452 (1995).
- 33 *Solomon, G. E., Hilal, S. K., Gold, A. P., Carter, S.* Natural history of acute hemiplegia of childhood. *Brain* 93, 107–120 (1970).
- 34 *Victor, D. J., Grenn, W. R.* Temporal artery biopsy in herpes zoster ophthalmicus with delayed arteritis. *Am. J. Ophthalmol.* 82, 628–630 (1976).
- 35 *Walker, R. J., Gammal, T. E., Allen, M. B.* Cranial arteritis associated with herpes zoster. *Radiology* 107, 109–110 (1973).

V. Th. Ramaekers, M.D., Ph.D.

Division of Pediatric Neurology
Department of Pediatrics
Universitätsklinikum der RWTH Aachen
Pauwelsstr. 30
D-52054 Aachen
Germany