

Primary Stenting of the Extracranial Internal Carotid Artery in a Patient with Multiple Cervical Dissections: Technical Case Report

Domagoj Coric, M.D., John A. Wilson, M.D.,
John D. Regan, M.D., D. Antonio Bell, M.D.

Departments of Neurosurgery (DC, JAW) and Radiology (JDR), Wake Forest University Baptist Medical Center, Winston-Salem, and Department of Radiology (DAB), Presbyterian Hospital, Charlotte, North Carolina

OBJECTIVE AND IMPORTANCE: Spontaneous dissection of the extracranial internal carotid artery (ICA) and vertebral artery (VA) is a well-documented cause of stroke in young, previously healthy patients. The majority of patients with spontaneous dissection are successfully treated with antiplatelet or anticoagulation therapy, but a significant proportion of patients progress to suffer devastating morbidity and mortality. Surgical intervention has primarily consisted of proximal ligation, extracranial-intracranial bypass, or endarterectomy. Generally, these procedures are technically demanding and yield disappointing clinical results.

CLINICAL PRESENTATION/INTERVENTION: A 36-year-old man without a significant medical history initially presented with a several-day history of episodic right upper extremity weakness and numbness and visual obscurations. Cerebral angiography revealed bilateral ICA long segment narrowing (95%), distal left VA high-grade (95%) stenosis compatible with dissections, and right VA proximal occlusion. While therapeutically anticoagulated on heparin, the patient continued to experience crescendo episodes of right upper extremity paresis and paresthesias as well as aphasia. The patient underwent primary stenting of the left ICA, using a series of six overlapping stents (three Gianturco-Roubin coronary stents and three Palmaz-Schatz coronary stents). The patient remained symptom-free without neurological complications, and subsequent angiography performed at the 9-month follow-up examination confirmed continued patency of the stented left ICA as well as recanalization of the right ICA and VA.

CONCLUSION: Neurovascular stents offer a minimally invasive and potentially efficacious treatment for the prevention of cerebral ischemia in patients with spontaneous extracranial dissection who remain symptomatic despite therapeutic anticoagulation. (Neurosurgery 43:956-959, 1998)

Key words: Carotid stenting, Endovascular therapy, Spontaneous carotid dissection

Spontaneous dissection of the extracranial internal carotid artery (ICA) and vertebral artery (VA) is a well-documented and significant cause

of stroke (1-3, 6, 10, 14, 18). The impact of the morbidity associated with spontaneous dissection is exacerbated by the young age of those afflicted (2, 3, 24, 28).

Spontaneous dissection has been shown to account for up to 5 to 20% of ischemic strokes in patients under the age of 45 years (10) and 2.5% of patients with first strokes (2). The extracranial ICA is the most frequent site of spontaneous dissection, with both ICAs involved in a minority of cases ($\leq 15\%$) (13). Between one-fourth and one-half of patients with spontaneous dissection of the extracranial ICA suffer stroke (3, 8, 15, 28). In a recent series of 80 consecutive patients with carotid artery dissections, 42 patients (52%) suffered neurological deficits, with stroke occurring up to 1 month after recognition of the dissection (1). In a study of 30 consecutive patients with spontaneous carotid dissection who presented with acute stroke, 23% died within 1 week and nearly half (48%) of the long-term survivors showed severe neurological impairment with poor functional recovery (3). The incidence of ischemic events is generally reported as being higher in cases of VA dissection (16, 25). A patient with spontaneous dissections of both the extracranial ICA and the left VA as well as an iatrogenically induced dissection of the right VA was treated using endovascular placement of overlapping neurovascular stents into the most symptomatic artery.

CASE REPORT

Clinical presentation

A 36-year-old man without a significant medical history initially presented with a several-day history of episodic right upper extremity weakness and numbness and visual obscurations. The patient related three discrete episodes, each lasting 15 to 20 minutes, that occurred during a 3-day period. The patient presented to his family doctor and underwent cranial computed tomography. The results were unremarkable, and the patient was treated with aspirin for presumed transient ischemic attacks. The patient subsequently returned to work, where he experienced a 20-minute episode of right upper extremity paresthesia and paresis as well as aphasia. The patient then presented to a re-

ferring emergency department and was therapeutically anticoagulated with heparin. A subsequent workup included the following: 1) magnetic resonance imaging/magnetic resonance angiography, which revealed a posterior left frontal infarct as well as a right frontal infarct and bilateral ICA and left vertebral stenoses; 2) cerebral angiography, which revealed bilateral ICA long segment narrowing (95%) (Fig. 1) and distal left VA high-grade (95%) stenosis compatible with dissections (during angiography at the referring institution, the intima of the right VA was compromised, resulting in a proximal occlusion); and 3) single photon emission computed tomography, which revealed two small perfusion defects, one in the right frontal lobe and one in the left posterior frontal lobe. The patient denied any history of trauma, tobacco use, or alcohol use. Lab studies at our facility included polymerase chain reaction, revealing no abnormality in the structure or biosynthesis of Types I and III collagen and a normal urine homocysteine level. An ophthalmological evaluation showed normal lenses and a normal fundoscopic examination. A dermatological examination showed normal skin without hypermobility. While hospitalized and receiving heparin (partial thromboplastin time = 70–80 s), the patient continued to experience crescendo episodes of right upper extremity paresis and paresthesias and aphasia.

Intervention

Endovascular treatment was directed only at the symptomatic left ICA dissection. A microcatheter was placed be-

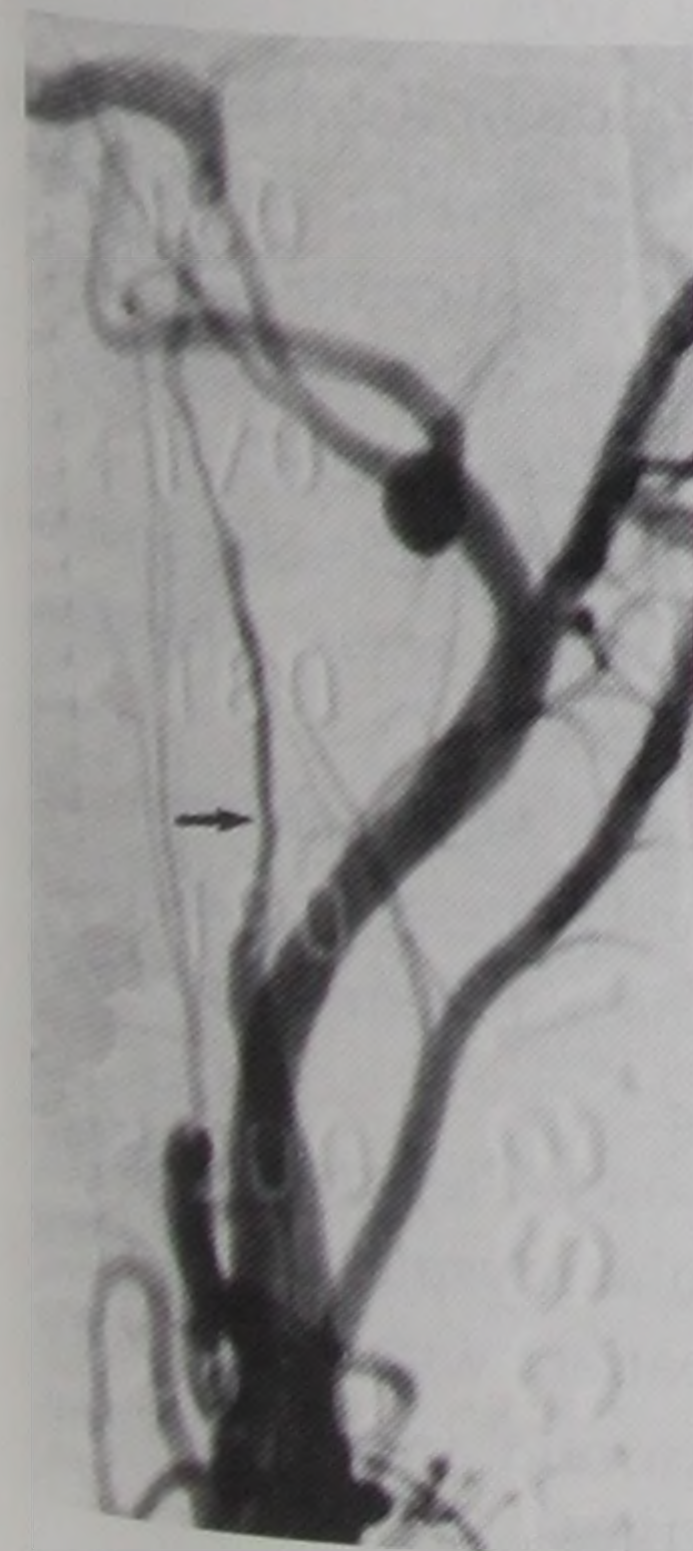


FIGURE 1. Admission arteriogram revealing dissection of the left ICA (arrow).

yond the dissection and used to perform angiography to confirm positioning within the true lumen. The patient underwent primary stenting of the left ICA, using a series of six overlapping stents (2.5 × 12-mm, 3 × 20-mm, and 3.5 × 20-mm Gianturco-Roubin coronary stents and three 3.5 × 15-mm Palmaz-Schatz coronary stents) (Fig. 2). The Gianturco-Roubin stent was chosen because of the greater flexibility of its delivery system, allowing placement beyond the cephalad extent of the dissection into the proximal petrous ICA. The Palmaz-Schatz stents were placed within the Gianturco-Roubin stents to improve radial strength. The Palmaz-Schatz stents were chosen, in this case, based on their being readily available at our institution. The last stent was placed 2 to 3 cm above the carotid bulb. At the end of the procedure, blood flow through the stented artery was much improved and there was spontaneous crossfill of the contralateral hemisphere via a patent anterior communicating artery. A mild amount of contrast was noted to pool in the false lumen of the dissection. No interventional treatment was directed at the other dissections. After the procedure, the patient's therapeutic anticoagulation was maintained with heparin and then coumadin and ticlopidine. At the 5-month follow-up examination, the patient remained symptom-free and sequential Doppler studies documented the patency of the stented left ICA and recanalization of the right ICA and bilateral VAs. At the 6-month follow-up examination, coumadin anticoagulation was discontinued. Subsequent angiography per-

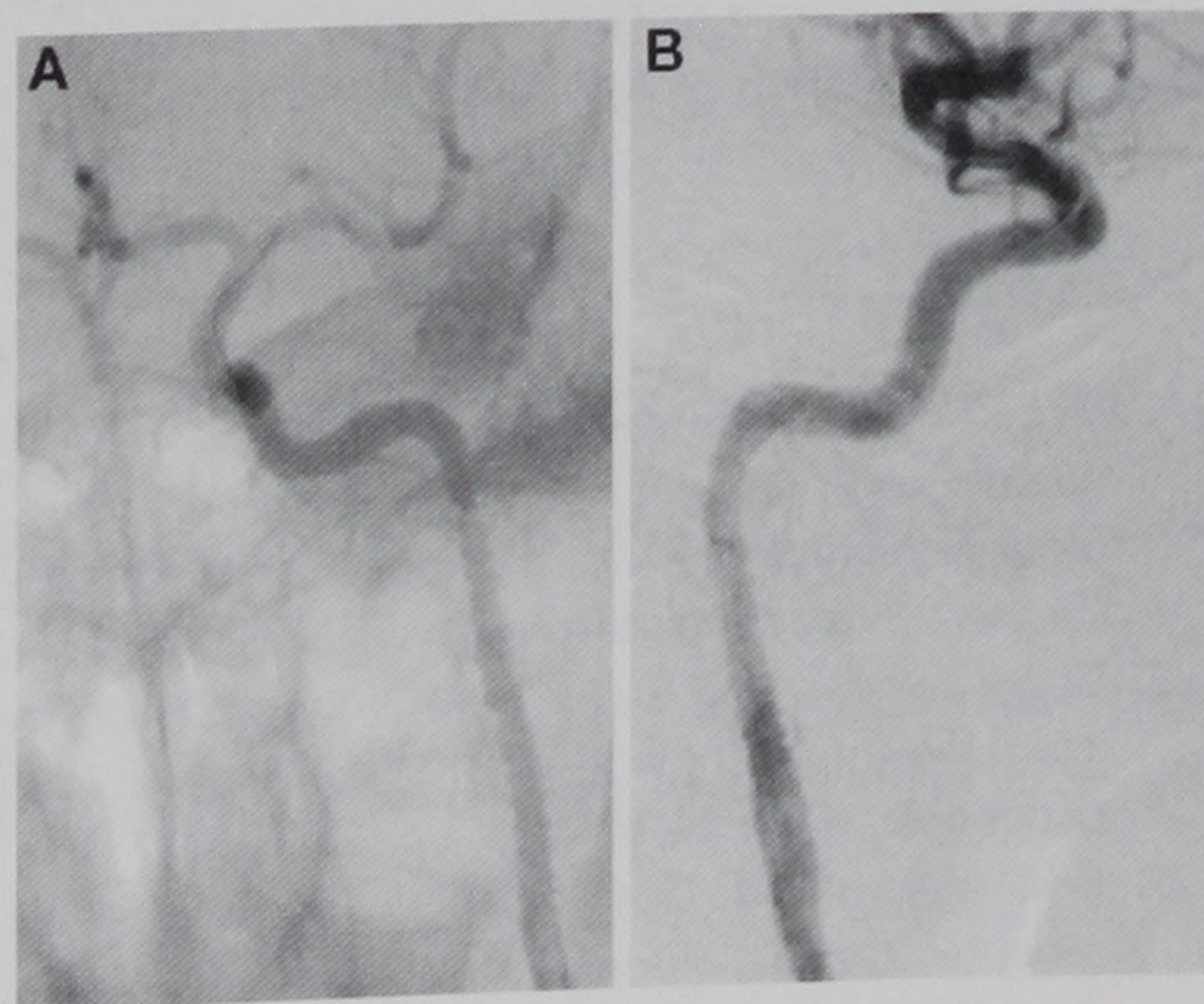


FIGURE 2. Anteroposterior (left) and lateral (right) views of the left ICA after stent placement.

formed at the 9-month follow-up examination confirmed continued patency of the stented left ICA (Fig. 3) as well as the right ICA and VAs. The patient remained symptom-free without neurological complications, returned to full-time employment, and was maintained on aspirin therapy alone.

DISCUSSION

The natural history of carotid and VA dissections generally leads to spontaneous healing of the lesion (17, 19, 21), but there is a significant percentage of cases that show persistence, progression, or recurrence of the dissection (1, 6, 17, 23, 27). The first-line therapy for extracranial dissection is pharmacological, primarily consisting of antiplatelet or anticoagulation therapy (8, 20, 26). The majority of patients with spontaneous dissection are successfully treated with this modality, but a well-documented and significant proportion of patients progress to suffer devastating morbidity and mortality (7, 17, 20). Traditionally, surgical intervention has been reserved for patients with persistent or worsening neurological deficits despite therapeutic anticoagulation and for patients in whom anticoagulation is contraindicated (12, 14, 17, 19, 24). Surgical intervention has consisted primarily of proximal ligation, extracranial-intracranial bypass, or endarterectomy (4, 14, 17, 24). Recently, Morgan and Sekhon (17) (1994) reported the use of extracranial-intracranial saphenous vein bypass in six cases of carotid or VA dissections. This bypass procedure is technically de-

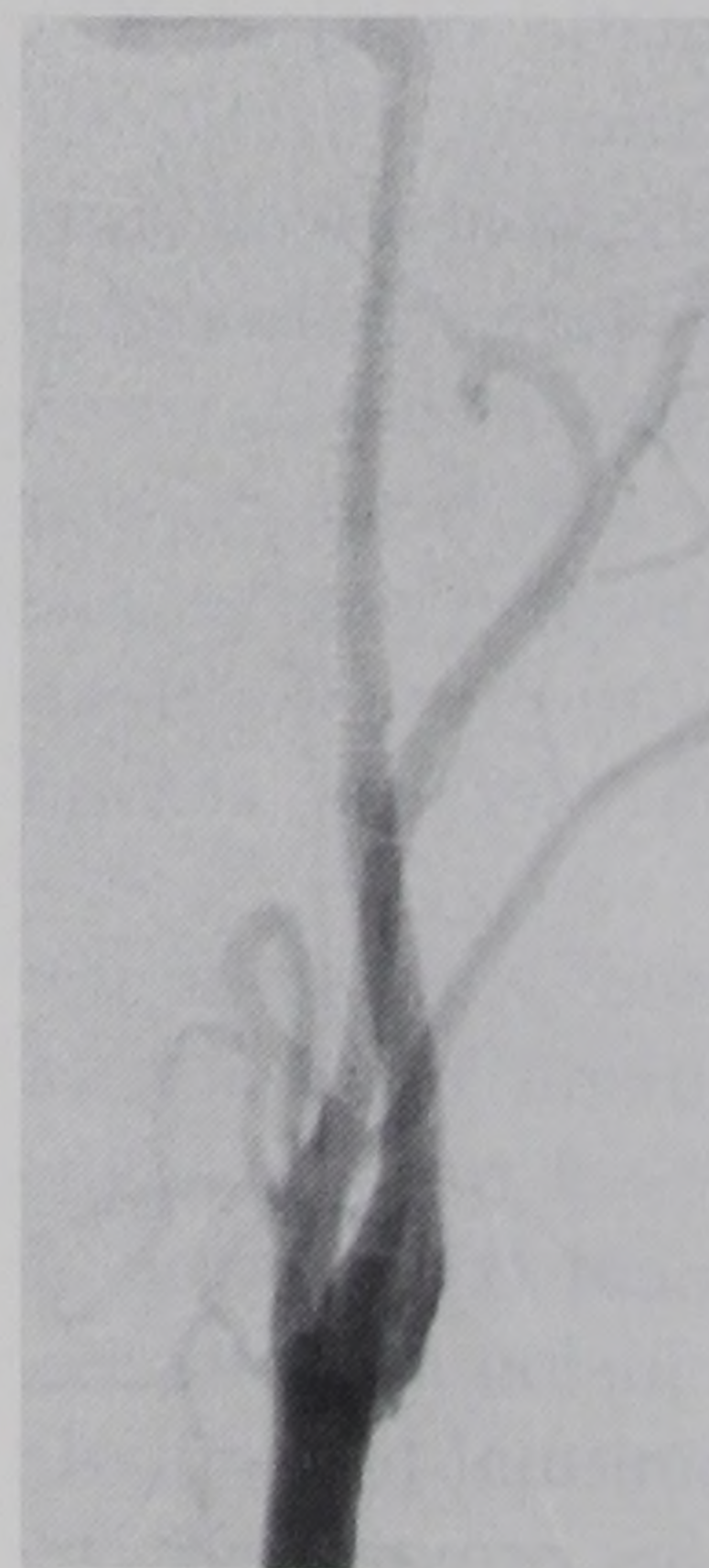


FIGURE 3. Follow-up angiogram, obtained 9 months after the procedure, demonstrating the patency of the left ICA.

manding, requiring a pterional craniotomy as well as a cross-clamp time of approximately 60 minutes. The authors reported a complication of epidural hematoma requiring a second craniotomy for evacuation in one of the six cases (16%). The authors recommended this bypass procedure in cases of bilateral carotid or vertebral disease or in patients with recurring ischemic events while therapeutically anticoagulated. The patient whose case report we present met both of these criteria and was successfully treated with a minimally invasive endovascular technique.

Endovascular techniques have previously been described in the treatment of VA dissections and pseudoaneurysms, but this has primarily consisted of balloon occlusion (7). Recently, Higashida et al. (9) (1997) reported a case of successful endovascular stenting and coil placement in the treatment of a ruptured fusiform basilar artery aneurysm. Yadav et al. (29) (1997) found elective stenting of the extracranial carotid arteries in 107 patients to be reasonably safe and efficacious in patients with carotid artery stenosis. They reported an initial mean stenosis reduction from 78 to 2%, which was maintained at a mean of 18% at 6-month follow-up examinations and a stroke/mortality incidence of 9%. Endovascular stent placement has been successfully used in the treatment of multiple aneurysms of the extracranial ICA (12) and cervical dissecting aneurysms (11). Recently, Duke et al. (5) (1997) used endovascular stents in the treatment of blunt carotid artery injury. They successfully placed stents in two patients with traumatic cervical ICA dissections. Perez-Cruet et al. (19) reported the successful use of a wall stent and detachable coils in the treatment of a case of pseudoaneurysm of the cervical ICA. There has not been, to our knowledge, the report of a case of successful stent implantation in the treatment of spontaneous cervical carotid dissection.

The risks associated with stent implantation include distal migration or embolization and vessel rupture at the time of stent placement (11) as well as early thrombotic occlusion and late stenosis caused by neointimal hyperplasia (12). Considering the proven efficacy

and cost-effectiveness of noninvasive treatment with anticoagulation and antiplatelet therapy, endovascular or surgical intervention should be considered only in cases of dissection recalcitrant to these modalities or in cases in which anticoagulation is absolutely contraindicated.

The cause underlying our case of multiple spontaneous dissections of the extracranial cerebral circulation remains unknown. Recently, Goldstein et al. (6) (1995) reported a case of spontaneous dissection without angiographic evidence of fibromuscular dysplasia that was subsequently found to have pathologically proven fibromuscular dysplasia. Fibromuscular dysplasia has been reported in 10 to 20% of patients with extracranial ICA dissection and is more commonly associated with bilateral dissection (13, 22). Our case illustrates the successful management of a patient with dissections of all four major extracranial cerebral vessels.

CONCLUSION

Neurovascular stents offer a minimally invasive and potentially efficacious treatment for the prevention of cerebral ischemia secondary to extracranial dissection. Prospective, controlled evaluation of this novel therapeutic modality with long-term follow-up is warranted to elucidate its role as a potential alternative to surgical intervention in patients who remain symptomatic despite anticoagulation.

Received, January 13, 1998.

Accepted, April 20, 1998.

Reprint requests: John A. Wilson, M.D., Department of Neurosurgery, Wake Forest University Baptist Medical Center, Winston-Salem, NC 27157-1029.

REFERENCES

1. Biousse V, D'Ajnglejan-Chatillon J, Touboul PJ, Amarenco P, Boussier MG: Time course of symptoms in extracranial carotid artery dissections: A series of 80 patients. *Stroke* 26:235-239, 1995.
2. Bogousslavsky J, Regli F: Ischemic stroke in adults younger than 30 years of age: Cause and prognosis. *Arch Neurol* 44:479-482, 1987.
3. Bogousslavsky J, Despland P-A, Regli F: Spontaneous carotid dissection with acute stroke. *Arch Neurol* 44:137-140, 1987.
4. Branch CL Jr, Davis CH: False aneurysm complicating carotid endarterectomy. *Neurosurgery* 19:421-425, 1986.
5. Duke BJ, Ryu RK, Coldwell DM, Brega KE: Treatment of blunt injuries to the carotid artery by using endovascular stents: An early experience. *J Neurosurg* 87:825-829, 1997.
6. Goldstein LB, Gray L, Hulette CM: Stroke due to recurrent ipsilateral carotid artery dissection in a young adult. *Stroke* 26:480-483, 1995.
7. Halbach VV, Higashida RT, Dowd CF, Frader KW, Smith TP, Teitelbaum GP, Wilson CB, Hieshima GB: Endovascular treatment of vertebral artery dissections and pseudoaneurysms. *J Neurosurg* 79:183-191, 1993.
8. Hart RG, Easton JD: Dissections of cervical and cerebral arteries. *Neurol Clin* 1:155-182, 1983.
9. Higashida RT, Smith W, Gress D, Urwin R, Dowd CF, Balousek PA, Halbach VV: Intravascular stent and endovascular coil placement for a ruptured fusiform aneurysm of the basilar artery: Case report and review of the literature. *J Neurosurg* 87:944-949, 1997.
10. Lisovoski F, Rousseaux P: Cerebral infarction in young people: A study of 148 patients with early cerebral angiography. *J Neurol Neurosurg Psychiatry* 54:576-579, 1991.
11. Marks MP, Dake MD, Steinberg GK, Norbath AM, Lane B: Stent placement for arterial and venous cerebrovascular disease: Preliminary experience. *Radiology* 191:441-446, 1994.
12. Mase M, Banno T, Yamada K, Katano H: Endovascular stent placement for multiple aneurysms of the extracranial internal carotid artery: Technical case report. *Neurosurgery* 37:832-835, 1995.
13. Milandre L, Perot S, Salamon G, Khalil R: Spontaneous dissection of both extracranial internal carotid arteries. *Neuroradiology* 31:435-439, 1989.
14. Miyamoto S, Kikuchi H, Karasawa J, Kuriyama Y: Surgical treatment for spontaneous carotid dissection with impending stroke. *J Neurosurg* 61:382-386, 1984.
15. Mokri B: Traumatic and spontaneous extracranial internal carotid artery dissections. *J Neurol* 237:356-361, 1990.
16. Mokri B, Houser OW, Sandok BA, Piepgras DG: Spontaneous dissections of the vertebral arteries. *Neurology* 38:880-885, 1988.
17. Morgan MK, Sekhon LHS: Extracranial-intracranial saphenous vein bypass for carotid or vertebral artery dissections: A report of six cases. *J Neurosurg* 80:237-246, 1994.
18. Ojemann RG, Gisher CM, Rich JC: Spontaneous dissecting aneurysm of the internal carotid artery. *Stroke* 3:434-440, 1972.
19. Perez-Cruet MJ, Patwardhan RV, Mawad ME, Rose JE: Treatment of dissecting pseudoaneurysm of the cervical internal carotid artery using a wall stent and detachable coils: Case report. *Neurosurgery* 40:622-626, 1997.
20. Pessin MS, Adelman LS, Barbads NR: Spontaneous intracranial carotid artery dissection. *Stroke* 20:1100-1103, 1989.
21. Pozzati E, Gaist G, Poppi M: Resolution of occlusion in spontaneously dissected carotid arteries: Report of two cases. *J Neurosurg* 56:857-860, 1982.
22. Schievink WI, Bjornsson J, Piepgras DG: Coexistence of fibromuscular dysplasia and cystic medial necrosis in a patient with Marfan's syndrome and bilateral carotid artery dissections. *Stroke* 25:2492-2496, 1994.

23. Schievink WI, Mokri B, O'Fallan WM: Recurrent spontaneous cervical-artery dissection. *N Engl J Med* 330:393-397, 1994.
24. Schievink WI, Piepgras DG, McCaffrey TV, Mokri B: Surgical treatment of extracranial internal carotid artery dissecting aneurysms. *Neurosurgery* 35:809-816, 1994.
25. Six EG, Stringer WL, Cowley AR, Davis CH: Posttraumatic bilateral vertebral artery occlusion: Case report. *J Neurosurg* 54:814-817, 1981.
26. Stringer WL, Kelly DL Jr: Traumatic dissection of the extracranial internal carotid artery. *Neurosurgery* 6:123-130, 1980.
27. Sturzenegger M: Ultrasound findings in spontaneous carotid artery dissection: The value of duplex sonography. *Arch Neurol* 48:1057-1063, 1991.
28. Sturzenegger M: Spontaneous internal carotid artery dissection: Early diagnosis and management in 44 patients. *J Neurol* 242:231-238, 1995.
29. Yadav JS, Roubin GS, Iyer S, Vitek J, King P, Jordan WD, Fisher WS: Elective stenting of the extracranial carotid arteries. *Circulation* 95:376-381, 1997.

COMMENTS

This case shows the usefulness of angioplasty and placement of stents in conditions that otherwise would be very difficult to treat. With results like those reported in this case, one might predict that this technique will be useful in other types of carotid occlusive disease.

Stanley L. Barnwell
Portland, Oregon

This is a fascinating case report of endovascular stent placement in a patient with severe extracranial vascular disease as well as a healthy dose of bad luck. Specifically, this patient presented

with fluctuating neurological deficits referable to the left carotid circulation and was found to have severe occlusion of three vessels (both carotid arteries and a single vertebral artery), after which the remaining vertebral artery was iatrogenically occluded. When heparin therapy failed for this patient, the treating physicians chose to place a series of stents in the offending left internal carotid artery and to pursue a conservative course of treatment for the disease in the remaining vessels. A successful clinical outcome was achieved.

The treatment plan is rational, and the authors achieved a successful outcome of a difficult situation. My single reservation regarding this article is that I cannot be certain that the lesion identified in *Figure 1* is truly a carotid dissection. It may be simply a long segment of atheromatous disease or, as the authors mentioned, fibromuscular dysplasia. This speculation has no bearing on the treatment provided nor on the value of the case report. In cases of carotid dissection in which neurological symptoms persist despite anticoagulant therapy, I think this sort of endovascular approach is reasonable and worthy of a trial.

Christopher M. Loftus
Oklahoma City, Oklahoma

Coric et al. describe a 36-year-old man who presented with presumably spontaneous dissections of all four extracranial vessels (i.e., both internal ca-

rotid arteries and both vertebral systems). Despite maximal medical therapy, he continued to have crescendo neurological events. He was successfully treated with angioplasty and stent placement of these occluded vessels, with excellent clinical outcome.

Currently, carotid artery angioplasty and stenting is an extremely controversial topic for atherosclerotic occlusive disease. However, spontaneous and traumatic dissections of the extracranial carotid and vertebral arteries are most likely an excellent indication for this type of procedure. The reported literature regarding extracranial carotid stenting for occlusive disease indicates an approximately 4% neurological risk per treated artery and, in some series, as high as a 9% neurological risk during the perioperative period. However, the surgical treatment of spontaneous dissections that are recalcitrant to medical therapy have an extremely high morbidity with uniformly poor outcomes. Our opinion is that at many institutions where interventional capabilities exist, this should be the treatment of choice for spontaneous and traumatic dissections. Long-term follow-up is necessary regarding intimal hyperplasia and recurrent stenosis, and as stent technology improves, the hopes are that this procedure will become a primary treatment of this condition, with lasting results.

Robert H. Rosenwasser
Philadelphia, Pennsylvania

Call for Concepts and Innovations Contributions

The *Concepts and Innovations* section has been conceived to establish a new dimension in journalistic presentation. Because of individual variations in the creative mind and the ability to effectively carry ideas through to fruition, many concepts or novel ideas are left "on the shelf" or are unheard because, for one reason or another, individuals do not have the capability to see them through to absolute or practically developed completion.

This section of the *Journal* will offer a forum for all those who wish to present new concepts or ideas related to neurosurgery and neuroscience, as applied to neurological disorders, and will offer the opportunity for the logical and substantive presentation of ideas and novel issues without absolute confirmation within clinical or laboratory sectors.

New concepts with potential application to all foci of practice will be welcomed.