

A Chinese girl with Leigh syndrome: Effect of botulinum toxin on dystonia

TF LEUNG,¹ J HUI,¹ WL YEUNG¹ and K GOH²

Department of Paediatrics¹ and Division of Neurosurgery, Department of Surgery,² The Chinese University of Hong Kong, Prince of Wales Hospital, Hong Kong

Abstract: Leigh syndrome is a form of neurodegenerative disease which is associated with intracranial infarcts. The diagnosis is made by finding hyperlactacidaemia together with cerebral infarcts on neuroimaging. We report a 4-year-old Chinese girl with Leigh syndrome who had several atypical features. She presented with generalized dystonia and developmental regression. In addition, she suffered from an unusual feature of bladder dystonia. This patient appeared to be suffering from respiratory chain complex I deficiency from studies on cultured skin fibroblasts. Assays for respiratory chain enzymes as well as mitochondrial DNA point mutations and major deletions in muscle were normal. Dystonia persisted despite treatments with muscle relaxants and a ketogenic diet. Intramuscular botulinum toxin resulted in significant relief of dystonia.

Key words: bladder dystonia; botulinum toxin; Leigh syndrome; muscle dystonia; respiratory chain complex I deficiency.

Leigh syndrome is characterized by swallowing and respiratory difficulties, spasticity, ataxia, peripheral neuropathy, external ophthalmoplegia, loss of vision, deafness and convulsions. The mean age of onset of clinical features is 1.5 years, with a mean duration of illness until death at 5 years of age.¹ Leigh syndrome can be caused by enzyme deficiencies of pyruvate metabolism and oxidative phosphorylation. Cytochrome c oxidase (respiratory chain complex IV) and respiratory chain complex I deficiencies are the two commonest underlying causes.^{1–5} Cerebrospinal fluid (CSF) lactate is invariably raised in patients with Leigh syndrome and this is best demonstrated on magnetic resonance spectroscopy. The mainstay of treatment for Leigh syndrome is supportive although many drugs has been tried to overcome the metabolic defects.^{1,6}

Respiratory chain complex I is the largest in the electron transport chain and consists of more than 40 polypeptides.^{1,7} The clinical syndrome of complex I deficiency can be classified as myopathy or a multisystem disorder.^{3–6,8,9} The former mainly affects skeletal muscle and rarely also involves myocardium. Smooth muscle is spared in this disease. Patients with multisystem disease usually present in early infancy and die after six months. A smaller group of patients have milder encephalomyopathy in childhood or adulthood.^{3,8,9} Patients typically have hyperlactacidaemia with raised lactate to pyruvate ratios.

Botulinum toxin is an exotoxin secreted by *Clostridium botulinum*. It blocks neuromuscular conduction by binding to receptors on motor nerve terminals, entering the nerve endings and inhibiting the release of acetylcholine. This results in chemical denervation and muscle paralysis.¹⁰ Botulinum toxin

is effective in the treatment of strabismus, blepharospasm, spasmodic torticollis and muscle spasticity or dystonia.^{10–13}

CASE REPORT

A 4-year-old Chinese girl was born at term with uneventful perinatal course. There was no family history of neurological diseases. Her early development was appropriate. At 2 years of age, she presented with features of 'hemiplegic cerebral palsy'. She gradually deteriorated and developed generalized dystonia at 3 years. Ophthalmological assessment was normal. Cranial magnetic resonance imaging showed infarcts in both basal ganglia (Fig. 1) and spectroscopy (MRS) confirmed raised lactate and reduced N-acetylaspartate in these areas. Magnetic resonance angiography and electrophysiological studies were normal. Fasting arterial lactate was 1.6 mmol/L (reference range 0.36–0.75) and pyruvate was 88 μ mol/L (reference range 30–80). Lactate to pyruvate ratio was 18 (normal 11–18). Lactate was 3.1 mmol/L in CSF. Antinuclear antibody, protein C, protein S, serum carnitine and ceruloplasmin were normal. D-penicillamine chelation test showed normal urinary copper excretion. There was no amino or organic acidurias.

Leigh syndrome was the likely diagnosis. Muscle biopsy findings appeared normal with no evidence of ragged red fibres. Muscle was also negative for common mitochondrial DNA point mutations which included MELAS (3243), MERRF (8344), LHON (11778 and 3460) and NARP (8993). Southern blot hybridization did not reveal any major deletion of mitochondrial DNA. Muscle showed normal enzyme activities for respiratory chain complexes I to V. Metabolic studies of cultured skin fibroblasts revealed increased cellular lactate to pyruvate ratio to 158 ± 33 (reference range 13.4 ± 1.7). Assays for pyruvate dehydrogenase, cytochrome oxidase and succinate cytochrome c reductase activities were normal. Pyruvate carboxylase activity was 1.03 nmoles/min/mg protein (control 2.08). There were insufficient fibroblasts to repeat respiratory chain enzyme activities. Another skin biopsy was not indicated just for this reason. In view of clinical picture, elevated lactate to pyruvate ratio and

Correspondence: Dr TF Leung, Division of Immunology and Allergy, The Hospital For Sick Children, 555 University Avenue, Toronto, Ontario, Canada, M5G 1X8. Fax: (416) 813 8638; e-mail: leung2142@cuhk.edu.hk.

TF Leung, MRCP (UK), Assistant Professor. J Hui, FRACP, Senior Medical Officer. WL Yeung, MRCP (UK), Medical Officer. K Goh, FRCS, Medical Officer.

Accepted for publication 28 April 1998.

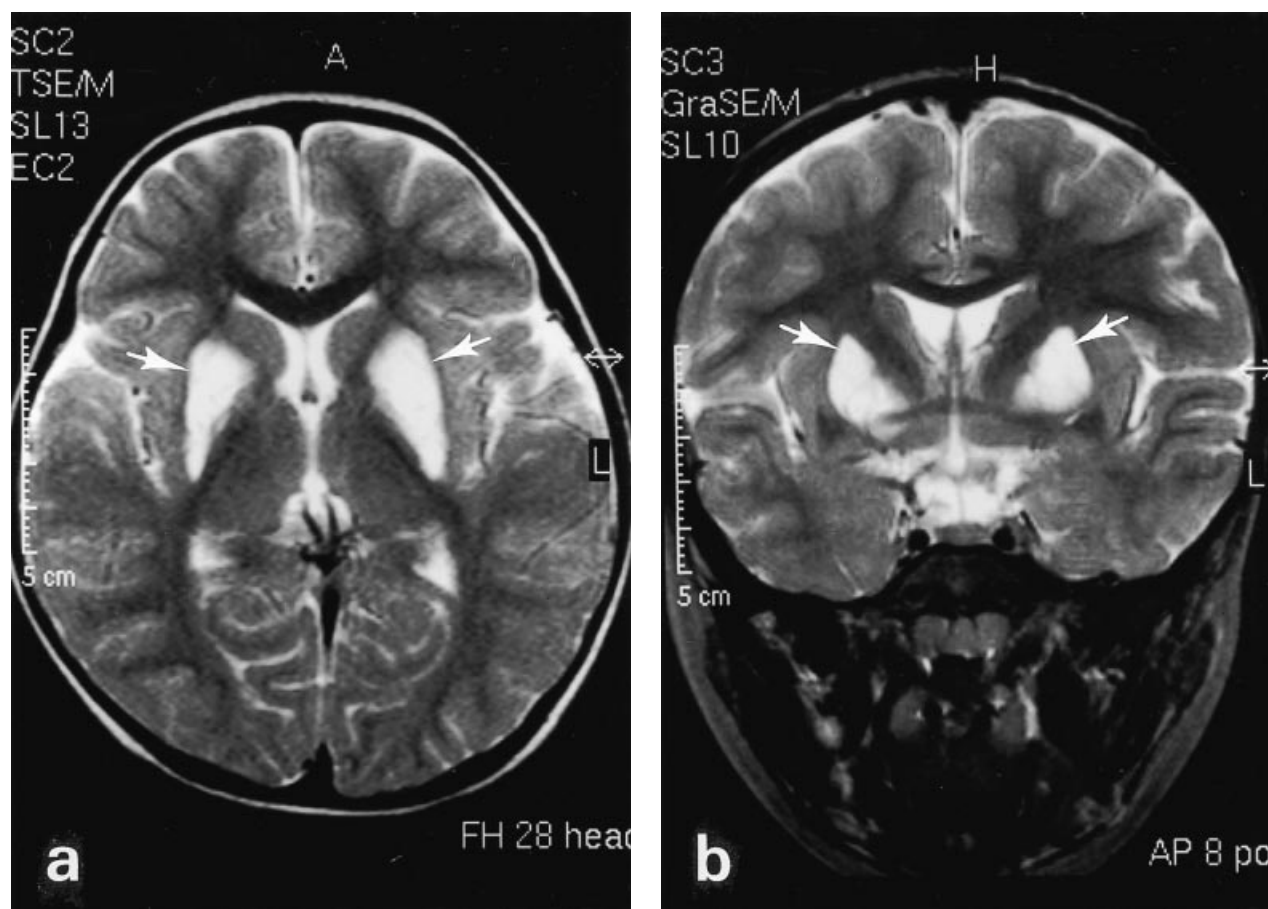


Fig. 1 T2-weighted magnetic resonance images of the brain in cross-sectional (a) and coronal (b) views showing hyperintensities in both basal ganglia which are suggestive of infarcts (white arrows).

available enzyme assays, our patient was deduced to be suffering from Leigh syndrome due to respiratory chain complex I deficiency.

The child did not respond to oral thiamine, baclofen, benzhexol and sinemet. A ketogenic diet was also commenced. She deteriorated and could not sit in a chair despite an improvement in hyperlactacidaemia on follow-up MRS performed six months later.

She was offered intramuscular injections of botulinum toxin (Botox). The rationale for using botulinum toxin was to reduce muscle hypertonia by paralyzing them, thus achieving a better posture for sitting and hygiene care. The dosage was 100–200 units total per session for upper limb muscle groups (biceps, triceps, brachioradialis, pectoralis major) and 200–300 units per session for lower limb muscle groups (quadriceps, hamstrings, adductors, iliopsoas). Injections were repeated in two weeks if no clinical improvement was observed. Ashworth scores for various muscle groups improved from grade 4 or 5 to grade 3 within few days after Botox injections. However, muscles became stiff again in two to three months.

Our patient had unprovoked swelling over her right thigh four months after Botox injection. Ultrasonography showed an intramuscular haematoma in right adductor compartment. Coagulation studies were normal. The cause of this spontaneous haemorrhage was not certain. Later, she developed urinary retention and abdominal ultrasonography revealed distended

urinary bladder with bilateral pelvicalyceal system dilatation. Voiding cystourethrogram was normal. Urodynamic study supported the diagnosis of bladder dystonia.

DISCUSSION

Our patient suffered from Leigh syndrome which was probably caused by respiratory chain complex I deficiency, as evidenced by elevated CSF and blood lactate, raised lactate to pyruvate ratio, typical radiological changes and studies of muscle and cultured skin fibroblasts. There were several interesting features. Firstly, our case showed that respiratory chain enzyme activities can be normal in muscle but impaired in skin fibroblasts. This tissue specificity of enzyme expression has been described previously.^{1,4,6} Secondly, an unusual feature is the detrusor (smooth) muscle involvement resulting in neurogenic bladder which has not been reported before. Thirdly, the patient presented initially with spastic hemiplegia but then developed generalized dystonia. Patients with Leigh syndrome usually have generalized body involvement from the beginning. She also lacked typical features such as seizures, respiratory difficulty and feeding problems.¹ Lastly, our patient had slow progression of disease as compared with the usually fulminant course for other cases.⁶

Oral muscle relaxants were ineffective in our patient. This is usually the situation for mitochondrial diseases. In the few reports of Leigh syndrome due to defective pyruvate metabolism, ketogenic diet resulted in arrest of disease progression.⁶ Our patient showed improvement of hyperlactacidaemia on MRS after the introduction of a ketogenic diet, however, she developed neurogenic bladder while having this special diet.

Another interesting feature in our case was the response to botulinum toxin. It relieves spasticity by inhibiting neuromuscular transmission. In recent years, this drug was increasingly used in treating patients with spasticity^{11,12} and dystonias.¹³ Children with spastic and athetoid types of cerebral palsy also responded to botulinum toxin.¹⁴⁻¹⁶ The main indication is to reduce muscle tone which facilitates better nursing care. However, there is no randomized study on the use of botulinum toxin in children. Our patient showed that botulinum toxin could substantially improve muscle tone in patients with Leigh syndrome.

The dosage of botulinum toxin is influenced by body weight, muscle size, severity of spasticity and the desired response.¹⁰ The initial dose in children is 3-5 units/kg. Our patient improved on 40 units/kg of Botox which was much higher than the recommended dose. Concerning its side-effects, misplaced botulinum toxin can temporarily paralyse other nearby muscle groups. Local irritation over injection sites is also commonly seen.¹⁰ Ten per cent of patients receiving botulinum toxin develop resistance to its effect. No early side-effects was observed after the injection of in our patient. However, she developed spontaneous intramuscular haematoma four months after Botox. This raised the possibility of delayed onset of haemorrhage after Botox injections which definitely warrants close surveillance.

In summary, our patient suffered from Leigh syndrome with severe generalized dystonia. Botulinum toxin resulted in significant alleviation of muscle dystonia. Further studies are required to define its dosage and safety profile in children.

REFERENCES

- Shoffner JM, Wallace DC. Oxidative phosphorylation diseases. In Scriver CR, Beaudet AL, Sly WL, Valle D, eds. *The Metabolic Basis of Inherited Disease*, vol 1, 7th edn. McGraw Hill, New York, 1995; 1535-609.
- Miyabayashi S, Ito T, Narisawa K. Biochemical study in 28 children with lactic acidosis, in relation to Leigh's encephalomyelopathy. *Eur. J. Pediatr.* 1985; **143**: 278.
- Morris AA, Leonard JV, Brown GK et al. Deficiency of respiratory chain complex I is a common cause of Leigh disease. *Ann. Neurol.* 1996; **40**: 25-30.
- Rahman S, Blok RB, Dahl HH et al. Leigh syndrome: clinical features and biochemical and DNA abnormalities. *Ann. Neurol.* 1996; **39**: 343-51.
- Robinson BH, De Meirleir L, Glerum M, Sherwood G, Becker L. Clinical presentation of mitochondrial respiratory chain defects in NADH-coenzyme Q reductase and cytochrome oxidase: clues to pathogenesis of Leigh disease. *J. Pediatr.* 1987; **110**: 216-22.
- De Vivo DC, DiMauro S. Mitochondrial diseases. In Swaiman KF, ed. *Pediatric Neurology—Principles and Practice*, vol 2, 2nd edn. Mosby, St. Louis, 1994; 1335-53.
- Ton C, Hwang DM, Dempsey AA, Liew CC. Identification and primary structure of five human NADH-ubiquinone oxidoreductase subunits. *Biochem. Biophys. Res. Commun.* 1997; **214**: 589-94.
- Pitkanen S, Feigenbaum A, Laframboise R, Robinson BH. NADH-coenzyme Q reductase (complex I) deficiency: heterogeneity in phenotype and biochemical findings. *J. Inher. Metab. Dis.* 1996; **19**: 675-86.
- Robinson BH. Lacticacidemia. *Biochim. Biophys. Acta* 1993; **1182**: 231-44.
- Botox. In Gillis MC, Welbanks L, Bergeron D, eds. *Compendium of Pharmaceuticals and Specialties*, 32nd edn. Canadian Pharmaceutical Association, Ottawa, 1997; 194-7.
- Pierson SH, Katz DI, Tarsy D. Botulinum toxin A in the treatment of spasticity: Functional implications and patient selection. *Arch. Phys. Med. Rehabil.* 1996; **77**: 717-21.
- Snow BJ, Tsui JKC, Bhatt MH, Varelas M, Hashimoto SA, Calne DB. Treatment of spasticity with botulinum toxin: A double blind study. *Ann. Neurol.* 1990; **28**: 512-5.
- Yoshimura DM, Aminoff MJ, Olney RK. Botulinum toxin therapy for limb dystonias. *Neurology* 1992; **42**: 627-30.
- Cosgrove AP, Corry IS, Graham HK. Botulinum toxin in the management of the lower limb in cerebral palsy. *Dev. Med. Child Neurol.* 1994; **36**: 386-96.
- Gooch JL, Sandell TV. Botulinum toxin for spasticity and athetosis in children with cerebral palsy. *Arch. Phys. Med. Rehabil.* 1996; **77**: 508-11.
- Koman CA, Modney JF, Smith B, Goodman A, Mulvaney T. Management of cerebral palsy with botulinum-A toxin: preliminary investigation. *J. Pediatr. Orthop.* 1993; **13**: 489-95.