

## A 67-Year-Old Woman with Polymyalgia Rheumatica and Left Hemispatial Neglect

**J. Paul Mahfood, MD**  
Division of Rheumatology  
Department of Internal  
Medicine  
University of South Florida  
Tampa, FL

**Michael Gold, MD**  
Department of Neurology  
University of South Florida

**Americo Gonzalvo, MD**  
Department of Pathology  
University of South Florida

**Joanne Valeriano-Marcet, MD**  
Division of Rheumatology  
Department of Internal  
Medicine  
University of South Florida

### ABSTRACT

A 67-year-old woman with a diagnosis of polymyalgia rheumatica presented initially with periods of confusion and incontinence. A CT scan of the brain was normal and she was treated with tapering doses of corticosteroids and clinical improvement. After a brief period off steroids, the patient presented with a progressive dementia, left-sided clumsiness, gait disturbances and left hemispatial neglect. An MRI at this time demonstrated a large area of edema over the right parietal lobe and intense cortical enhancement. A chest CT demonstrated multiple nodules. Biopsies of the lung and brain failed to identify any infectious organisms or malignant tissue. The leptomeningeal biopsy revealed multiple granulomatous areas with central necrosis and histiocytic cells consistent with idiopathic hypertrophic pachymeningitis.

Key words: polymyalgia rheumatica, neglect, chronic meningitis, MRI.

Mahfood JP, Gold M, Gonzalvo A, Valeriano-Marcet J. A 67-year-old woman with polymyalgia rheumatica and left hemispatial neglect. *J Neuroimaging* 1998;8:222-227

A 67-year-old woman was diagnosed with polymyalgia rheumatica (PMR) and temporal arteritis (TA) at age 62 based on fatigue, polymyalgia, proximal muscle stiffness, unilateral temporal headache, and elevated erythrocyte

sedimentation rate (ESR). Bilateral temporal artery biopsies and head computed tomography (CT) were both negative. High-dose corticosteroids were associated with clinical improvement, and the patient was continued on chronic corticosteroid therapy with variable dose adjustments in response to symptomatic flare-ups. She did not receive disease-modifying antirheumatic drugs and had no prior history of connective tissue diseases. Concurrent medical problems included type II noninsulin-dependent diabetes diagnosed in 1991, hypertension, and osteoporotic vertebral fractures. Past surgeries included total hysterectomy at age 48 and thyroidectomy at age 54.

In May 1995 she experienced episodes of confusion and bladder incontinence for which a brain CT, with and without contrast, was reported to be normal. She was tapered off corticosteroids in August 1995 following stable clinical improvement and stabilization. Magnetic resonance imaging (MRI) with contrast, performed 1 month later, was compared with the previous CT and revealed no mass lesions or abnormal enhancement. An ophthalmologist reported no evidence of retinal degeneration, optic neuropathy, or any symptoms of TA. While temporarily off corticosteroids she presented to a neurologist with symptoms of mild, unexplained weight loss, gait imbalance, left-side weakness, clumsiness of her hands, variable cognitive deficits, myalgia, and fatigue. Examination revealed an amnesic disorder, anomia, ideomotor praxis, preservative behaviors, and left hemispatial neglect on line bisection and target cancellation tasks. The cranial nerves were normal except for extinction to double simultaneous visual stimulation. The tone of the left arm was increased and a subtle weakness was difficult to dissociate from motor intentional neglect. No extrapyramidal features were noted. Fine touch and pinprick were diminished on the right upper arm without a radicular pattern. There was extinction to double simultaneous extinction to left-side stimuli.

Received Feb 5, 1997, and in revised form Mar 27, 1998. Accepted for publication Mar 29, 1998.

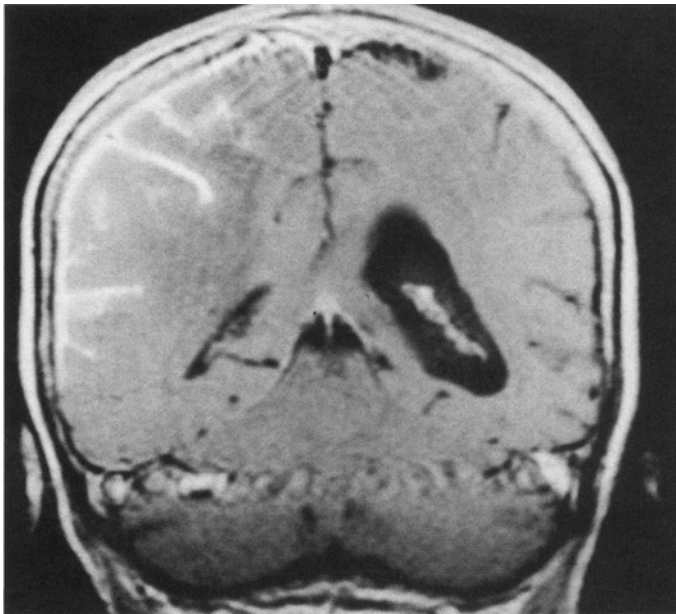
Address correspondence to Dr Gold, University of South Florida College of Medicine, Department of Neurology MDC 55, 12901 Bruce B. Downs Boulevard, Tampa, FL 33612.

Deep tendon reflexes were brisker on the left upper and lower extremities.

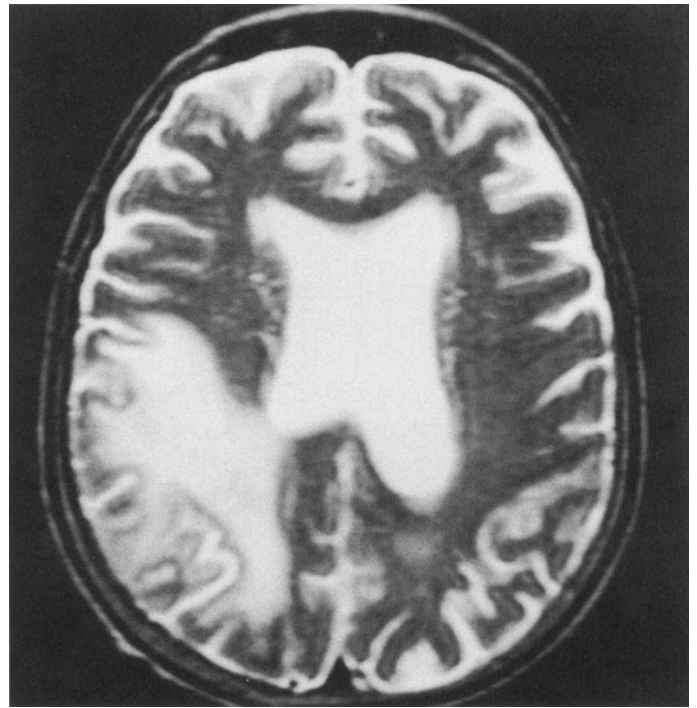
Corticosteroid therapy was resumed prior to referral to a rheumatologist, who reported a normal medical examination. Outpatient laboratory evaluations revealed Wintrobe ESR, 47 mm per hour; hemoglobin, 14.4 g per deciliter; white blood cell count, 21,000 per cubic millimeter; platelet count, 292,000 per cubic millimeter; normal thyroid function tests; and absent rheumatoid factor and antinuclear antibodies. The patient was admitted to the hospital, where another MRI was performed, and she underwent a comprehensive evaluation. Laboratory tests, including a hemogram, serum electrolytes, antibody serologies, and an angiotensin converting enzyme level, were all normal, with the exception of a slightly elevated ESR (38 mm per hour). She was placed on corticosteroid therapy with improvements in her left-side weakness and left hemispatial neglect for several days. Because of the multiple nodules noted on chest CT, which were suspicious for a malignancy, a lung biopsy was performed and was followed by an open brain biopsy. No lumbar puncture was attempted because of the mass effect noted on MRI. She remained clinically stable on a tapering dose of steroids until her death several months later following a complicating episode of pancreatitis and pneumonia. The family refused an autopsy.

#### Radiological Description

Brain MRI (Figs 1–3) with and without contrast material shows extensive and patchy leptomeningeal enhancement extending over the right temporal, right occipital, and

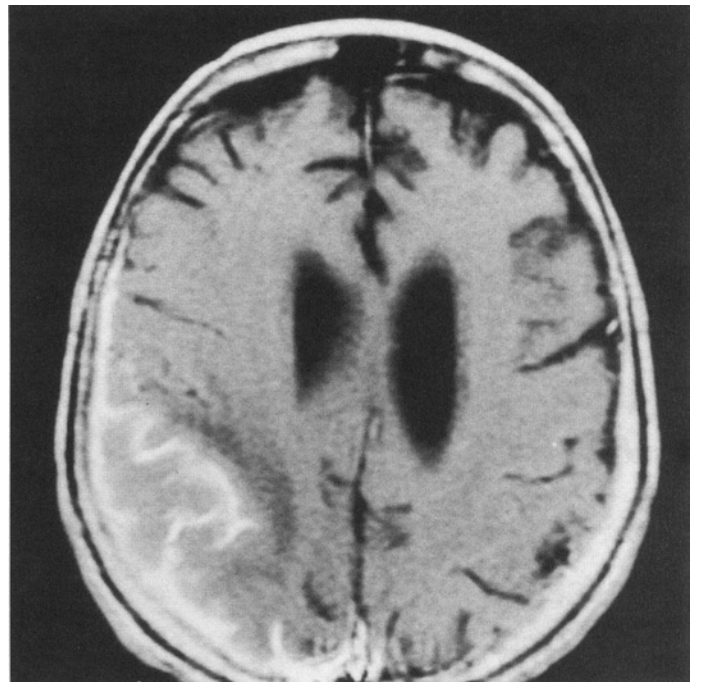


**Fig 1.** Coronal T1-weighted magnetic resonance image following intravenous gadolinium demonstrating diffuse cortical enhancement peripherally of the right parietal lobe.



**Fig 2.** Axial T2-weighted magnetic resonance image without contrast demonstrating diffuse edema primarily involving the white matter of the right parietal lobe.

right parietal lobes. Increased T2-weighted signals are seen in the right posterior temporal and right posterior parietal regions within the subcortical and deep white matter. The increased signal, compatible with vasogenic



**Fig 3.** Axial T1-weighted magnetic resonance image following intravenous gadolinium demonstrating diffuse cortical enhancement of the right parietal lobe with slight mass effect and edema. Note the absence of ring-enhancing or focal intracranial lesions.

edema, was associated with effacement and compression of the right lateral ventricular body, posterior lateral horn, and occipital horn. A 3-mm midline shift to the left was noted. No abnormal enhancement was seen in the left hemisphere. There was no evidence of tentorial herniation. An increased periventricular T2 signal was present posterior to the left lateral ventricle and posterior horn, suggestive of chronic microvascular changes. In addition, diffuse cortical atrophy and extensive atrophy of both medial temporal lobes were noted.

Chest CT with and without contrast showed multiple calcified focal nodules in both lung fields from the apex to the base, most of which appeared to be pleural and subpleural against a background of chronic obstructive lung disease. No hilar adenopathy was noted. Abdominal and pelvic CT was normal. A diagnostic lung biopsy was performed initially and was then followed by an open brain biopsy. No lumbar puncture was attempted because of the mass effect noted on MRI.

### Neurological Differential Diagnosis

This patient had a 4-year history of a rheumatological process with corticosteroid treatment antedating the onset of neurological problems by a period of 4 years, during which she was treated with corticosteroids. Her initial presentation was episodic confusion and incontinence, raising the possibility of an epilepsy or repeated near-syncopal events. There was no report of any focal signs during or following these episodes. She was weaned off steroids and then developed a gradual loss of cognitive skills along with a poorly characterized "clumsiness" of her left side. On mental status examination, she demonstrated left hemispatial neglect on exploratory tasks (line bisection and target cancellation) and on perceptual tasks (double simultaneous stimulation), indicating a lesion of the right parietal lobe. In addition, deficits were noted in verbal memory, object naming, and ideomotor apraxia, indicating deficits in the left parietotemporal region. Her elemental examination suggested an upper motor neuron-type lesion based on the clumsiness and weakness of the left arm.

The differential diagnosis is quite broad and is complicated by her previous medical problems. The pattern of involvement suggests a multifocal intracranial process that became more clearly manifest after she stopped taking steroids.

One way to approach the differential diagnosis is to hypothesize that the patient's new signs and symptoms were related to her recent discontinuation of steroids. A brief, noninclusive differential diagnosis is presented in Table 1, and revolves around neoplastic, infectious, and inflammatory conditions. The lack of a primary tumor and a negative biopsy of the lung nodules and the brain make a neoplasm unlikely. Likewise, the failure to identify or

Table 1. Brief Differential Diagnosis

Diagnoses	Symptoms
Neoplastic	Lymphoma, carcinomatous meningitis (small-cell carcinoma), dural-based metastases (melanoma), dural-based primary tumor of the central nervous system
Infectious	Fungal ( <i>Aspergillus</i> , coccidioidomycosis), parasitic (cystocercosis, amoebic), mycobacterial, luetic/borreliosis
Inflammatory	Vasculitis (SLE,PAN), sarcoidosis
Cardiovascular disease	Hypertensive lipohyalinosis, diabetic microangiopathy

SLE = systemic lupus erythematosus; PAN = polyarteritis nodosum.

culture organisms from either lung or brain tissue makes a chronic infection unlikely. This leaves a chronic inflammatory condition such as sarcoidosis as the most likely cause of our patient's focal signs and symptoms.

This patient also had medical complications from chronic steroid use (diabetes mellitus and hypertension), which could have caused cerebrovascular disease and the development of vascular dementia. The lack of transient ischemic attacks or abrupt decline in cognition would argue against this option. Although there was no evidence for systemic vasculitis, the patient could have an isolated central nervous system (CNS) vasculitis that became active as the steroids were tapered. MRI did not reveal cerebrovascular disease in the appropriate topology to account for all the patient's signs and symptoms. Meningeal enhancement is associated with the acute stages of cerebral ischemia but does not result in a hypertrophic meningitis, thereby making microvascular ischemic disease or vasculitis unlikely explanations.

Alternatively one can consider processes that are unrelated to the use of steroids. A brief differential diagnosis is presented in Table 2. Although the patient's mental status examination and clinical presentation meet the criteria for dementia, the focal motor findings and left hemispatial neglect suggest a structural lesion, which makes a primary degenerative process unlikely as the sole explanation.

The vasogenic edema and mass effect on MR images suggest that the differential diagnosis can be narrowed

Table 2. Another Brief Differential Diagnosis

Mechanism	Diagnosis
Degenerative	Alzheimer's disease, frontotemporal dementia, Pick's disease
Amyloidosis	Creutzfeldt-Jakob disease, cerebral amyloidosis
Vascular	Arteriovenous malformation
Congenital	Phakomatoses

down to a neoplastic lesion, and an infectious or inflammatory process. Contrast enhancement did not reveal a nidus underlying the edema, but instead revealed tremendous meningeal enhancement. Although CSF analysis might be helpful, pleocytosis, abnormal cytology, and elevated protein levels are found with neoplasm, chronic infection, and chronic inflammation, thereby limiting its specificity. We believed that the most probable etiology was a chronic infection. A brain biopsy is needed to differentiate between the remaining possibilities.

### Pathological Description

The gross biopsy specimen of the left lower lung measured  $5.0 \times 2.5 \times 2.0$  cm. Histological examination revealed multiple granulomatous areas with central necrosis, peripheral palisades, and numerous clear cells with the appearance of histiocytes (Fig 4). Gram's stain, and special fungal and acid-fast bacilli (AFB) stains were negative. There was no evidence of malignancy or vasculitis.

The open brain biopsy specimen measured  $1.2 \times 0.6 \times 0.3$  cm. Histological examination showed cerebral cortex with overlying arachnoidal membrane. The arachnoid membrane revealed fibrous thickening and was infiltrated by abundant chronic inflammatory cells, especially plasma cells and numerous foamy histiocytes. There were non-caseating granulomatous lesions with a necrotic center surrounded by palisading histiocytes and a few multinucleated giant cells. The arteries encased in the fibrous process showed intimal thickening without evidence of vasculitis. The underlying parenchyma showed mild reactive astrogliosis in the superficial layers of the cerebral cortex. The fibrotic and inflammatory process extended along the

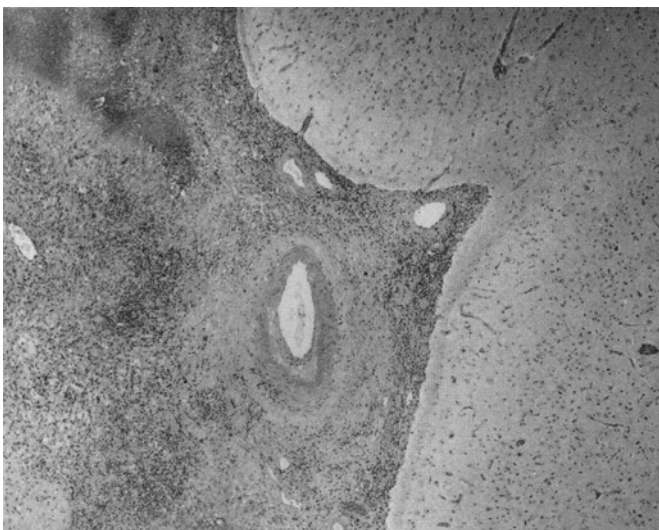
Virchow-Robin space into the superficial cerebral cortex. Fungal and AFB stains were negative, and there was no evidence of malignancy (Fig 5). A pathological diagnosis of idiopathic hypertrophic cranial pachymeningitis (IHCP) was rendered.

### Discussion

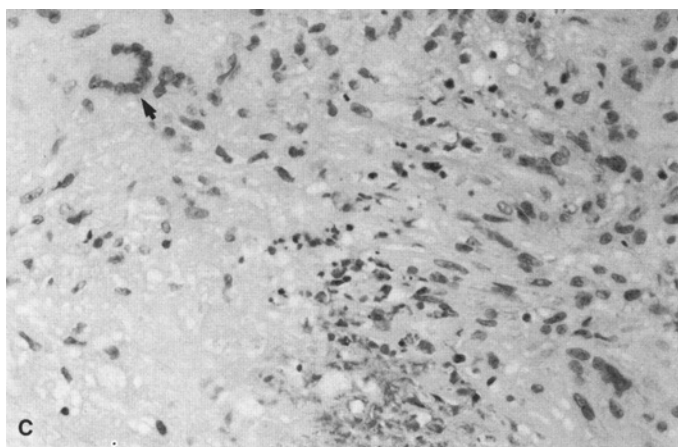
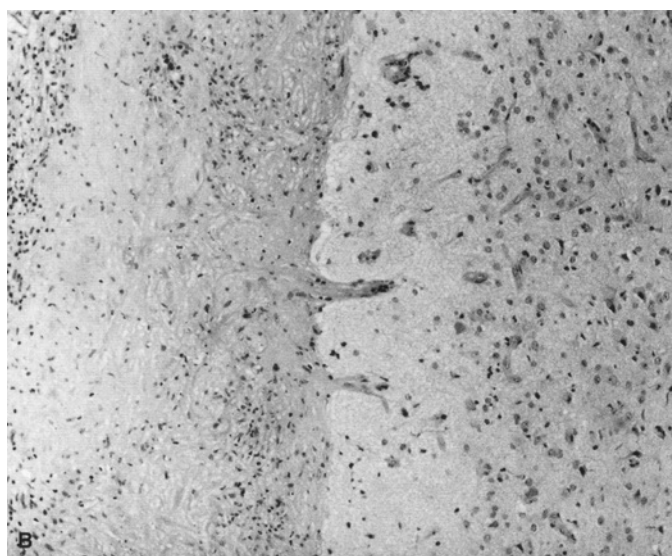
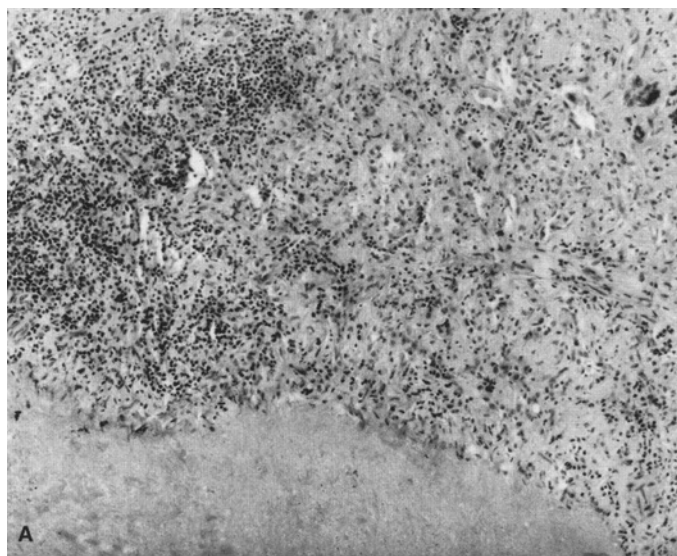
First described by Charcot and Joffroy in 1869 (cited in Smith and Aksamit<sup>1</sup>), IHCP is a rare disease of unknown cause with diverse clinical, laboratory, and radiographic manifestations suggesting a multifactorial etiology. Later patient reports have described an intracranial process with chronic inflammation of the dura mater leading to diffuse thickening and fibrosis of the meninges that can interfere with normal CNS function.<sup>2</sup> IHCP may involve the cerebral parenchyma, cranium, and extracranial soft tissue.<sup>3</sup> It is a diagnosis of exclusion, with a broad differential diagnosis that includes a variety of spinal<sup>4-7</sup> and cranial infections<sup>4,8-12</sup> due to multiple organisms, as well as noninfectious etiologies such as neoplasm, vasculitis, rheumatoid pachymeningitis, sarcoidosis, and chronic cerebral vascular stasis or accidents.<sup>13-26</sup> IHCP has also been associated with chronic dialysis,<sup>27</sup> undifferentiated connective tissue disease,<sup>14</sup> and hydrocephaly with myocarditis, raising the question of an autoimmune mechanism linking IHCP with myocarditis.<sup>28</sup>

Unique features in our patient include radiographic evidence of a mass effect in the absence of structural lesions, association with PMR, absence of cranial nerve involvement, and rheumatoid nodulelike lesions noted on brain and lung biopsies in the absence of rheumatoid arthritis (RA) or serological evidence of rheumatoid factor and antinuclear antibodies. Rheumatoid nodules of the brain and leptomeninges are a rare finding and have only been reported in patients with deforming RA<sup>29</sup> or nondeforming RA.<sup>30</sup> Brain involvement is generally recognized histologically by the formation of rheumatoid nodules.<sup>31,32</sup>

Cheng and colleagues<sup>33</sup> reported the clinical, laboratory, radiographic, and pathological features of 37 patients diagnosed with IHCP during an 8-year period and found that the most common etiologies were sarcoidosis (31%) and metastatic adenocarcinoma (25%). The specific etiology remained undetermined in 44% of patients in their series. Their study indicated that MRI is the preferred neuroimaging modality, that a biopsy of an enhancing lesion is likely diagnostic, and that a posterior fossa or pterional approach gives the greatest diagnostic yield. Mamelak et al<sup>2</sup> reported 3 patients with IHCP and noted that headache and cranial nerve findings were the most common symptoms occurring in 100% and 78% of patients respectively. Masson et al<sup>15</sup> reported 7 patients with IHCP whose primary clinical findings were headache, ataxia, and cranial nerve palsies. Their CSF analysis revealed variable inflammatory changes without evidence of microorgan-



**Fig 4.** Section from the left lower lobe of lung showing extensive areas of necrosis (*lower left corner*) and chronic granulomatous inflammation with multinucleated giant cells, without evidence of vasculitis or malignancy. No microorganisms were identified with special stains (H&E, original magnification  $\times 100$  before 86% reduction).



**Fig 5.** (A) Section of brain with overlying leptomeninges that are markedly thickened and fibrotic. Multiple granulomas with chronic inflammatory infiltrate and focal areas of necrosis are seen. No microorganisms were identified with special stains (H&E, original magnification  $\times 40$  before 88% reduction). (B) Medium-power magnification confirms leptomenigeal thickening with prominent chronic inflammation and scattered giant cells. Underlying brain reveals marked reactive changes (H&E, original magnification  $\times 100$  before 88% reduction). (C) High-power view of the granuloma illustrates necrosis in the center of the granuloma (lower left corner), with palisading epithelioid histiocytes and lymphocytes. A single, large multinucleated giant cell is seen in the left upper corner (H&E, original magnification  $\times 400$  before 58% reduction).

isms or malignancy. Histological examination of the leptomeninges in 5 patients revealed a cellular infiltrate of polymorphic cells without epithelioid granuloma. Four of these patients responded to corticosteroid therapy. A study<sup>1</sup> of 49 patients with IHCP followed for 12 years found that in 15% of patients an etiology, usually malignancy, was eventually identified. The most useful empiric therapy in this group was also corticosteroids. In general, an initial clinical response to corticosteroid therapy is expected to occur in as many as 50% of patients,<sup>1</sup> despite subsequent progression of the disease.<sup>2</sup> Combination therapy with corticosteroid and cyclophosphamide has been used successfully when Wegener's granulomatosis was the etiology of IHCP.<sup>17</sup> Spontaneous resolution has also been reported<sup>34</sup> but is not the usual course.

We believe this patient illustrates the first reported association between IHCP and PMR with evidence of mass effect and rheumatoid nodulelike lesions in the CNS in the absence of RA, rheumatoid factor, or antinuclear antibodies. High-dose corticosteroid therapy reversed her focal neurological symptoms and led to resolution of the mass effect. Although patients with AD may develop focal findings as part of the natural progression of the disease, ad-

ditional pathological processes such as vascular, infectious, neoplastic, and, as in this patient, inflammatory diseases can be expected to develop in some of these patients. Clinicians need to remain alert to the development of focal or atypical features in patients with dementia.

## References

1. Smith JE, Aksamit Jr AJ. Outcome of chronic idiopathic meningitis. *Mayo Clin Proc* 1994;69:548-556
2. Mamelak AN, Kelly WM, Davis RL, Rosenblum ML. Idiopathic hypertrophic cranial pachymeningitis. Report of three cases. *J Neurosurg* 1993;79:270-276
3. Kadoya C, Soejima T, Yamada H, Yokota A. Pachymeningoencephalitis: case report. *Neurosurgery* 1993;33:131-134
4. Murai H, Kira J, Kobayashi T, et al. Hypertrophic cranial pachymeningitis due to *Aspergillus flavus*. *Clin Neurol Neurosurg* 1992;94:247-250
5. Berenguer J, Diaz-Mediavilla J, Urra D, Munoz P. Central nervous system infection caused by *Pseudallescheria boydii*: case report and review. *Rev Infect Dis* 1989;11:890-896
6. Carli P, Yao N, Marlier S, et al. Febrile cervicalgia caused by *Streptococcus milleri* external pachymeningitis. *Presse Med* 1993;22:33 (Letter)
7. Bucy PC, Freeman W. Hypertrophic spinal pachymeningitis. *J Neurosurg* 1952;15:22-27
8. Nishioka R, Nakajima S, Morimoto Y, et al. Hypertrophic

- cranial pachymeningitis with *Propionibacterium acnes* detected by dural biopsy. *Rinsho Shinkeigaku* 1995;35:526–530
9. Leiberman A, Tovi F, Hirsch M. Pachymeningitis presenting features of posterior sinus infection. *Eur J Pediatr* 1986;144:583–585
  10. Kawano Y, Kira J. Chronic hypertrophic cranial pachymeningitis associated with HTLV-I infection. *J Neurol Neurosurg Psychiatry* 1995;59:435–437
  11. Gorell JM, Palutke WA, Chason JL. *Candida* pachymeningitis with multiple cranial nerve pareses. *Arch Neurol* 1979;36:719–720
  12. Taveras MJ. *Neuroradiology*. New York: Williams & Wilkins, 1996:738
  13. Ranoux D, Devaux B, Lamy C, Mear JY, Roux FX, Mas JL. Meningeal sarcoidosis, pseudo-meningioma, and pachymeningitis of the convexity. *J Neurol Neurosurg Psychiatry* 1992;55:300–303
  14. Fujimoto M, Kira J, Murai H, et al. Hypertrophic cranial pachymeningitis associated with mixed connective tissue disease; a comparison with idiopathic and infectious pachymeningitis. *Intern Med* 1993;32:510–512
  15. Masson C, Henin D, Hauw JJ, et al. Cranial pachymeningitis of unknown origin: a study of seven cases. *Neurology* 1993;43:1329–1334
  16. Larnaout A, Haddad M, Hentati F, Ben Hamida M. *Candida albicans* meningitis and neurosarcoidosis. *Rev Neurol (Paris)* 1992;148:762–766
  17. Ghilain S, Delreux V, Kevers L, Sindic CJ, Mathurin P, Laterre EC. Multiple cranial nerve involvement associated with tentorial pachymeningitis of granulomatous type. *Acta Neurol Belg* 1988;88:91–100
  18. Stern BJ, Krumholz A, Johns C. Sarcoidosis and its neurological manifestations. *Arch Neurol* 1985;42:909–917
  19. Radziwill A, Weder B. Neurosarcoidosis of the central nervous system. Analysis of the long term follow-up of 8 cases. *Nervenartz* 1995;66:915–922
  20. O'Duffy JD, Goldstein JP. Neurologic involvement in seven patients with Bechet's disease. *Am J Med* 1976;61:170–178
  21. Olson ME, Chernik NL, Posner JB. Infiltration of the leptomeninges by systemic cancer. *Arch Neurol* 1974;30:122–137
  22. Moore PM, Calabrese LH. Neurological manifestations of systemic vasculitides. *Semin Neurol* 1994;14:300–306
  23. Caselli RJ, Scheithauer BW, O'Duffy JD. Chronic inflammatory meningoencephalitis should not be mistaken for Alzheimer's disease. *Mayo Clin Proc* 1993;68:846–853
  24. Gutman L, Hable K. Rheumatoid pachymeningitis. *Neurology* 1963;13:901–903
  25. Pou SA, Maso E, Roquer J. Isolated angiitis of the central nervous system. Clinical and neuropathological study of 2 cases. *Rev Neurol (Paris)* 1995;151:258–266
  26. Eguchi K, Kodama Y, Hotta T, et al. A case of cranial hypertrophic pachymeningitis with intracranial hemorrhage. *No To Shinkei* 1996;48:475–480
  27. Feringa ER, Weatherbee L. Hypertrophic granulomatous pachymeningitis causing progressive blindness in a chronic dialysis patient. *J Neurol Neurosurg Psychiatry* 1975;38:1170–1176
  28. Tanaka M, Suda M, Ishikawa Y, Fujitake J, Fujii H, Tatsuoka Y. Idiopathic hypertrophic cranial pachymeningitis associated with hydrocephalus and myocarditis: remarkable steroid-induced remission of hypertrophic dura mater. *Neurology* 1996;46:554–556
  29. Bathon JM, Moreland LW, DiBartolomeo AG. Inflammatory central nervous system involvement in rheumatoid arthritis. *Semin Arthritis Rheum* 1989;18:258–266
  30. Karam NE, Roger L, Hankins LL, Reveille JD. Rheumatoid nodulosis of the meninges. *J Rheumatol* 1994;21:1960–1963
  31. Markenson JA, McDougal JS, Tsairis P. Rheumatoid meningitis: a localized immune process. *Ann Intern Med* 1979;90:786–789
  32. Kim RC, Collins GH. The neuropathology of rheumatoid disease. *Hum Pathol* 1981;12:5–15
  33. Cheng TM, O'Neill BP, Scheithauer BW, Piepgras DG. Chronic meningitis: the role of meningeal or cortical biopsy. *Neurosurgery* 1994;34:590–595
  34. Nishio S, Morioka T, Togawa A, et al. Spontaneous resolution of hypertrophic cranial pachymeningitis. *Neurosurg Rev* 1995;18:201–204