

Management of a ruptured cerebral aneurysm in infancy. – Report of a case of a ten-month-old boy

Swen Hülsmann^{1,2}, Dag Moskopp², and Hansdetlef Wassmann²

¹Department of Physiology and Pathophysiology, University of Göttingen,

²Department of Neurosurgery, University of Münster, Germany

Abstract

A ten month old unconscious boy with hemiplegia (Hunt and Hess IV) was first admitted to a district hospital without a CT scanner or a neurosurgical service (Glasgow-Coma-Score 4, no pathological pupillary signs). Therefore, he was transferred to the Pediatric Department of the University Hospital the same night. An emergency CT scan that night showed intracerebral and subarachnoid hemorrhage with enlarged ventricle (Fisher grade 5). Angiography was not available within reasonable time. Thus in the stage of progressively increasing clinical deterioration, still without pupillary signs, an external ventricular drainage was placed. Immediately after reduction of the cerebrospinal fluid volume, arterial hypertension was noticed – the right pupil was mydriatic and fixed. Without further apparative diagnosis an emergency craniotomy was performed for decompression under the suspicion of a secondary hemorrhage due to a reupture of a middle cerebral artery aneurysm. A bleeding aneurysm of the right middle cerebral artery was found and clipped. A mass transfusion was necessary and a pulmonary air embolism occurred. The infant died in tabula. The histological specimens revealed disruption of the internal elastic membrane of both MCA. This emphasizes a congenital nature of the aneurysm.

We conclude that cerebral arterial aneurysms have to be considered in the differential diagnosis of stroke-like symptoms in infancy and early childhood, although the incidence of reported cases is less than one case per year. Since no valid screening parameter is available, diagnosis is often made only after rupture of the aneurysm. This causes problems for emergency management. Infants and children with stroke or stroke-like symptoms should immediately be transferred to a hospital with a neurosurgical unit.

Keywords: Cerebral pediatric aneurysm, emergency management, fibromuscular dysplasia, infancy and early childhood, subarachnoid hemorrhage.

1 Introduction

Intracranial aneurysms in infancy and early childhood are rare. The number of reported new cases is less than one case per year. 0.005 to 2 % of all diagnosed aneurysms are in children [8, 34, 39]. Therefore, most neurosurgeons have little experience with those cases and treatment of infants with a subarachnoid hemorrhage due to the rupture of cerebral arterial aneurysms is not as well standardized as for adults. Important problems may occur in the choice of the right treatment and early radiological diagnosis. Consequences for relatives of patients and screening measures have to be discussed.

2 Case report

A boy was born as the second child of healthy parents. His brother, 3 1/2 years old, was known to be healthy with normal development. The boy was born after an uncomplicated and uneventful 40-week-pregnancy. Delivery was uneventful, he weighted 3100 g (50 % percentile), was 52 cm large (50 %) and the circumference of his head was 36 cm (75 %). The Apgar-score was 9/10/10. The immediate postnatal period was normal. After a few weeks the mother noticed a “trembling of the eyes”. The nystagmus was of small amplitude and diminished on gazing to either side. A consulted ophthalmologist could not find any anatomical abnormalities and classified the nystagmus as congenital. At the same time a mild divergent strabismus of the right eye was noticed and treated with occlusion. The nystagmus persisted. The child had relapsing nonspecific infection of the upper respiratory tract. At the age of 9 month he was brought to the Pediatric Department.

Head circumference was 47 cm (50 % percentile), weight 8100 g (25–50 %). The psychomotoric development was retarded without focal neurological deficit. The parachute reaction was not normal. His roll over movements were still uncoordinated and laborious, he could not sit without support. An EEG was normal.

Suddenly at ten months the boy was found unconscious, with left-sided hemiplegia. He had vomited. He was transported initially to a small hospital, where no CT-scanner was available. On admission there, the child was unconscious and had left-sided hemiplegia. He was breathing spontaneously. The pupils were the same size, round, and reactive to light. The patient showed right-sided spontaneous movements and posturing (Glasgow Coma Score (GCS 4)).

For a CT scan the boy had to be transferred to the pediatric department of our hospital. The computerized tomography scan of the head showed massive subarachnoid and intracerebral hemorrhage (Fisher grade 5) [11] with ventricular hemorrhage and cerebral midline shift, brain edema and hydrocephalus (Figures 1 and 2). The hematoma of the right sylvian fissure suggested an arterio-venous-malformation or a ruptured aneurysm. At this point the patient was presented to us. We saw a comatose infant with left sided hemiplegia, breathing spontaneously and showing spontaneous movements on the right side, still without pupillary signs (GCS 4). Since angiography was not available within reasonable time, we decided to place an external ventricular drainage to gain time in a stage of progressively increasing intracranial pressure.

An external ventricular drainage was placed. Immediately after reduction of the cerebrospinal fluid volume arterial hypertension was noticed – the right pupil was mydriatic and fixed. Under the suspicion of a secondary hemorrhage due to a rerupture of the aneurysm we performed an emergency craniotomy for decompression without further apparative diagnosis. A bleeding aneurysm of the right middle cerebral artery was found and clipped with three Sugita-clips. The blood loss during surgery was massive and required transfusion of 5 erythrocyte concentrates and 1000 ml of fresh frozen plasma. During the course of surgery a pulmonary artery embolism occurred. The patient became hypotensive and hypothermic. Although volume was replaced and catecholamines were given he finally suffered metabolic failure. All efforts of resuscitation were unsuccessful.

A postmortem examination was performed. The macroscopy of the CNS revealed an extraordinarily edematous brain with subarachnoid and intraventricular hemorrhage. A saccular aneurysm of the right middle cerebral artery (MCA) was confirmed with the clips in correct place. No further macroscopic changes or aneurysms of cerebral vessels were found. Additionally, the autopsy revealed acute congestive right heart failure and dilatation of the pulmonary artery, consistent with a pulmonary air embolism and hemorrhagic shock signs. An acute catarrhal bronchitis and bilateral cryptochidism was noticed.

The microscopy of the circle of Willis showed focal proliferations of the intima with segregation and dis-

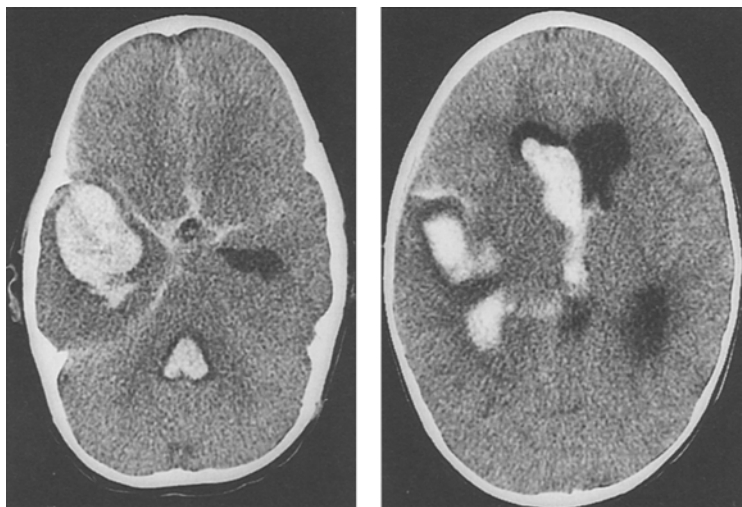


Figure 1. Computerized tomography scan from a ten-month-old boy presenting with loss of consciousness and hemiplegia. It shows the extension of subarachnoid and intracerebral hemorrhage on admission to the university hospital. The ventricular hemorrhage extended into the fourth ventricle.

Figure 2. A second slice of the CT scan from a ten-month-old boy presenting with loss of consciousness and hemiplegia. The ventricular hemorrhage is in the right lateral and third ventricle. There is also evidence of brain edema and occlusion hydrocephalus.

ruption of the internal elastic membrane (IEM). These changes were found bilaterally in the MCA. Further aneurysmatic dilatations or aneurysms in a nascent state were not seen.

3 Discussion

Intracranial aneurysms are rarely reported in children and especially in infancy. Up to now there are fewer than 100 reports of cerebral aneurysms in children below the age of five years [2, 7, 8, 9, 19, 22, 25, 28, 29, 30, 31, 32, 35, 37, 38, 40, 41, 42, 44, 46, 51, 54, 55, 58]. Paloetti et al [40] summarized 44 cases of cerebral aneurysms in children of less than 3 years. When Ferrante reviewed the literature in 1988, he added 24 new cases of patients younger than 3 years and 21 patients younger than 5 years of age [9]. Since then ten new cases have been reported in this age group [8, 19, 22, 28, 30, 37, 38, 42, 46, 47]. The number of reported new cases is less than one case per year. 0.005 to 2 % of all diagnosed aneurysms are pediatric [8, 34, 39]. In an autopsy series by Chason and Hindman not one aneurysm was found in a series of 203 children under 10 years [5]. There is still no reliable information about the incidence of cerebral aneurysms in infancy and early childhood in the literature.

Reviewing the literature we disclosed 46 cases of cerebral aneurysms in infants younger than 1 year. Of these aneurysms, four were considered to be traumatic or associated with a recent trauma [1, 36, 42], two appeared to be mycotic [24, 30], one was associated with fibromuscular hyperplasia of the renal arteries [3], one with *moya moya* disease [cited in 9] and one with Rendu osler disease [47]. The remaining cases were thought to be congenital. Histology was not available for all these cases, but in 13 of the cases histological examination disclosed structural

changes of the media: e. g., lack or fragmentation of the internal elastic membrane (IEM) in the aneurysm and adjacent vessel wall [3, 4, 10, 15, 16, 23, 26, 28, 30, 33, 43]. In our recent case the media was cushioned and fragmentation and splitting of the internal elastic lamina was noticed in parts of both the middle cerebral arteries and in the aneurysms dome. These changes are likely to promote the generation of aneurysms since experimental data suggest that the IEM normally withstands intraluminal pressures up to 600 mmHg [14]. Thus defects of the IEM explain why the blood pressure can cause bulging of the vessel wall and promote the development of the aneurysm [50]. But the cause of IEM disruptions is not known yet [13]. Fibromuscular dysplasia [45] (Table I) was reported by our pathologist and in two other cases [3, 28]. This disease causes changes of the IEM that may cause or at least promote generation of cerebral aneurysms in infancy and early childhood. The etiology of FD itself is not known, yet all reported cases of aneurysms with pathological IEM might as well be due to FD.

Still questionable is the hereditary nature of infantile aneurysms. Only one sibling of the 45 patients with infantile aneurysm also suffered from an aneurysm [28]. Subarachnoid hemorrhage has been confirmed in a brother who died at the age of 7 days. In one other case an identical twin died early in life with symptoms consistent with SAH, but the brain was not included in autopsy [36]. In the remaining cases there is no hint of a hereditary nature of the aneurysm, although no screening of relatives is documented. The youngest child with a familial aneurysm was 4 years old [52]. To our knowledge no examination of the brother or other relatives of our patient has been performed yet. However, there have been reports of a familial accumulation [6, 12, 17, 28,

Table I: Histological forms of fibromuscular dysplasia (adapted from Remmele [45]), Type A and B1 correspond best with the findings in the vessel wall of cerebral aneurysms

Type	Relative frequency	Morphology, consequences
A	10 %	<i>Fibrodysplasia of the intima:</i> proliferation of fibroblasts and fibrosis of the intima – the elastica interna might also be changed
B1	2–3 %	<i>Fibromuscular dysplasia of the media:</i> proliferation of smooth muscle cells and fibrosis, disruption of the internal elastic layer is possible
B2	75–80 %	<i>Fibrodysplasia of the media:</i> presenting with the typical “strings of beads”-pattern and thinning of the media in the dilatations
C	10–15 %	<i>Fibrodysplasia of the subadventitia:</i> segmental annular fibrosis in the area of the external elastic membrane

52] of aneurysm. Since the trait is not obvious and there are no laboratory parameters for screening, all siblings should undergo either angiography, angio-CT, or angio-MRI. Reliable angiography results, however, carry risk due to the invasive character of this investigation. Less invasive tests like the angio-CT or angio-MRI are almost as reliable, but more expensive [49]. Unfortunately, a negative result does not rule out the development of an aneurysm in the future, and repetitive scans are required during lifetime. Thus, this technique is not suited for general screening in asymptomatic patients. But since the risk of surgical treatment of an unruptured aneurysm is so low, and morbidity of a ruptured aneurysm is so high, screening measures to detect asymptomatic aneurysms in families of a patient with an aneurysm appear justified. There are also no tests for screening aneurysms. A promising approach appears to be the screening for deficiency of alpha-1-antitrypsin, a protease inhibitor, in the serum of patients. Such a deficiency has been reported in coincidence with cerebral artery aneurysms [48]. Other authors are less convinced of this connection [57]. Further investigations have to follow.

When admitting an infant with stroke or stroke-like symptoms, neurosurgeons should consider a rupture of an aneurysm. Most of the prior cases included subarachnoid hemorrhage (SAH) and/or intracranial hemorrhage (68 %). At least twelve of these scored IV–V on the Hunt and Hess scale [21], but information on the clinical picture is limited in most cases (Table 2). We had to cope with an infant in bad condition (Hunt and Hess IV). The CT scan re-

quired a quick decision. Angiography was not available within a reasonable time. A "reasonable time" would be 20 to 30 min in a well-organized hospital. Angiography was performed immediately after admission in only two cases [3, 26] and surgical treatment was initiated in only one of these cases [26]. This indicates one problem of diagnostics: time. In most cases in, the literature surgery was delayed until after angiography with a generally good outcome. In our case, the plan to win time for sufficient diagnosis by placing an external ventricular drainage had to be given up when the pupils became fixed. We decided to perform an emergency decompression. This appears ex-post-facto to be a reasonable decision, since emergency craniotomy and trapping of an aneurysm generally shows a good outcome [26].

Neurosurgeons should strive for an early diagnosis and efficient emergency treatment if subarachnoid hemorrhage has occurred. Unfortunately, many physicians are not aware of the fact that cerebral aneurysms can be present and bleed in the very young patient. Management of children and infants with strokes or stroke-like events might be a problem. To our knowledge no standard has been defined for the emergency management of young patients with cerebral aneurysms. In our case of the 10 month old boy, treatment was delayed because the patient was not directly transported to a neurosurgical department. Since acute hemorrhage of aneurysms or arterio-venous malformations (AVM) and ischemic strokes can present with the same symptoms [27], it is difficult to decide where to send the patient. A final diagnosis can not be made at the emergency site. Because bleeding aneurysms and AVM's

Table II: Conservative and operative management of infantile cerebral aneurysms.

	Hunt and Hess Grade 0		Hunt and Hess Grade 1–3		Hunt and Hess Grade 4–5	
	died	survived	died	survived	died	survived
Surgery (Clipping, etc.**)	0	3 (29, 51, 56)	0	5 (1, 4, 16, 30, 35)	0	4 (7, 25, 26*, 55)
no Surgery	2 (23, 32)	4 (41, 44, 53, 54)	1 (33)	1 (31)	7 (2, 3, 10, 15, 28, 1, 43)	0

Source: 45 patients reviewed in the literature, taking only those where sufficient clinical data was available. Hunt and Hess – Score according to [21]

* emergency surgery

** Trapping, clipping, wrapping, not only ventricular drainage etc.

have to be treated with neurosurgery, while stroke can be treated conservatively. Transport of children presenting with stroke to a hospital with a neurosurgical service seems reasonable. Transport to the next hospital with a CT-scan is an alternative only if the first clinical examination reveals no acute danger to life. If an AVM or an aneurysm is the cause of symptoms, angiography or angio-CT might be necessary to distinguish different types of bleeding and might also be helpful for planning the surgery even in emergency situations. Thus, these should be available without delay in a hospital with neurosurgical units. Other differential diagnoses should be ruled out only if there is no indication for emergency surgery.

The outcome of aneurysms surgery for children, as for adults, is best if elective surgery can be performed [18, 20, 58]; operative risk is high in deteriorated patients according to the Hunt-and-Hess-Scale [20]. Generally, the outcome of children is thought to be better than that of adults [22]. This again supports the call for transport to a hospital with a neurosurgical department. To establish and promote this emergency routine, we have to sensitize and convince neurosurgeons, paramedics, emergency doctors, general practitioners, and pediatricians that subarachnoid hemorrhage due to aneurysms is a very important differential diagnosis and needs all our attention.

References

- [1] ANMACHER AL, CG DRAKE: Cerebral artery aneurysms in infancy, childhood and adolescence. *Child's brain* 1 (1975) 72–80
- [2] BILKOW A, M ZAJICEK: Mozkowa krvanci z cejnich aneurismat u deti. *Cesk Pediatr* 26 (1971) 332–333
- [3] BORLANDER H, O HASSLER, B LILIEQUIST, KA WEST: Cerebral aneurysm in an infant with fibromuscular hyperplasia of the renal arteries. *J Neurosurg* 49 (1978) 756–759
- [4] CEDZICH C, J SCHRAMM, G RÖCKLEIN: Multiple middle cerebral artery aneurysms in an infant. Case report. *J Neurosurg* 72 (1990) 806–809
- [5] CHASON JL, WM HINDMAN: Berry Aneurysms of the Circle of Willis. *Neurology* 8 (1958) 41–44
- [6] DIERSSEN G, F MONTIAGA, A VAZQUEZ, B PATERNIA: Three cases of ruptured intracranial aneurysm in a family. *Neurochirurgia (Stuttg)* 33 (1990) 85–87
- [7] DOBRONY I, J VAJDA: Im Säuglingsalter operiertes sakkuläres Aneurysm der A cerebri media. *Acta Pediatr Acad Sci Hung* 17 (1976) 311–315
- [8] ERICSON K, M SODERMAN, B KARLSSON, WY GUO, C LINDQUIST: Multiple intracranial arteriovenous malformations: a case report. *Neuroradiol* 36 (1994) 157–159
- [9] FERRANTE L, A FORTUNA, P CELLI, A SANTORO, B FRAIOLI: Intracranial arterial aneurysms in early childhood. *Surg Neurol* 29 (1988) 39–56
- [10] FERRY PC, C KERBER, D PETERSON, AG GALO: Arteriectasis, subarachnoid hemorrhage in a three-month-old infant. *Neurology* 24 (1974) 494–500
- [11] FISHER CM, JP KISTLER, JM DAVIS: Relation of cerebral vasospasm to subarachnoid hemorrhage visualized by computerized topographic scanning. *Neurosurgery* 6 (1980) 1–9
- [12] FOX JL, JP KO: Familial intracranial aneurysms. *J Neurosurg* 52 (1980) 501–503
- [13] GAO YZ, HA VAN ALPHEN: Pathogenesis and histopathology of saccular aneurysms: review of the literature. *Neurol Res* 12 (1990) 249–255
- [14] GLYNN LE: Medial defects in the circle of Willis and their relation to aneurysm formation. *J Pathol Bacteriol* 51 (1940) 213–221
- [15] GRACIA-CHAVEZ C, J MOSSY: Cerebral artery aneurysm in infancy: Association with agnesis of the corpus callosum. *J Neuropathol Exp Neurol* 24 (1965) 492–501
- [16] GRODE ML, M SAUNDERS, CA CARTON: Subarachnoid hemorrhage secondary to ruptured aneurysms in infants. Report of two cases. *J Neurosurg* 49 (1978) 898–902
- [17] HASHIMOTO I: Familial intracranial aneurysms and cerebral vascular anomalies. *J Neurosurg* 46 (1977) 419–427
- [18] HEISKANEN O: Ruptured intracranial arterial aneurysms of children and adolescents. Surgical and total management results. *Childs Nerv Syst* 5 (1989) 66–70
- [19] HERMAN JM, HL REKATE, RF SPETZLER: Pediatric intracranial aneurysms: simple and complex cases. *Pediatr Neurosurg* 17 (1991) 66–72
- [20] HUMPHREYS RP: Intracranial arterial aneurysms. In: EDWARDS MSB, HJ HOFFMAN (eds): *Cerebral vascular disease in children and adolescents*. Williams and Wilkins, Baltimore 1989, pp. 247–253
- [21] HUNT WE, RM HESS: Surgical risk as related to time of intervention in the repair of intracranial aneurysms. *J Neurosurg* 28 (1969) 14–20
- [22] ITO M, M YOSHIHARA, M ISHII, A WACHI, K SATO: Cerebral aneurysms in children. *Brain Dev* 14 (1992) 263–268
- [23] JAE JA: A large aneurysm of the posterior inferior cerebral artery in a 1-year old child. *J Neurosurg* 18 (1961) 245–247
- [24] JÄNSCH W: Rupturiertes Hirnbasisaneurysma im Säuglingsalter. *Zentralbl. Allg. Pathol.* 105 (1964) 439–442
- [25] JONES RK, EW SHEARBURN: Intracranial aneurysm in a four-week-old infant. Diagnosis by angiography and successful operation. *J. Neurosurg* 18 (1961) 122–124

- [26] KITANO I, M FUKUI, K KINOSHITA: Infantile cerebral aneurysm. *Surg Neurol* 16 (1981) 386–390
- [27] KOTLAREK F, A THRON, U WEBER, R SCHNEIDER: Der Schlaganfall beim Kind: Ätiologie, Differentialdiagnose, sinnvolle Diagnostik und therapeutische Möglichkeiten. *Klin Padiatr* 205 (1993) 332–339
- [28] KUCHELMEISTER K, R SCHULZ, M BERGMANN, R SCHWUCHOW, E VOLLMER: A probably familial saccular aneurysm of the anterior communicating artery in a neonate. *Childs Nerv Syst* 9 (1993) 302–305
- [29] LAPRAS CI, A GOUTELLE, JP DECHAUME, MM BRUNAT: Les anévrismes intracrâniens chez l'enfant. A propos de 4 observations. *Société de Neurochirurgie de Langue Française*, Décembre 1976
- [30] LEE KS, SS LIU, RF SPETZLER, HL REKATE: Intracranial mycotic aneurysm in an infant: Report of a case. *Neurosurgery* 26 (1990) 129–133
- [31] LEE YJ, SR KANDALL, VS GAHLI: Intracerebral arterial aneurysm in a newborn. *Arch Neurol* 35 (1978) 171–172
- [32] LEMMEN LJ, RC SCHNEIDER: Aneurysm in the third ventricle. *Neurology (Minneapolis)* 3 (1953) 474–476 (1953)
- [33] LIPPER S, D MORGAN, MR KRIGMAN, EV STAAB: Congenital saccular Aneurysm in a 19-day-old neonate: Case report and review of the literature. *Surg Neurol* 10 (1978) 161–165
- [34] MCCORMICK WF, JD NOFZINGER: Saccular intracranial aneurysms. *J Neurosurg* 22 (1965) 155–159
- [35] MORELLI RJ, F LAUBSHER: Intracranial aneurysm in infancy. Case report. *J Neurosurg* 46 (1977) 832–834
- [36] NEWCOMB AL, GF MUNNS: Rupture of aneurysm of the circle of Willis in the newborn. *Pediatrics* 3 (1949) 769–772
- [37] NISHIO A, M SAKAGUCHI, K MURATA, M EGASHIRA, T YAMADA, M IZUO, N NAKANISHI: Anterior communication artery aneurysm in early childhood. Report of a case. *Surg Neurol* 35 (1991) 224–229
- [38] OSENBACH RK: Giant aneurysm of the distal posterior inferior cerebellar artery in an 11-month-old child presenting with obstructive hydrocephalus. *Pediatr Neurosurg* 15 (1989) 309–312
- [39] OSTERGAARD JR, B VOLDBY: Intracranial arterial aneurysms in children and adolescents. *J Neurosurg* 58 (1983) 832–837
- [40] PAOLETTI P, S PEZZOTTA, M SCOTTA, L MOSCA: Saccular aneurysm of infancy and early childhood. Report of a case. *Acta Neurochir (Wien)* 57 (1981) 257–267
- [41] PIA HW, H FONTANA: Aneurysms of the posterior cerebral artery. *Acta Neurochir (Wien)* 38 (1977) 13–35
- [42] PIATT JH, DA CLUNIE: Intracranial arterial aneurysm due to birth trauma. Case report. *J Neurosurg* 77 (1992) 799–803
- [43] PICKERING GR, GR HOGAN, EF GILBERT: Aneurysm of the posterior inferior cerebellar artery. Rupture in a newborn. *Am J Dis Child* 119 (1970) 155–158
- [44] POOLS JL, DG POTTS: Aneurysms and arteriovenous anomalies of the brain: diagnosis and treatment. Harper and Row, New York 1965
- [45] REMMELE W: Pathologie – Ein Lehr- und Nachschla- gebuch, Springer, Berlin, Heidelberg, New York, Tokyo 1993, p. 188
- [46] ROJANI AM, KJ POSKITT, DD COCHRANE, AJ MACNAB, MG NORMAN: Ruptured intracranial aneurysm presenting as cerebral infarction in a young child. *Pediatr Neurosurg* 16 (1990) 326–330
- [47] ROY C, G NOSEDA, A ARZIMANOGLU, JP HARPEY, MH BINET, C VAUR, B CAILLE: Maladie de Rendu-Osler révélée par la rupture d'un anévrisme artériel cérébral chez un nourrisson. *Arch Fr Pédiatr* 47 (1990) 741–742
- [48] SCHIEVINK W, U PRAKASH, D PIEGRAS, B MOKRI: α_1 -Antitrypsin deficiency in aneurysms and cervical artery dissection. *Lancet* 343 (1994) 452–453
- [49] SCHMID UD, HJ STEIGER, P HUBER: Accuracy of high resolution computed tomography in direct diagnosis of cerebral aneurysms. *Neuroradiology* 29 (1987) 152–159
- [50] SEKHAR LN, RC HEROS: Origin, growth, and rupture of saccular aneurysms: A Review. *Neurosurgery* 8 (1981) 248–260
- [51] SHUCART WA, SA WOLPERT: An aneurysm in infancy presenting with diabetes insipidus. *J Neurosurg* 37 (1972) 368–370
- [52] TER BERG HW, JB BIJLSMA, J WILLEMSE: Familial occurrence of intracranial aneurysms in childhood: A case report and a review of literature. *Neuropediatrics* 18 (1987) 227–230
- [53] THOMPSON JR, DC HARWOOD-NASH, CR FITZ: Cerebral aneurysms in children. *AJR* 2 (1973) 163–175
- [54] THOMPSON RA, HFW PRIBRAM: Infantile cerebral aneurysms associated with ophthalmoplegia and quadriplegia. *Neurology (Minneapolis)* 19 (1969) 785–789
- [55] VAPALATHI PM, KP SCHUG, L TARKKANEN, G BJORKESTEN: Intracranial arteriell aneurysm in a three-month-old infant. Case report. *J Neurosurg* 30 (1969) 169–171
- [56] VENTURYRA ECG, SH CHO, BC BENOIT: Super giant globoid intracranial aneurysm in an infant. Case report. *J Neurosurg* 53 (1980) 411–416
- [57] WÖLFER J, D MOSKOPF, B WOESLER, H WASSMANN: α_1 -Proteaseinhibitor im Serum von Patienten mit spontanen Subarachnoidalblutungen. In: BÖKER DK (ed): *Cerebraler Vasospasmus – Neue Aspekte zur Pathogenese und Therapie*. Biermann, Zülpich 1996, pp 69–73
- [58] YOSHIMOTO T, K UCHIDA, J SUZUKI: Intracranial saccular aneurysms in the first three decades. *Surg Neurol* 9 (1978) 287–291

Submitted January 14, 1997.

Accepted February 28, 1997.

Dr. med. Swen Hülsmann
Zentrum Physiologie und Pathophysiologie
Abt. Neuro- und Sinnesphysiologie
Georg-August-Universität
Humboldtallee 23
D-37077 Göttingen
Germany