

PURE TOPOGRAPHICAL DISORIENTATION RELATED TO DYSFUNCTION OF THE VIEWPOINT DEPENDENT VISUAL SYSTEM

K. Suzuki, A. Yamadori, Y. Hayakawa and T. Fujii

(Section of Neuropsychology, Division of Disability Science, Tohoku University Graduate School of Medicine)

ABSTRACT

A 70-year-old woman presented with pure topographical disorientation following haemorrhage in the right medial parietal lobe. She could not navigate in the real world despite good ability to draw maps, describe routes, and identify objects and buildings. Her performance on mental rotation, visual memory, and spatial learning tests also was normal. In contrast, she failed totally in a locomotor map test and in a task in which she was requested to judge viewpoints of buildings. Her highly selective topographical disorientation was probably caused by the inability to identify a viewpoint of a particular building. The lesion may have disconnected the association between the spatial information processed in the lateral parietal lobe and the visual memory mediated by the limbic system, which seems to be important for viewpoint dependent analysis.

Key words: topographical disorientation, dorsal visual system, visual recognition

INTRODUCTION

Topographical disorientation is the inability to navigate through familiar or novel environments. The basic mechanism of topographical disorientation does not seem to be homogeneous and different types of the disorder have been proposed. Paterson and Zangwill (1945) described a patient with great difficulty in recognizing buildings and features in his home town, which they labeled specific topographical agnosia. This patient also had difficulties in describing routes and in drawing maps and plans, considered to be due to the inability to formulate correct topographical relationships, "an additional disorder in the field of spatial memory". Topographical disorientation is commonly described as either topographical agnosia or amnesia, but the distinction remains somewhat unclear (Suzuki, Yamadori, Takase et al., 1996).

Topographical disorientation may also be classified based on the locus of lesion (Levine, Warach and Farah, 1985). Disorders of "visual-object" representations due to damage to the ventral visual system should be distinguished from disorders of "visual-spatial" representations due to damage to the dorsal visual system. Although some authors (Milner and Goodale, 1995; Farrell, 1996) consider the ventral visual system especially important for

topographical orientation, in several case reports the disorder has been associated with damage to the right parietal lobe. We recently studied a patient with pure topographical disorientation associated with a lesion in the right medial parietal lobe. Our investigation revealed specific features, conceivably related to damage of the dorsal visual system.

CASE REPORT

TY, a 70-year-old, right-handed, retired female teacher with a 12th-grade education, was admitted to the Rehabilitation Department of Tohoku University Hospital, Japan, for evaluation and therapy of topographical disorientation. Her previous medical history included mild hypertension and hyperlipemia. She had been very active and sometimes toured Tokyo alone with the help of a map.

Forty days before admission, she woke up at midnight with severe headache and nausea. She intended to go to the toilet to vomit, but could not find her way and had to open every door along the corridor. Next morning, she felt fine except for mild headache. She left home to go to an out-patient clinic within a ten-minute walk, where she had been treated for ten years. She lost her way and walked around for more than three hours. She finally sought help at an office located far away from her house. She could recognize friends along the way and the location of the office, which she described to her husband by telephone. During the next week, she complained of headache, blurred vision, and mild numbness in her left arm and shoulder. Eight days later, she was admitted to a hospital where brain computed tomography revealed subcortical haemorrhage, which was treated conservatively. On admission to the hospital, she was alert and oriented in time and place. However, she could not learn the location of the lavatory and sometimes collided with a door or a person. During the following week, the numbness of the left arm improved and she was referred to our service. Detailed neuropsychological assessment was performed during the next two months. She remained clinically stable throughout her hospitalization.

Neurological examination showed that she was alert and oriented. She had incomplete left lower quadrantanopsia, but her visual acuity was preserved with full ocular movements. A slight weakness of her left arm and leg was observed. The functions of the other cranial nerves and cerebellum were intact. Deep tendon reflexes were symmetrical without pathological reflexes.

Brain magnetic resonance imaging performed one and half month after the onset revealed a subcortical haemorrhage in the right parietal lobe, located mainly in the precuneus and impinging on the cuneus (Figure 1). Lacunae were also noted in the deep white matter of both hemispheres. Measurement of blood flow with ^{123}I -IMP single photon emission computed tomography showed hypoperfusion in the right parietal lobe. Cerebral angiography showed no abnormality.

Neuropsychological Assessment

She was alert and oriented in time and place. Her digit span forward was 5 and her modified Corsi Block tapping span was 4, which was within the normal range of age-matched controls (4.7 ± 0.8). Her WAIS-R verbal IQ was 103, but her performance IQ was 86. She scored 28 out of 36 on Raven's Coloured Progressive Matrices. The Wechsler Memory Scale-Revised tests showed that both verbal and visual memory were well preserved: General memory index 113, Verbal memory index 104, Visual memory index 125, and Delayed recall index 118. She showed no evidence of aphasia, acalculia, right-left disorientation, visual agnosia, ideomotor apraxia, ideational apraxia, or motor impersistence.

Ten days after the onset, she demonstrated topographical disorientation, metamorphopsia, visual disorientation, visuomotor ataxia in the left visual field, left unilateral spatial neglect, left visual extinction, and constructional apraxia. Most of these symptoms improved rapidly, but topographical disorientation and visuomotor ataxia persisted for the next two months.

She gave informed consent to participate in a series of experimental investigations to

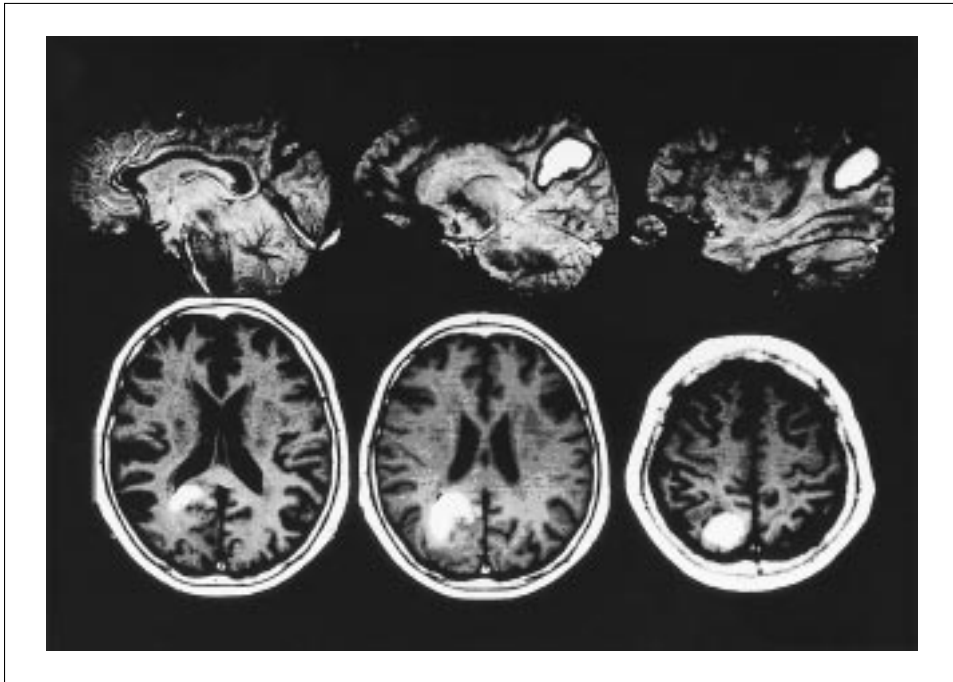


Fig. 1 – Brain magnetic resonance image taken one and half months after the onset revealing old subcortical haemorrhage in the right parietal lobe, located close to the precuneus.

determine the qualitative features of her topographical disorientation, and to elucidate its mechanisms in relation to the damage to the dorsal visual system.

EXPERIMENTAL INVESTIGATIONS

Higher Visual Function (Table I)

She was given the development visual perception test – second edition (Hammil, Pearson and Voress, 1993) which consists of 8 subtests: eye-hand coordination, position in space, copying, figure-ground, spatial relations, visual closure, visual-motor speed and form constancy. Her performance was assessed with reference to the percentiles of 10 year-old children. She scored at the 50-95 percentile in all subtests, except the visual closure test. The stereo test showed that stereoscopic vision was within the normal range (stereoscopic angle 100s). Ishihara's test for colour blindness brought out no defect. There was no prosopagnosia, achromatopsia, or object visual agnosia. She never reported that familiar faces looked strange or unfamiliar.

Viewpoint Identification

Her ability to identify the viewpoint from which a stimulus was seen was assessed with the presentation of photographs of 9 objects, 4 sets of objects and

TABLE I
Visual Perception and Recognition

Test	
Judgment of Line Orientation (Benton)	20/30
Overlapping figures (Christensen)	9/9
Facial Recognition (Matching of identical face)	30/30
Naming familiar persons	22/22
Naming famous people	18/22
Naming famous buildings and scenery	13/15
Naming colours	10/10
Naming object drawings	10/10
Naming object photographs	9/9
DTVP-2*	
Eye-Hand Coordination	63%ile
Position in Space	75%ile
Copying	95%ile
Figure-Ground	50%ile
Spatial Relations	75%ile
Visual Closure	37%ile
Visual-Motor Speed	50%ile
Form Constancy	84%ile

* DTVP-2 = Developmental test of visual perception, second edition.
 The performance was assessed with reference to the percentiles of 10 year-old children.

her own house. Each object was photographed from a different view (9 items), each set of objects was photographed from 4 different views (however, only 14 photographs were used) and her own house was photographed from 3 different views, each presented three times (9 items). She was requested to indicate with her forefinger the standpoint from which the photo was taken on a plan of the stimulus taken from above (Figure 2).

She could identify viewpoints of single object (9/9) and sets of objects (13/14) quite well. However, she showed marked difficulty in identifying the viewpoints of her own house (0/9), although she could recognize that the building was her house. She correctly recognized each part of the house and its surroundings, e.g., a garden table, but had no idea from which viewpoint the garden table was seen, even when she noticed other cues such as trees in the garden. In contrast, if asked to imagine what she would see around her house from a particular direction, she gave correct verbal responses.

Topographical Memory for Environmental Features

She could name 87% of famous buildings or sceneries correctly. However, when given a photograph of her house and its surroundings, she only recognized the former. Although the surrounding houses or buildings had no specific features, their identification should have been facilitated by the knowledge of their spatial relationships with her own house. In contrast, her verbal description of a park and large buildings around her house was fairly accurate.

Topographical Memory for Spatial Relationships

She could draw an almost complete plan of her house and the buildings

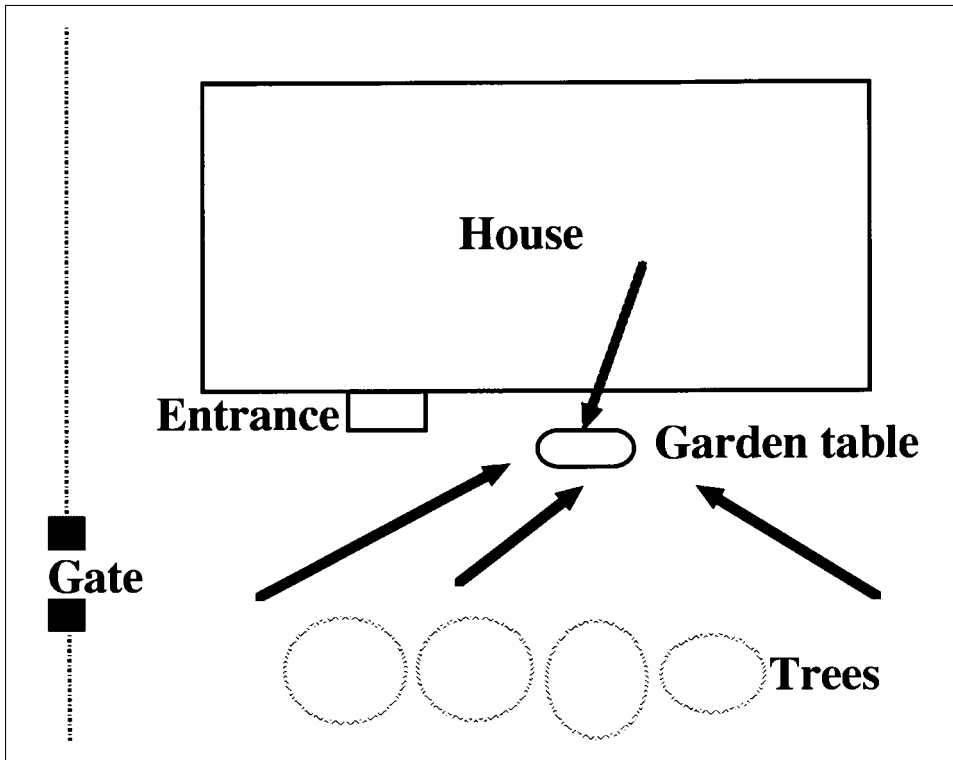


Fig. 2 – Example of the responses given by the patient to identify the viewpoint of a photograph of her own house. The top arrow indicates the correct viewpoint of the photograph. The bottom three arrows are TY's indications of the viewpoints. Although she noticed a garden table on the photo, she had no idea from which direction it was seen.

surrounding it and describe verbally the route from her house to the clinic where she had been treated for 10 years. She even recalled where she lost her way at the acute stage. She could correctly place 8 out of 10 cities on a map of Japan. Mistakes were only made in the western part of Japan where she had never been. Therefore, her retrograde memory for spatial relationships was judged to be normal.

To study anterograde memory for spatial relationships, she was asked to draw a simple map of the hospital including five places that she had occasionally visited: a lobby, flower shop, post office, mini-mart, and nursing station. Although she first located only two places, after walking through these places again, she could draw the map and place the five points correctly.

Spatial Learning

In a spatial learning supraspan test (span + 2 = 6 blocks), she learned 3 different sequences in 3 trials, which was well within the normal range. In the Porteus Maze, she passed mazes up to year 11 in 1 trial, the year 12 maze in 2 trials, the year 14 maze in 1 trial, and the adult maze in 3 trials.

Mental Rotation and Mental Imagery

To assess mental rotation ability, she was required to draw a small circle in the corner of a parallelogram, in which it was located corresponding to the corner of a model parallelogram, rotated from 0 to 180 degrees (Christensen, 1979). She scored 6 out of 10 in this task, which is fair for her age. On the form constancy subtest of the developmental test of visual perception, which involves mental rotation of figures, she scored at the 84 percentile of 10 year-old children. To examine her ability to imagine unseen objects, three-dimensional drawings of stacked blocks were presented for her to count the total number of blocks (Christensen, 1979). She performed all 4 items correctly. Therefore, mental imagery and rotation abilities, which are necessary for map reading, were fairly well preserved.

Locomotor Map Test

Her ability to find her way through the environment was examined. She had to find her way with the aid of a map from the main entrance (point 1 in Figure 3A) of the hospital to another building (point 2 in Figure 3A) in the campus, which were approximately 330 m apart. As there were no names of the buildings in the map, it was hard to verbalize the route with sequences of turns and landmarks. Before starting, she was asked to trace the shortest path on the map, which she could do perfectly (Figure 3A). She also verbalized which way she would go, saying she would turn to her right first. However, she first turned to her left and wandered about for some time (Figure 3B). An examiner gave her a verbal cue when she got totally lost. She could turn the map round, so that the map was in alignment with the path. In addition, she always mislocated her present position on the map (Figure 3C). She took about 20 minutes to arrive at the target building.

Road-map Test of Directional Sense

We used a road-map test similar to the Money Road-Map Test of Directional Sense (Alexander and Money, 1966). TY was presented with a section of the Porteus Maze, on which a route was marked. Her task was to say, without turning the maze around or changing her orientation with respect to the maze, whether each successive turn was to the right or to the left. She described all the 37 turns correctly without hesitation.

Test of Abstract Orientation

A test of abstract orientation similar to that of Ettlinger, Warrington and Zangwill (1957) was given. TY was asked to imagine that she was facing in one compass direction and then asked to say in which direction she would be facing if she performed a given movement. Her performance was good with 13 correct responses out of 16. She performed perfectly (10/10) the task of telling in what direction was a city with respect to another. She could judge the direction of body parts correctly (19/20), e.g., "If your nose is facing south, in which direction will your right shoulder be?"

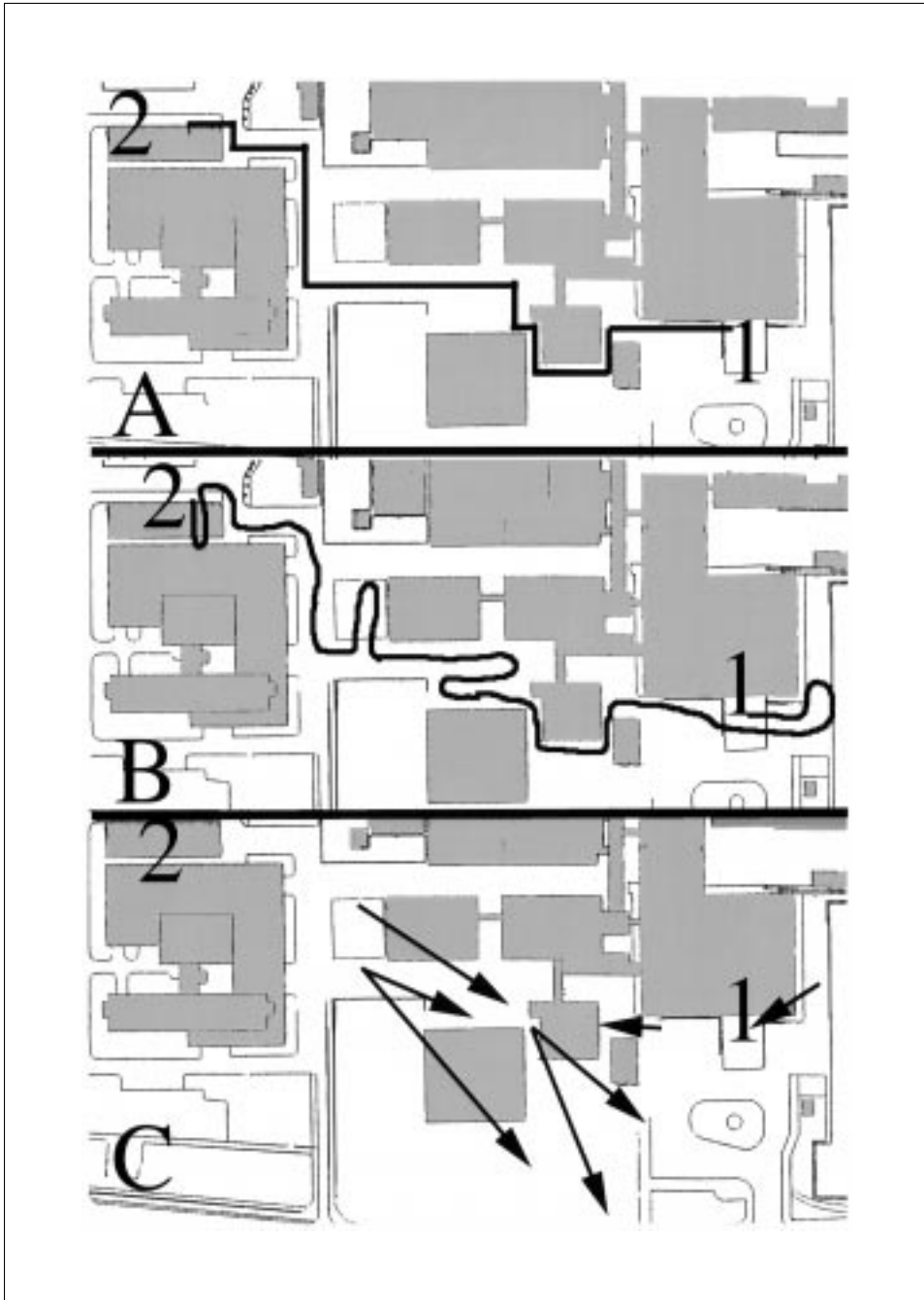


Fig. 3 – Locomotor map test. The patient had to find her way with a map from the main entrance (1) of the hospital to another building (2) in the campus, located approximately 330 m apart. A: The black line indicates the path she correctly traced on the map. B: The black line indicates the path she followed. C: Arrows show mistakes made when she had to point to her location on the map. The origin of each arrow indicates her actual location and the arrowhead the place she indicated on the map.

DISCUSSION

TY showed pure spatial disorientation without other major cognitive deficits. The syndrome was characterized by the isolated difficulty to navigate through the real world. Other related deficits, such as difficulty in map drawing and recognizing familiar landscape or buildings, were absent. The disorder likely underlying this highly selective topographical disorientation was the inability to judge or identify the viewpoint of a particular building. TY could not tell from which angle a picture was taken, although she could identify it. Loss of the ability to identify the viewpoint of a particular landmark or building makes it extremely difficult to identify their exact orientation, even if the building and the position of the building in a map can be recognized.

Topographical disorientation has classically been divided into two major forms: topographical amnesia and topographical agnosia (Paterson and Zangwill, 1945). Topographical agnosia is a type of visual agnosia specific for landmarks. Topographical amnesia can be divided into two subtypes: amnesia for landmarks and amnesia for spatial relationships. The present case cannot be classified into either of these types.

Topographical disorientation associated with deficit of actual navigation but with relatively preserved cognitive map and an ability to recognize landmarks has been reported in a few patients. Vighetto, Aimard, Confavreux et al. (1980) reported a patient who initially demonstrated topographical disorientation with confabulation about his location and an inability to describe familiar routes. The symptoms improved over the following 5 months, when he showed deficit only on a locomotor map test with non-verbalizable landmarks. Computed tomography and autopsy revealed cerebral infarction in the right parietal lobe. Hublet and Demeurisse (1992) described a patient with topographical disorientation and infarction in the right internal capsule. He performed poorly a locomotor map test with non-verbalizable landmarks, a stylus maze learning test and visual memory tests. In contrast, he was perfectly able to evoke familiar paths and to recognize photographs of familiar districts. Cerebral hypoperfusion was observed over the right parietal lobe.

The above cases and the present one clearly indicate that the abilities to recognize landmarks, to draw a map, to describe a route and to follow a route in a real setting can be dissociated. In the present case, route finding difficulty was related to the inability to identify the viewpoint of large objects, like her house, whereas no difficulty emerged both in judging viewpoints of smaller objects or sets of objects.

In a discussion about mental imagery, Levine et al. (1985) proposed to classify topographical disorientation into a form caused by the impairment of "visual-object" representations and a form caused by the impairment of "visual-spatial" representations. "Visual-object" representations would be subserved by the "what" visual system passing through the temporal regions, i.e., the ventral system, while "visual-spatial" representations would be subserved by the "where" visual system passing through the parietal region, i.e., the dorsal system (Ungerleider and Mishkin, 1982). However, Farrell (1996) in an extensive review of this subject took exception with the attribution of "what" and "where"

components to two discrete anatomical systems, arguing that both components may be processed by the same ventral visual pathway. Using a similar line of argument, Milner and Goodale (1995) submitted that both cortical visual systems processed objects as well as location, but with different purposes: the ventral system would encode spatial information “allocentrically” (i.e., viewpoint-independently) for achieving perception and identification, and the dorsal system would encode spatial information “egocentrically” (i.e., viewpoint-dependently) for the guidance of actions. They suggested that most cases of topographical disorientation are due to damage of the ventral system causing the allocentric type of visuospatial dysfunction.

However, the several cases of topographical disorientation associated with right parietal lesion suggest that the dorsal visual system is also related to topographical disorientation (Paterson and Zangwill, 1945; Whitty and Newcombe, 1973; Kase, Troncoso, Court et al., 1977; Cogan, 1979; Fine, Mellstrom, Mani et al., 1980; Vighetto et al., 1980; Aimard, Vighetto, Confavreux et al., 1981; Levine et al., 1985; Hublet and Demeurisse, 1992; Clarke, Assal and de Tribolet, 1993; Takahashi, 1993; Shimomura, Shirata and Yamada, 1995; Takahashi, Kawamura, Shiota et al., 1997). Table II summarizes 10 cases, in which the lesion, confirmed radiologically (CT/MRI) or at autopsy, involved either the right medial parietal lobe or the retrosplenial region, i.e. the posterior cingulate gyrus (Kase et al., 1977; Levine et al., 1985; Hublet and Demeurisse, 1992; Clarke et al., 1993; Takahashi, 1993; Shimomura et al., 1995; Takahashi et al., 1997). A case with a glioblastoma in the splenium was included in Table II, because of the expected dysfunction of the retrosplenial region due to the peripheral edema (Bottini, Cappa, Geminiani et al., 1990). All these 11 cases were unable to find routes in a real setting or to draw/describe routes, in the absence of agnosia for landmarks. TY and the patient reported by Hublet et al. (1992) showed the special features that the ability to draw maps was preserved and that topographical disorientation only emerged in a real setting and on a locomotor map test. The ability to identify viewpoints was not examined by Hublet et al. (1992).

The importance of the parietal lobe for spatial ability is firmly established. Pandya and Yeterian (1984) drew attention to the role played by the lateral parietal lobe (area 7) – cingulate gyrus circuitry in the formation of spatial memory. They argued that information on the significance of stimuli, which is based on the memory traces provided by the cingulate gyrus, is necessary for area 7 to attend to the spatial world appropriately. The neurophysiological role of the medial parietal lobe is unclear, but it is strategically situated in the retrosplenial region between the lateral parietal lobe and the posterior cingulate gyrus. Viewpoint identification is very likely to be dependent on the close association between the spatial information processed in the lateral parietal lobe and the memory mediated by the cingulate gyrus, especially on the right side. This association is likely to be critical for viewpoint identification of large objects such as a house, because their mental representation calls for a bird’s-eye view, while a small object can be seen from any viewpoint in everyday life. In the present patient, this viewpoint dependent, ego-centric component of navigational ability was probably impaired by the right medial parieto-cingulate

TABLE II
*Topographical Disorientation Associated with the Lesion in the Medial Parietal
 and/or Retrosplenial Region*

Case	Lesion localization	Recognition of landmarks	Drawing maps	Verbal description of routes	Navigation in real setting	Locomotor map test	Road-map test of directional sense	Non-verbal memory	Construction
Kase et al. (1977) C1	Blt. P (med and lat)				-				+
Levine et al. (1985) C2	Blt. PO	+	-	-	-				-
Hublet et al. (1992)	R internal capsule*	+	+	-	-	-			+
Takahashi (1993) C9	R med P, retrosplenial	+	-	-	-				-
Clarke et al. (1993)	R med P, splenium	+	-	-	-				-
Shimomura et al. (1995)	R med PO, retrosplenial	+	-	-	-				-
Takahashi et al. (1997) C1	R med P, retrosplenial+					-			-
C2	R med P, retrosplenial	+	-	-	-				-
C3	R med P, retrosplenial	+	-	-	-				+
Suzuki et al. (this study)	R med P, retrosplenial	+	+	+	-	-	+	+	+
Bottini et al. (1990)	splenium (glioblastoma)	+	-	-	-	-	+	+	-

C = case, R = right, Blt = bilateral, O = occipital, P = parietal, med = medial, lat = lateral, - = impaired, + = preserved, * low perfusion in the right parietal lobe.

lesion. Although impairment of other visuo-motor processes might also have contributed to her deficits, we believe that her inability to achieve viewpoint-dependent coding was the key factor in causing her topographical disorientation.

Acknowledgments. We are grateful to Dr. Hiroshi Shimizu for referring the patient to us.

REFERENCES

- AIMARD, G., VIGHETTO, A., CONFAVREUX, C., and DEVIC, M. La désorientation spatiale. *Revue Neurologique (Paris)*, 137: 97-111, 1981.
- ALEXANDER, E., and MONEY, J. Turner's syndrome and Gerstmann's syndrome: Neuropsychologic comparisons. *Neuropsychologia*, 4: 265-273, 1966.
- BOTTINI, G., CAPPÀ, S., GEMINIANI, G., and STERZI, R. Topographic disorientation – A case report. *Neuropsychologia*, 28: 309-312, 1990.
- CHRISTENSEN, A-L. *Luria's Neuropsychological Investigation Manual*. Copenhagen: Munksgaard, 1979.
- CLARKE, S., ASSAL, G., and DE TRIBOLET, N. Left hemisphere strategies in visual recognition, topographical orientation and time planning. *Neuropsychologia*, 31: 99-113, 1993.
- COGAN, D. Visuo-spatial dysgnosia. *American Journal of Ophthalmology*, 88: 361-368, 1979.
- ETTLINGER, G., WARRINGTON, E., and ZANGWILL, O.L. A further study of visual-spatial agnosia. *Brain*, 80: 335-361, 1957.
- FARRELL, M.J. Topographical disorientation. *Neurocase*, 2: 509-520, 1996.
- FINE, E., MELLSTROM, M., MANI, S., and TIMMINS, J. Spatial disorientation and the Dyke-Davidoff-Masson syndrome. *Cortex*, 16: 493-499, 1980.
- HAMMILL, D.D., PEARSON, N.A., and VOESS, J.K. *Developmental Test of Visual Perception, Second Edition. Examiner's Manual*. Austin: PRO-ED, 1993.
- HUBLET, C., and DEMEURISSE, G. Pure topographical disorientation due to a deep-seated lesion with cortical remote effects. *Cortex*, 28: 123-128, 1992.
- KASE, C.S., TRONCOSO, J.F., COURT, J.E., TAPIA, J.F., and MOHR, J.P. Global spatial disorientation. Clinico-pathologic correlations. *Journal of the Neurological Sciences*, 34: 267-278, 1977.
- LEVINE, D., WARACH, J., and FARAH, M. Two visual systems in mental imagery: Dissociation of "what" and "where" in imagery disorders due to bilateral posterior cerebral lesions. *Neurology*, 35: 1010-1018, 1985.
- MILNER, A.D., and GOODALE, M.A. *The Visual Brain in Action*. Oxford: Oxford University Press, 1995.
- PANDYA, D.N., and YETERIAN, E.H. Proposed neural circuitry for spatial memory in the primate brain. *Neuropsychologia*, 22: 109-122, 1984.
- PATERSON, A., and ZANGWILL, O. A case of topographical disorientation associated with a unilateral cerebral lesion. *Brain*, 68: 188-211, 1945.
- SHIMOMURA, T., SHIRATA, A., and YAMANE, K. Two cases of route finding defect due to subcortical hemorrhage. *Japanese Journal of Stroke*, 17: 75-79, 1995.
- SUZUKI, K., YAMADORI, A., TAKASE, S., NAGAMINE, Y., and ITOYAMA, Y. Transient prosopagnosia and lasting topographical disorientation after the total removal of a right occipital arteriovenous malformation. *Clinical Neurology (Tokyo)*, 36: 1114-1117, 1996.
- TAKAHASHI, N. Pathophysiology of visual agnosia. *Japanese Journal of Neuropsychology*, 9: 23-29, 1993.
- TAKAHASHI, N., KAWAMURA, M., SHIOTA, J., KASAHATA, N., and HIRAYAMA, K. Pure topographic disorientation due to right retrosplenial lesion. *Neurology*, 49: 464-469, 1997.
- UNGERLEIDER, L.G., and MISHKIN, M. Two cortical visual systems. In D.J. Ingle, M.A. Goodale and R.J.X. Mansfield (Eds.), *Analysis of Visual Behavior*. Cambridge, MA: MIT Press, 1982, pp. 549-586.
- VIGHETTO, A., AIMARD, G., CONFAVREUX, C., and DEVIC, M. Une observation anatomo-clinique de fabulation (ou délire) topographique. *Cortex*, 16: 501-507, 1980.
- WHITTY, C.W.M., and NEWCOMBE, F.R.C. Oldfield's study of visual and topographic disturbances in a right occipito-parietal lesion of 30 years duration. *Neuropsychologia*, 11: 471-475, 1973.
- Kyoko Suzuki, M.D., Section of Neuropsychology, Division of Disability Science, Tohoku University Graduate School of Medicine, 2-1 Seiryomachi, Aoba-ku, Sendai, 980-8575 Japan.
E-mail: kyon@mail.cc.tohoku.ac.jp

(Received 26 February 1998; accepted 3 May 1998)