

Staged Volume Radiosurgery Followed by Microsurgical Resection: A Novel Treatment for Giant Cerebral Arteriovenous Malformations: Technical Case Report

Andrew D. Firlik, M.D., Elad I. Levy, M.D.,
Douglas Kondziolka, M.D., Howard Yonas, M.D.

Department of Neurological Surgery, University of Pittsburgh Medical Center,
Pittsburgh, Pennsylvania

OBJECTIVE AND IMPORTANCE: We describe the successful treatment of symptomatic giant arteriovenous malformations (AVMs) using staged volume radiosurgery followed by microsurgical resection.

CLINICAL PRESENTATION: A 57-year-old man presented with Spetzler-Martin Grade 5 AVMs, with persistent headaches and seizures. He had previously undergone eight attempts at AVM embolization and a craniotomy for attempted AVM resection; he had suffered four episodes of brain hemorrhaging but had made a good neurological recovery.

INTERVENTION: Because of the persistent symptoms of the patient and his history of hemorrhaging, a treatment plan based on staged radiosurgical treatments of different portions of the AVMs (three sessions, spaced 6 mo apart), followed by delayed microsurgical removal of the much-reduced residual AVMs (3 years later), was undertaken. The patient did not suffer any additional hemorrhaging episodes, his AVMs were completely removed, and he has made a good recovery.

CONCLUSION: Staged volume radiosurgery followed by microsurgical resection of the residual AVMs represents a novel treatment strategy for the management of Grade 5 AVMs that might be untreatable by any single treatment method used alone. (*Neurosurgery* 43:1223-1228, 1998)

Key words: Arteriovenous malformations, Microsurgery, Stereotactic radiosurgery

The successful treatment of giant, complex, arteriovenous malformations (AVMs) in critical brain locations remains a challenge. Multimodality treatment strategies using combinations of embolization, microsurgery, and radiosurgery allow greater numbers of patients with AVMs to be successfully treated (2, 4, 5, 8, 10, 15). We describe a new approach of staged volume radiosurgery followed by delayed microsurgical resection for a patient with giant

AVMs that could not be successfully eliminated by either radiosurgery or microsurgery alone.

CASE REPORT

A 52-year-old, right-handed man initially presented to another institution with right hemiparesis after intraventricular and left parietal hemorrhage. Angiography disclosed giant left frontoparieto-occipital AVMs, measuring $5 \times 9 \times 6$ cm,

which were determined to be unresectable at that time. The patient underwent six attempts at embolization (using Gelfoam [The Upjohn Co., Kalamazoo, MI] and polyvinyl alcohol particles) in the 2 years after diagnosis, which resulted in partial nidus obliteration, but he sustained another hemorrhage, causing right hemiparesis and moderate aphasia. He made an excellent recovery from this event, prompting two additional attempts at embolization using particles, which resulted in further partial nidus reduction. Three years after his initial presentation, the patient continued to experience debilitating headaches, seizures, and intermittent right-sided paresthesia and hemiparesis. In an attempt to ameliorate his symptoms and protect him from another hemorrhage, a craniotomy was performed to surgically ligate and directly embolize major feeding vessels. Postoperatively, the patient was hemiplegic on the right and moderately globally aphasic.

In the next 2 years, the patient made a good recovery despite an additional hemorrhage. He exhibited only subtle word-finding difficulties and only mild right hemiparesis. He continued to be plagued by severe occipital headaches, right arm paresthesia, and frequent seizures, despite appropriate anticonvulsant treatment. He sustained another intraventricular hemorrhage. When the patient was 57 years of age, given his persisting symptoms and repeated hemorrhaging, a plan was formulated to perform staged radiosurgical treatment of different volumes of the AVMs, at 6-month intervals, until all portions of the AVMs had been irradiated. We planned to follow the obliterative response with serial computed tomographic imaging, hoping that complete obliteration might be achieved in the subsequent 5 years (*Fig. 1*).

The patient underwent stereotactic angiography-guided radiosurgery on three occasions during the next 18 months. Initially, the anteroinferior component (supplied by the left internal carotid artery) and the posteroinferior component (supplied by the left poste-

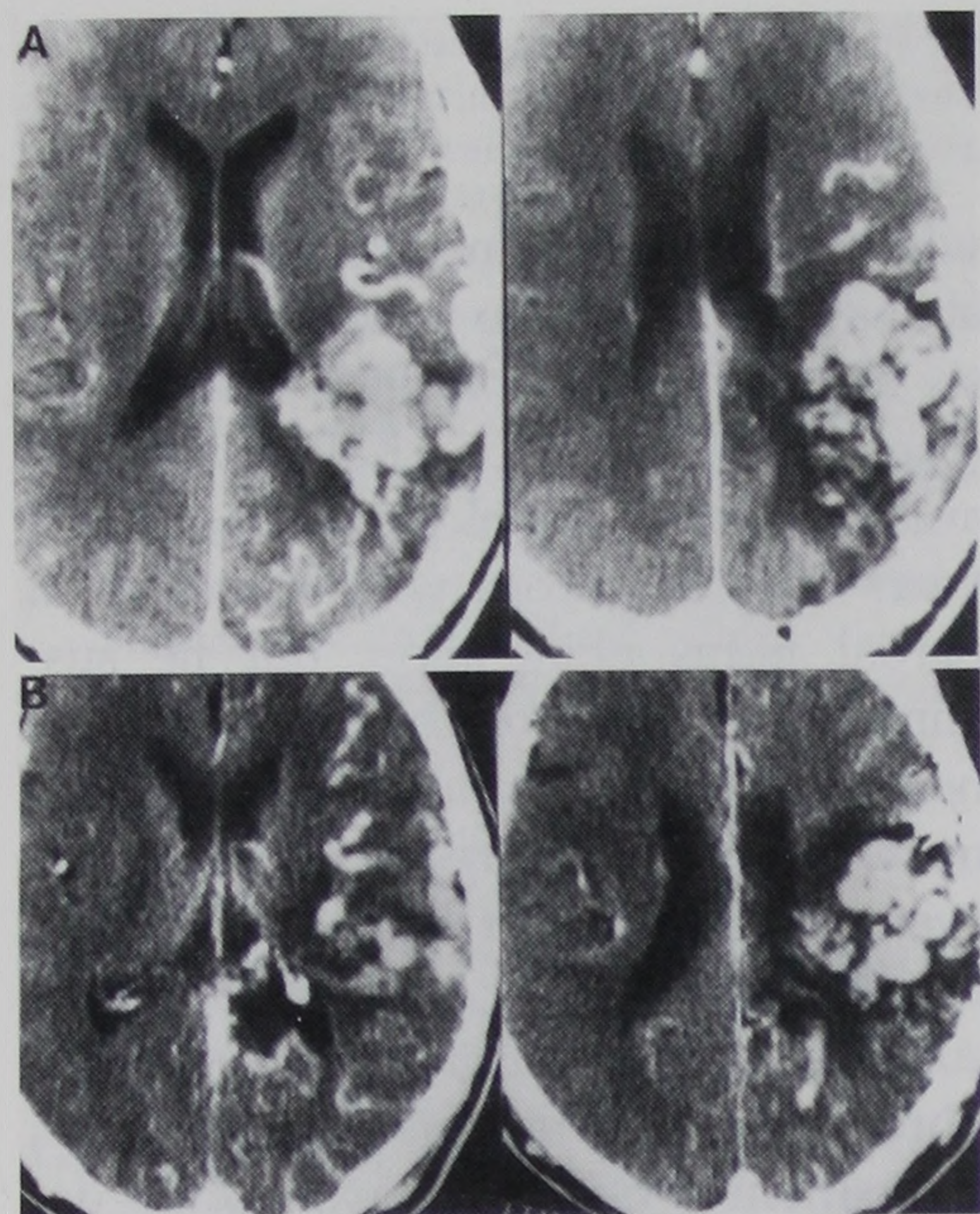


FIGURE 1. Axial contrast-enhanced computed tomographic scans before (A) and after (B) staged volume gamma knife radiosurgery. After radiosurgery, there was partial nidus obliteration and a notable decrease in the volume and caliber of large draining veins, a factor that facilitated subsequent microsurgical removal of the AVMs.

rior cerebral artery) of the AVMs were irradiated, each with 15 Gy at the 50% isodose (maximum, 30 Gy) (Fig. 2). Six months later, the anterosuperior component (supplied by the left internal carotid artery) and the posterosuperior component (supplied by the middle and posterior cerebral arteries) were irradiated, each with 15 Gy at the 50% isodose (maximum, 30 Gy) (Fig. 3). A third radiosurgical session 6 months later delivered an additional 15 Gy at the 50% isodose margin to the remaining, previously nonirradiated portion of the AVMs (maximum, 30 Gy) (Fig. 4). In the 3 years after the third radiosurgical treatment, the patient experienced no additional hemorrhagic events and no new neurological deficits. Repeat computed tomographic imaging showed partial AVM obliteration and a notable decrease in the caliber of large draining veins that had posed problems in previous operations (Fig. 1).

The AVMs were then thought to be resectable, and resection was recommended. During surgery, frameless stereotactic guidance was used. Upon exposure of the brain, the AVMs appeared

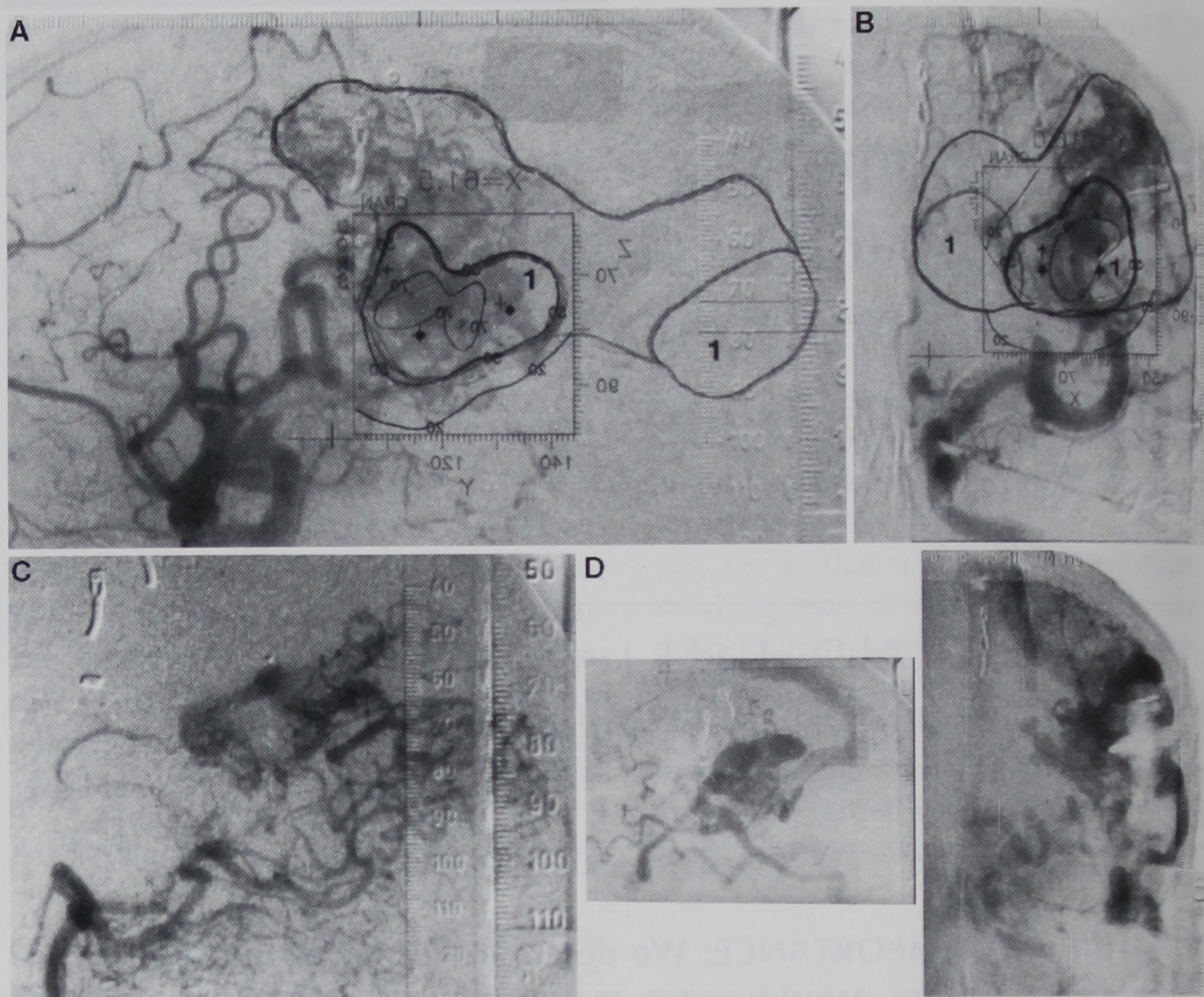


FIGURE 2. Angiograms obtained at the time of the first radiosurgical treatment. The total AVM volume is outlined in the lateral (A) and anteroposterior (B) left internal carotid artery injection angiograms. Areas encircling the numeral 1, areas targeted in the first radiosurgical treatment. Note the large portion of the AVMs supplied by the left vertebral artery (C). There was both cortical and deep venous drainage (D).

less engorged than previously, with smaller draining veins. The brain tissue surrounding the AVMs appeared firm and gliotic. A resection plane was easily developed between the AVMs and the gliotic brain tissue, facilitating complete removal. A postoperative angiogram confirmed complete AVM removal (Fig. 5). In histopathological sections, the AVMs showed marked hyalinization and thickening of blood vessel walls and occlusion or partial occlusion of some vessels with embolic material from previous embolizations, with a surrounding rim of gliotic brain tissue (Fig. 6). Postoperatively, the patient demonstrated right hemiparesis and worsened aphasia. After a 6-month follow-up period, he lives independently, exhibits mild aphasia and mild right hemiparesis, and has returned to his baseline level of functioning.

DISCUSSION

Given the considerable treatment-related morbidity and mortality rates for giant AVMs, the key to their management involves determination of whether

the risks of surgery outweigh the risks of the natural history for each lesion (1, 16). The grading scale of Spetzler and Martin (14) has proven useful (6) for preoperative assessment of the surgical risk of AVM resection. The Grade 5 AVMs described in this report would have a 19% surgical risk of a minor deficit and a 12% surgical risk of a major deficit. The patient would be expected to have a 32 to 50% overall risk of neurological deterioration early after surgery to resect the AVMs and an approximately 17% chance of a persistent late deficit (6, 14). It is important to note, however, that these risks of deficits were derived from observations of patients for whom complete resection was possible (a selected group); therefore, the surgical risks for the patient described in this report might actually have been higher. Heros et al. (8) reported a "good" or "excellent" early postoperative outcome for only 28.6% of 21 patients with Grade 5 AVMs, with a late morbidity/mortality rate of 38.4% (5). In the context of these results, Heros and Tu (7) urged

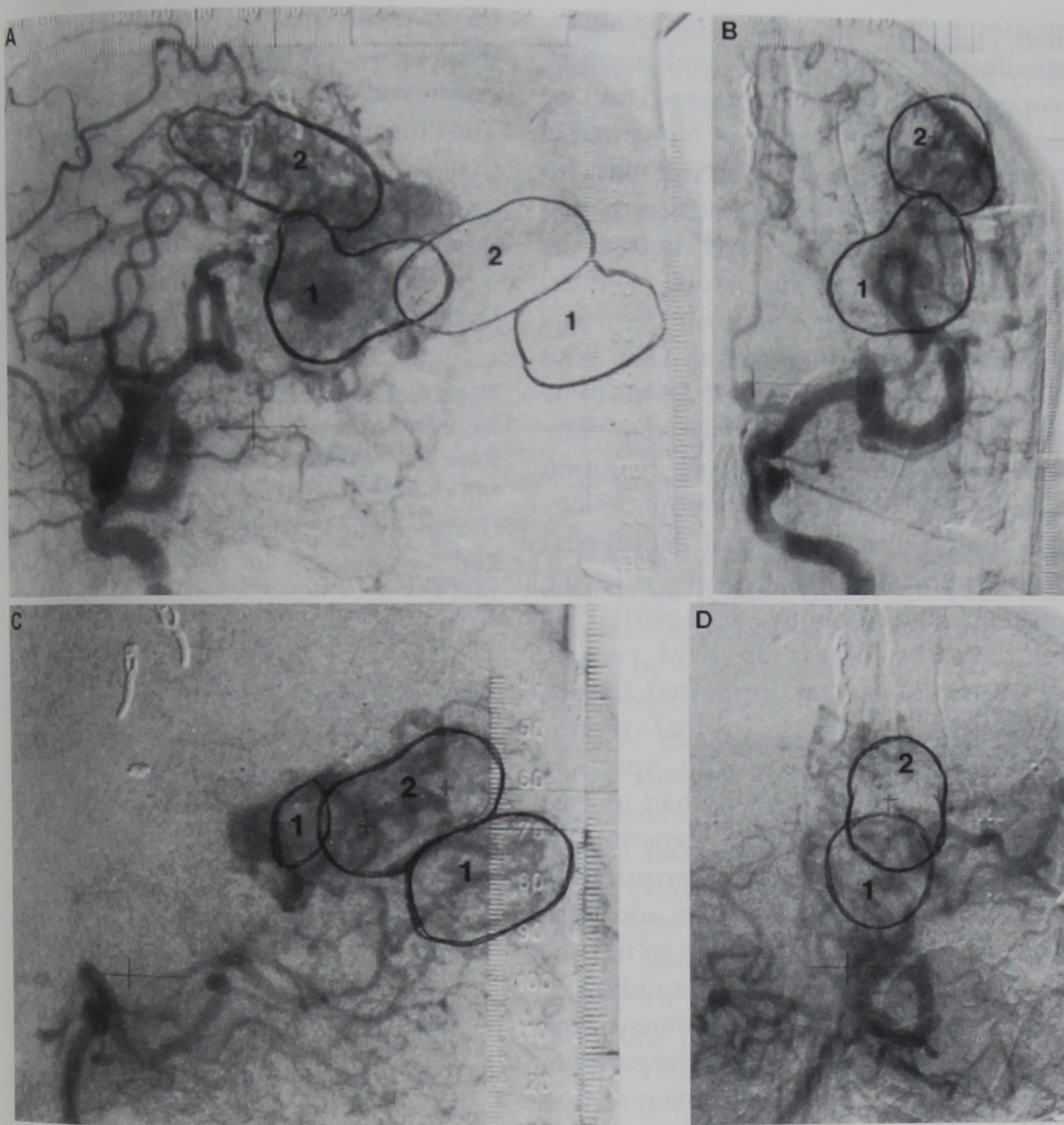


FIGURE 3. Angiograms obtained at the time of the second radiosurgical treatment. The AVMs are shown in the lateral (A) and anteroposterior (B) left internal carotid artery injection angiograms and in the lateral (C) and anteroposterior (D) left vertebral artery injection angiograms. Areas encircling the numeral 2, areas targeted in the second radiosurgical treatment. Areas encircling the numeral 1, previously treated areas.

caution in surgically approaching such AVMs and discussed a very careful decision-making process for the selection of such patients for surgery. Entering into the decision-making process described by Heros and Tu (7) for the surgical treatment of such patients, in addition to the risk factors inherent in the Spetzler-Martin classification, are such incalculable factors as the psychological reaction of the patient to the lesion, the occupation of the patient, and the prior experience of the surgeon with similar lesions. Progressive symptoms, referable to either hemorrhage, steal, or seizures, are additional reasons to intervene surgically. The patient discussed in this report demonstrated progressive deterioration resulting from headaches, seizures, and repeated hemorrhaging,

despite multiple attempts at embolization and partial resection. This repeated hemorrhaging prompted us to develop a new approach to a surgical cure of his AVMs.

Single-stage irradiation of giant AVMs is not feasible, either because of high radiation-related risks resulting from the large volume of normal tissue, surrounding the AVMs, that is irradiated (at doses sufficient to obliterate AVM vessels) or because of low obliteration efficacy with the use of clinically safe but weakly effective doses. Flickinger et al. (3) reported obliteration rates for targeted AVM tissue based on the radiation dose. A dose of 15 Gy to an AVM margin was associated with a 70% chance of total obliteration. Lower doses were much less effective; therefore, a

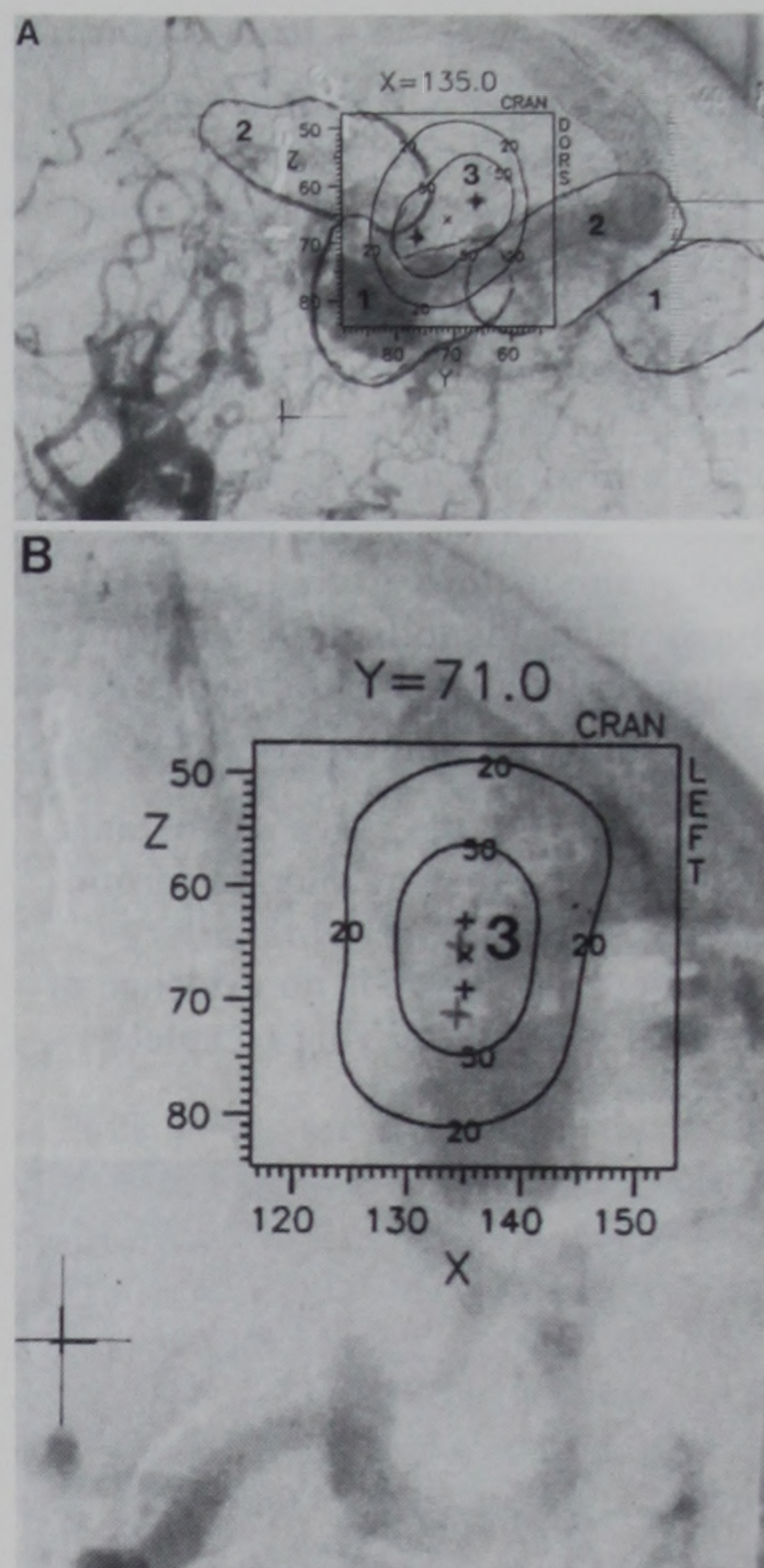


FIGURE 4. Angiograms obtained at the time of the third radiosurgical treatment. The residual AVMs are shown in the lateral (A) and anteroposterior (B) left internal carotid artery injection angiograms. Area encircling the numeral 3, area targeted in the third radiosurgical treatment. Note that the AVMs in areas treated during the first and second radiosurgical treatments (areas encircling the numerals 1 and 2, respectively) have been largely obliterated.

15-Gy dose was chosen for each radiosurgical session for the patient described in this report. When Kjellberg et al. (9) used proton beam therapy for the management of giant AVMs, the complete obliteration rate was low (<20%), although those authors thought that some protection from further hemorrhaging was achieved. Embolization alone, although sometimes effective in reducing arteriovenous shunting, is not likely to cure AVMs, as was the case for the patient described in this report; it

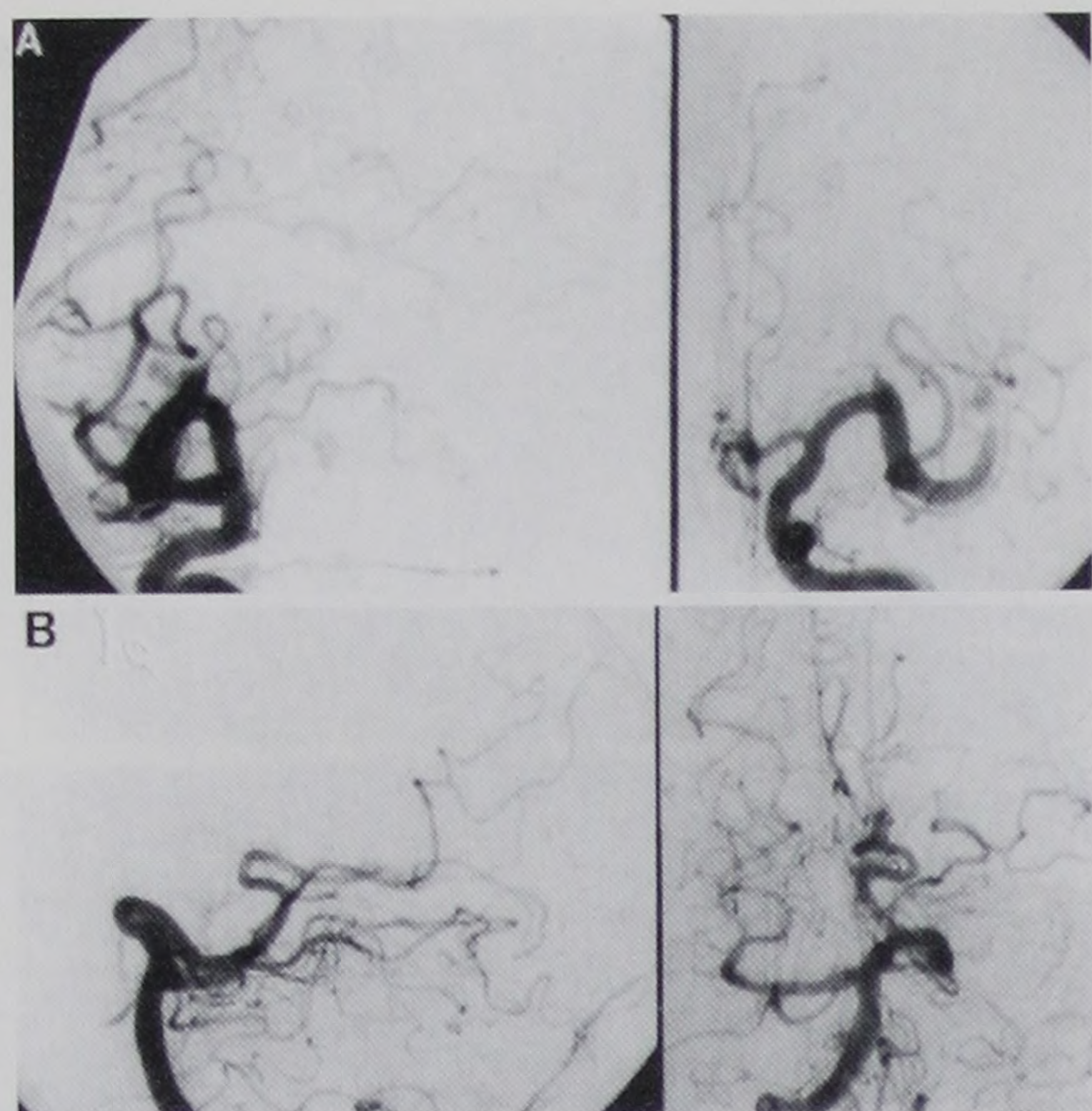


FIGURE 5. Postoperative angiograms, showing both the left internal carotid artery (A) and left vertebral artery (B) injections. There is no evidence of residual AVMs, signifying complete microsurgical removal.

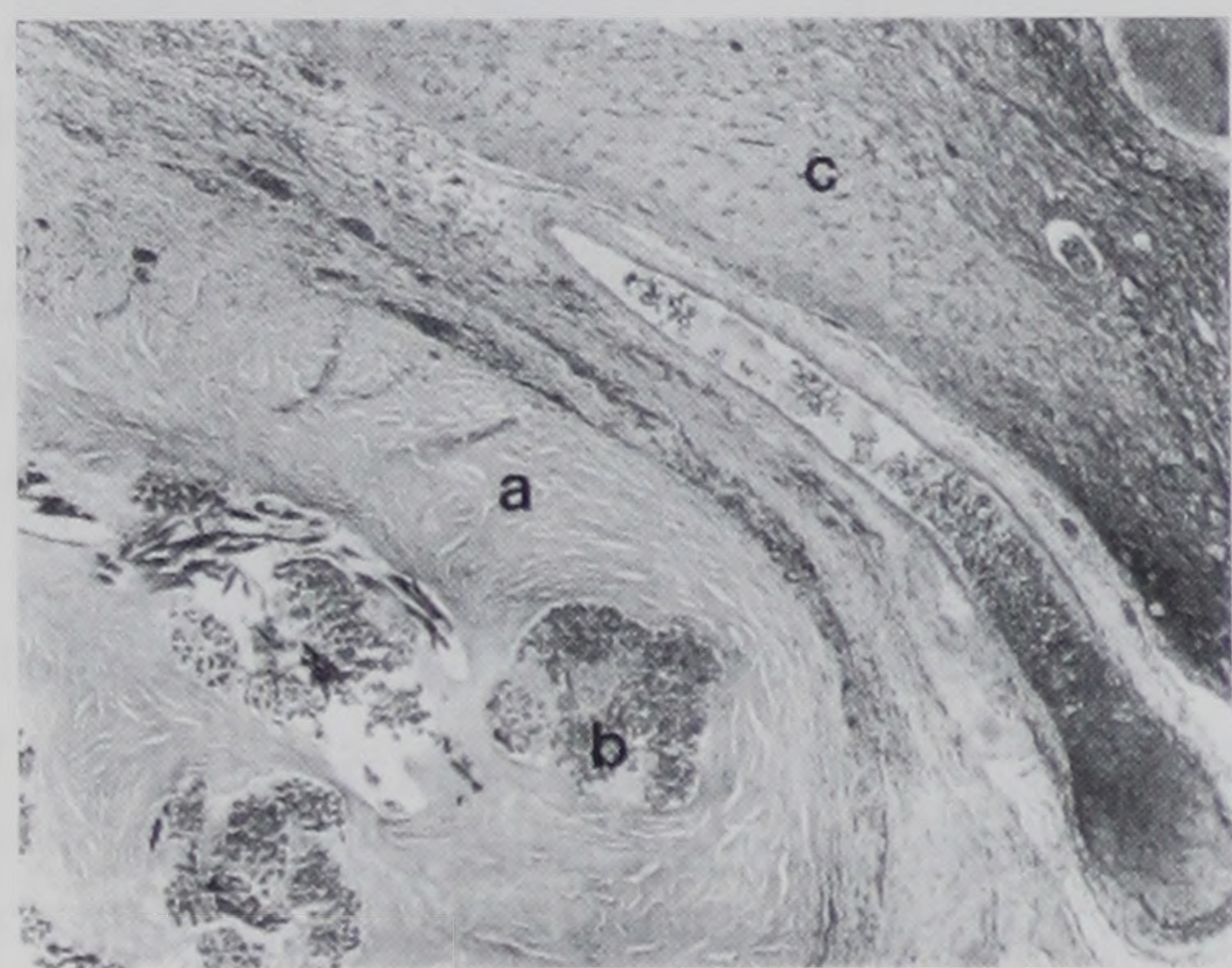


FIGURE 6. High-power photomicrograph of a histological specimen stained with Mason-trichrome stain, showing marked blood vessel wall hyalinization and thickening (area a), partial or complete obliteration of blood vessels with embolic material (area b), and a surrounding rim of gliotic brain tissue (area c).

can be a useful adjunct to microsurgery or radiosurgery (5, 17). Conventional fractionated radiotherapy has been used to manage giant AVMs, but with little success (13).

The use of repeat stereotactic radiosurgery was previously reported by our group (12); this strategy was designed to increase the likelihood of AVM cure with this modality. Those patients underwent repeat irradiation of persistent AVM volumes after radiosurgery. Most patients had not achieved complete obliteration after a single procedure, because of inade-

quacies in AVM imaging or targeting, recanalization after prior embolization, reopening of vessels compressed by hematoma, or some degree of blood vessel resistance to radiation. Success with repeat radiosurgery in that setting paved the way for the strategy used to treat the patient described in this report.

Microsurgery after radiosurgery was described by Steinberg et al. (15), who found previously irradiated AVMs to be less vascular and easier to coagulate, "facilitating quicker and safer resection with less blood loss." On histopathological analysis, they reported endothelial proliferation, hyaline deposition in the vascular endothelium, and partial or complete thrombosis of AVM vessels, all observations that supported the intraoperative findings. In that report, three of four patients with Spetzler-Martin Grade 5 AVMs who had undergone prior radiosurgery experienced "good" outcomes after microsurgical treatment of their AVMs. In addition, that group thought that, even in incompletely obliterated AVMs after radiosurgery, the small-vessel component was largely thrombosed, leaving the patients with mostly the larger arteriovenous fistulous portions of the AVMs, which were, in some cases, amenable to definitive treatment with endovascular techniques alone (11). The effects of prior radiosurgery, therefore, seem to make subsequent surgical treatment, even of very large AVMs, not only possible but also technically less difficult and potentially safer.

In our case, the staged radiosurgical treatments were separated by 6 months. This time was to allow for repair of sublethal damage to the DNA within the treated regions. Use of the specific interval of 6 months was arbitrary; 3 months was thought to be adequate. The definitive microsurgical procedure was performed 3 years after the final radiosurgical session, to allow for maximal radiation effects before surgical intervention.

CONCLUSIONS

Patients with giant AVMs in critical locations remain a challenge to neurosurgeons. The successful treatment of the patient in this report represents a novel approach, i.e., planned staged ra-

diological treatment of different portions of the AVMs, followed by delayed definitive resection of the remainder. The concept underlying this approach is that radiosurgical and microsurgical techniques can be complementary and, when combined in a thoughtful strategy, can achieve results that neither technique could achieve independently.

Received, November 4, 1997.

Accepted, May 29, 1998.

Reprint requests: Douglas Kondziolka, M.D., Department of Neurological Surgery, University of Pittsburgh Medical Center, 200 Lothrop Street, Suite B-400, Pittsburgh, PA 15213.

REFERENCES

- Auger RG, Wiebers DO: Management of unruptured intracranial arteriovenous malformations: A decision analysis. *Neurosurgery* 30:561-569, 1992.
- Deruty R, Pelissou-Guyotat I, Amat D, Mottolese C, Bascoulegue Y, Turjman F, Gerard JP: Multidisciplinary treatment of cerebral arteriovenous malformations. *Neurol Res* 17:169-177, 1995.
- Flickinger JC, Pollock BE, Kondziolka D, Lunsford LD: A dose-response analysis of arteriovenous malformation obliteration after radiosurgery. *Int J Radiat Oncol Biol Phys* 36:873-879, 1996.
- Fournier D, Terbrugge KG, Willinsky R, Lasjaunias P, Montanera W: Endovascular treatment of intracerebral arteriovenous malformations: Experience in 49 cases. *J Neurosurg* 75:228-233, 1991.
- Gobin YP, Laurent A, Merienne L, Schlienger M, Aymard A, Houdart E, Casasco A, Lefkopoulou D, George B, Merland JJ: Treatment of brain arteriovenous malformations by embolization and radiosurgery. *J Neurosurg* 85:19-28, 1996.
- Hamilton MG, Spetzler RF: The prospective application of a grading system for arteriovenous malformations. *Neurosurgery* 34:2-7, 1994.
- Heros RC, Tu Y-K: Unruptured arteriovenous malformations: A dilemma in surgical decision making. *Clin Neurosurg* 33:187-236, 1986.
- Heros RC, Korosue K, Diebold PM: Surgical excision of cerebral arteriovenous malformations: Late results. *Neurosurgery* 26:570-578, 1990.
- Kjellberg RN, Hanamura T, Davis KR, Lyons SL, Adams RD: Bragg-peak proton beam therapy for arteriovenous malformations of the brain. *N Engl J Med* 309:269-274, 1983.
- Lunsford LD, Kondziolka D, Flickinger JC, Bissonette DJ, Jungreis CA, Maitz AH, Horton JA, Coffey RJ: Stereotactic radiosurgery for arteriovenous malformations of the brain. *J Neurosurg* 75:512-524, 1991.
- Marks MP, Lane B, Steinberg GK, Fabrikant J, Levy RP, Frankel KA, Phillips MH: Endovascular treatment of cerebral arteriovenous malformations following radiosurgery. *AJNR Am Neuroradiol* 14:297-303, 1993.

12. Pollock BE, Kondziolka D, Lunsford LD, Bissonette D, Flickinger JC: Repeat stereotactic radiosurgery of arteriovenous malformations: Factors associated with incomplete obliteration. *Neurosurgery* 38:318-324, 1996.
13. Redekop GJ, Elisevich KV, Gaspar LE, Wiese KP, Drake CG: Conventional radiation therapy of intracranial arteriovenous malformations: Long-term results. *J Neurosurg* 78:413-422, 1993.
14. Spetzler RF, Martin NA: A proposed grading system for arteriovenous malformations. *J Neurosurg* 65:476-483, 1986.
15. Steinberg GK, Chang SD, Levy RP, Marks MP, Frankel K, Marcellus M: Surgical resection of large incompletely treated intracranial arteriovenous malformations following stereotactic radiosurgery. *J Neurosurg* 84:920-928, 1996.
16. Tamaki N, Ehara K, Lin T-K, Kuwamura K, Obara Y, Kanazawa Y, Yamashita H, Matsumoto S: Cerebral arteriovenous malformations: Factors influencing the surgical difficulty and outcome. *Neurosurgery* 29:856-863, 1991.
17. Viñuela F, Dion JE, Duckwiler G, Martin NA, Lylyk P, Fox A, Pelz D, Drake CG, Girvin JJ, Debrun G: Combined endovascular embolization and surgery in the management of cerebral arteriovenous malformations: Experience with 101 cases. *J Neurosurg* 75:856-864, 1991.

COMMENTS

This is an interesting case report using planned volume staging of radiosurgery to treat large frontoparieto-occipital arteriovenous malformations (AVMs). The three radiosurgical treatments were separated by 6-month intervals; 3 years later, the residual AVMs were successfully resected. Although the use and benefits of radiosurgery before microsurgery for AVM treatment have been reported previously (1), the application of staged volume radiosurgery for this patient is novel and quite interesting. I am surprised at the large extent of AVM obliteration achieved only 1 year after the first radiosurgical treatment and 6 months after the second radiosurgical treatment. The explanation for why certain AVMs are obliterated more quickly than others that are similarly treated remains obscure.

We have been able to obtain similar radiosurgical obliteration and cure of large AVMs using single-stage, heavy-charged particle radiosurgery followed by microsurgical resection (or embolization and resection), but the approach described by the authors represents an alternative strategy when access to a cyclotron radiosurgical facility is not available. The authors achieved good clinical results in an difficult case, using an in-

novative radiosurgical technique. Other groups should be encouraged to consider this approach in selected cases.

**Gary K. Steinberg
Steven D. Chang**
Stanford, California

1. Steinberg GK, Chang SD, Levy RP, Marks MP, Frankel K, Marcellus M: Surgical resection of large incompletely treated intracranial arteriovenous malformations following stereotactic radiosurgery. *J Neurosurg* 84:920-928, 1996.

The authors report a case of a patient with large (Grade 5) AVMs who was treated with staged (three sessions, separated by 6 mo) radiosurgery and eventual surgical resection. Surprisingly, in view of the postoperative angiograms, which showed minimal or no filling of any distal middle cerebral branches, the patient recovered to the point of eventually exhibiting only mild aphasia and mild right hemiparesis.

We have argued, considering our own poor results and a review of the literature that indicates similarly poor results, that most Grade 5 AVMs should be left untreated unless the patient has progressive or incapacitating symptoms and/or recurrent hemorrhaging. This patient certainly qualifies as having become progressively incapacitated and having experienced repeated hemorrhaging; therefore, I agree with the decision of the authors to treat the patient aggressively. One could argue that perhaps the same eventual results could have been obtained with more aggressive embolization and surgical resection in one stage; however, without examining all angiograms and without having participated in the treatment, it is difficult to argue this point. What seems clear from the description presented by authors is that the eventual surgical resection was easier than it would have been without radiosurgery. It is also possible that the radiation, by producing gradual obliteration not only of the AVM vessels but also of normal middle cerebral branches, allowed the patient to better tolerate surgical resection. This, of course, was achieved at the cost of exposing the patient to a continuing risk of hemorrhaging (it has not been argued convincingly that radiosurgery decreases the risk of hemor-

rhage before complete obliteration occurs) during the 4.5 years that elapsed between the first radiosurgical session and the eventual surgical resection of the still-patent AVMs. The fact that this particular patient did not experience bleeding during that time reveals little about the chances of subsequent bleeding for other patients for whom this kind of treatment may be contemplated.

In brief, this is a valuable report that offers us another option to treat patients with Grade 5 AVMs who are progressively symptomatic and/or have suffered repeated hemorrhaging. The authors devised a well-planned approach and performed it successfully.

Roberto C. Heros
Miami, Florida

Firlik et al. present a case report in which a patient with AVMs experienced repeated hemorrhaging despite embolization attempts and surgery. The authors treated the AVMs with three staged radiosurgical sessions, each treating a different part of the AVMs, at 6-month intervals. Three years later, surgical resection of the reduced AVM nidus was successful.

Radiosurgery and/or embolization may be used in combination with surgery when no single therapeutic method is likely to succeed. The use of staged radiosurgical treatment of different compartments of large AVMs, as described by the authors, is a new variation of the concept of retreating failed radiosurgical cases with another radiosurgical treatment. Some have suggested that deliberate partial irradiation of AVMs may increase the risk of hemorrhage (1). All involved in the radiosurgical treatment of AVMs await additional reports on this technique, applied to larger numbers of patients who are monitored for longer periods of time, to determine the efficacy and risks of staged radiosurgery.

William A. Friedman
Gainesville, Florida

1. Colombo F, Pozza F, Chierago G, Casentini L, De Luca G, Francescon P: Linear accelerator radiosurgery of cerebral arteriovenous malformations: An update. *Neurosurgery* 34:14-21, 1994.