

Neurology®

Auditory illusions caused by a small lesion in the right medial geniculate body

Toshio Fukutake and Takamichi Hattori
Neurology 1998;51;1469-1471
DOI 10.1212/WNL.51.5.1469

This information is current as of November 1, 1998

The online version of this article, along with updated information and services, is located on the World Wide Web at:
<http://www.neurology.org/content/51/5/1469.full.html>

Neurology® is the official journal of the American Academy of Neurology. Published continuously since 1951, it is now a weekly with 48 issues per year. Copyright . All rights reserved. Print ISSN: 0028-3878. Online ISSN: 1526-632X.



References

1. Lauritzen M, Olsen TS, Lassen NA, Paulson OB. The role of spreading depression in acute brain disorders. *Ann Neurol* 1983;14:569-572.
2. Gardner-Medwin AR, van Bruggen N, Williams SR, Ahier RG. Magnetic resonance imaging of propagating waves of spreading depression in the anaesthetized rat. *J Cereb Blood Flow Metab* 1994;14:7-11.
3. Headache Classification Committee of the International Headache Society. Classification and diagnostic criteria for headache disorders, cranial neuralgias and facial pain. *Cephalalgia* 1988;8:1-96.
4. Loenneker T, Hennel F, Henning J. Multislice interleaved excitation cycles (MUSIC): an efficient gradient-echo technique for functional MRI. *Magn Reson Med* 1996;35:870-874.
5. Woods RP, Iacoboni M, Mazziotta JC. Bilateral spreading cerebral hypoperfusion during spontaneous migraine headache. *N Engl J Med* 1994;331:1689-1692.
6. Weiller C, May A, Limmroth V, et al. Brainstem activation in human migraine attacks. *Nat Med* 1995;1:658-660.
7. Aicardi G, Guiffrida R, Rapisarda C, Albe-Fesardi D. Effects of cortical spreading depression on spontaneous activity of red nucleus cells in the guinea pig. *Arch Ital Biol* 1988;126:199-203.
8. Kumar A, Raghur R, Dhawan BN. Possible involvement of nitric oxide in red nucleus stimulation-induced analgesia in the rat. *Eur J Pharmacol* 1995;279(1):1-5.
9. Jones S, Sklar D, Dougherty J, White W. Randomized double-blind trial of prochlorperazine for treatment of acute headache. *JAMA* 1989;261:1174-1176.
10. Bures J, Buresova O, Krivanek J. The mechanism and applications of Leao's spreading depression of electroencephalographic activity. New York: Academic Press, 1974:172-179.

Auditory illusions caused by a small lesion in the right medial geniculate body

Article abstract—Although the medial geniculate body (MGB) is a well-known integration center for the central auditory pathways, auditory symptoms caused by MGB damage have not been described. We report the appearance of the auditory illusions of hyperacusis and palinacousis in a 49-year-old man without previous psychiatric or epileptic illness after a small hemorrhagic infarction located mainly in the right MGB.

NEUROLOGY 1998;51:1469-1471

Toshio Fukutake, MD; and Takamichi Hattori, MD

Auditory illusions are considered similar to metamorphopsia or visual illusions.¹ Subjective complaints include such descriptions of sounds as louder or softer than normal (paracusia), as though there were an increase or decrease in rhythm, modification of tone, or timbre; a strange or disagreeable quality; and perseveration (palinacousis).¹ These illusory phenomena have been described in several psychiatric disorders, epileptic attacks (aura or equivalent), temporal or pontine lesions, and alcohol or drug intoxication.^{1,2}

We describe a patient without previous psychiatric or epileptic illness who developed transient auditory illusions after suffering a small hemorrhagic infarction that was located mainly in the right medial geniculate body (MGB).

Case report. A 49-year-old right-handed man, a professional golfer, was referred to our hospital because of a possible TIA. In the evening 3 weeks before referral, while undergoing a more vigorous than usual foot massage by his wife, he experienced severe foot pain and suddenly heard louder sounds from the television, described as being among roaring waves or clanging bells. At that time, the television was presenting a gunshot scene from a war movie. These illusory loud sounds echoed disagreeably in his head, predominantly on the right side. He immediately switched off the television but then shouted to his wife to please turn it off because he thought that the television

might still be on. Before switching it off, he was upset and later could not remember whether he had heard other sounds. After switching it off, he could hear his own and his wife's voice without distortion. She found his speech slightly slurred. The illusory sounds ended after approximately 10 minutes. He experienced simultaneous transient sensory symptoms of numbness in the left side of the mouth and hypesthesia in the left thigh. The following day, he was examined by a neurosurgeon and a TIA was suspected. He underwent CT, which showed areas of low density in the right posteroinferior thalamus. His past medical history was unremarkable except for untreated hypertension and his smoking habit (40 cigarettes per day for more than 20 years). He had no history of psychiatric or epileptic disease and took no regular medication.

The general physical examination on referral was unremarkable, except for blood pressure of 164/94 mm Hg. Neurologic examination detected no motor or sensory deficits in the four extremities. His cognitive and mental functions were normal. Hearing was grossly normal, with no tinnitus, and the Weber test showed no lateralization. A funduscopic examination showed no papilledema or hemorrhage, and the visual fields were intact. Other cranial nerve functions also were normal. Tendon reflexes were normal, and no pathologic reflexes were elicited. Coordination was intact. Routine laboratory findings for blood and urine were all normal. Brain MRI detected areas of hyperintensity on the T2-weighted and proton-density images in the right posteroinferior thalamus, including the MGB; these areas appeared as a central isointensity with a rim of hyperin-

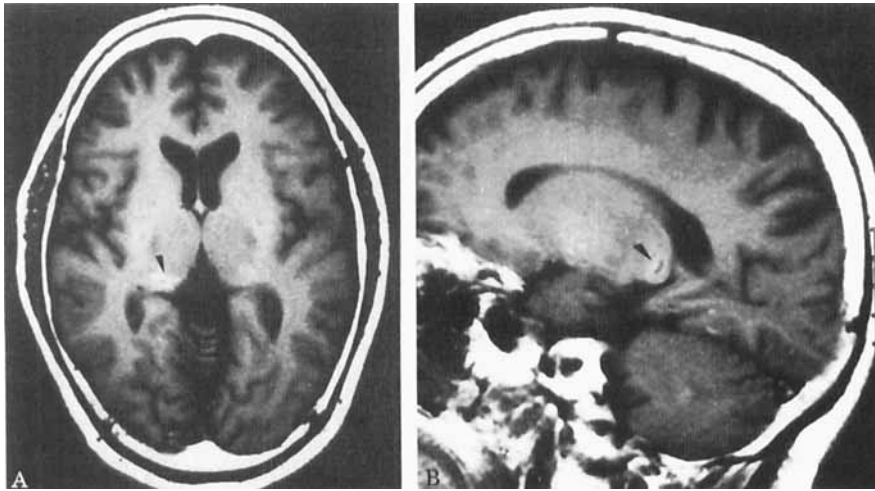


Figure. Brain MRIs show areas of central isointensity with a rim of hyperintensity (arrowheads) on the T1-weighted images (A, axial; B, parasagittal) in the right posteroinferior thalamus, including the medial geniculate body. Slice thickness: 8 mm, and gap 2 mm.

tensity on the T1-weighted images (figure). There was no abnormal flow-void findings in or around this lesion. An audiogram was normal. Follow-up MRI 2 months after onset showed abnormalities similar to those found in the first study, but the abnormal signal intensities on the T1- and T2-weighted and proton density images of the lesion were less in degree and extent.

Discussion. This patient presented with sudden-onset transient auditory illusions consisting of paracusia (hyperacusis) and palinacousis but had no persistent hearing disorder. His auditory illusions were unpleasant and more complex than neurosensory tinnitus but were less formed than temporal lobe hallucinations. They occurred alone, not in combination with auditory complex hallucinations or other perceptual illusions/hallucinations such as visual or gustatory ones. His presentation is unique considering the direct association with a well-documented (right) small posteroinferior thalamic lesion that included the MGB. The lesion is in the territory of the thalamogeniculate branch from the posterior cerebral artery and seems to be a hemorrhagic infarction. The coincidental sensory symptoms and dysarthria may have been related to posterior thalamic structures adjacent to the lesion, such as the ventral posterolateral and posteromedial nuclei.

The anatomy of the lesions underlying auditory illusions have not been extensively studied because of their frequent association with psychotic or epileptic illness.^{1,2} Temporal lobe lesions that leave hearing intact may cause auditory illusions.² Although temporal or temporoparietal lesions such as tumors or hemorrhages sometimes have been associated with auditory illusions or hallucinations,^{3,4} the localizing value is controversial.⁵ Clinicoanatomic correlation is difficult in cases of tumors or large hemorrhages that distort the brain without completely destroying it and produce edema in the surrounding tissue. As with temporal lesions, brainstem lesions may be accompanied by complex auditory illusions (pontine auditory hallucinosis).^{6,7} These auditory sense distur-

bances are considered to be more complex than neurosensory tinnitus but less formed than temporal lobe hallucinations, as in our case. They are usually associated with the impairment of hearing in one or both ears and other neurologic signs related to the brainstem lesion.

The MGB is the nuclear mass of the thalamic auditory relay nucleus, an integration center for the central auditory pathways, that receives fiber from the inferior colliculus and chiefly gives rise to the ipsilateral superior temporal gyrus via the geniculatotemporal or auditory radiation.⁸ The MGB may have roles in the spectral analysis of sound, sound pattern recognition, auditory memory, and the localization of sound in space, in addition to matching auditory information with other modalities.⁹ The presence or clinical symptomatology of pure MGB damage has not been described in humans. There was merely a patient with a postoperative restricted unilateral lesion of the MGB and inferior colliculus, reported by Fischer et al.,¹⁰ who had *no* auditory complaints despite abnormalities in her middle latency auditory evoked potentials.

We could find no case in the literature of a small MGB lesion as described in our patient. This is the first report to suggest that an MGB lesion causes auditory illusions, probably asymmetric. We speculate that there has been no description of auditory symptoms in cases of lesions involving the MGB because the reported lesions were larger and less localized.

Acknowledgments

The authors thank Dr. Masaru Ohga, Shimizu Neurosurgical Hospital, for referring the patient, and Associate Professor Shigeki Aoki and Professor Tsutomu Araki, Department of Radiology Yamaguchi Medical University, for reviewing the neuroradiological examinations of the patient.

From the Department of Neurology, Chiba University School of Medicine, Chiba, Japan.

Received May 12, 1998. Accepted in final form July 18, 1998.

References

1. Hécaen H, Albert ML. Human neuropsychology. New York: Wiley-Interscience, 1978:257-261.
2. Adams RD, Victor M, Ropper AH. Principles of neurology, 6th ed. New York: McGraw-Hill, 1997:291-292, 452.
3. Jacobs L, Feldman M, Diamond SP, Bender MB. Palinacousis: persistent or recurring auditory sensations. *Cortex* 1973;9:275-287.
4. Auzou P, Hannequin D, Cochin JP, Girard C, Augustin P. Palinacousie avec hémianacousie par lésion temporale gauche. *Rev Neurol (Paris)* 1995;151:129-131.
5. Bender MB, Diamond SP. An analysis of auditory perceptual defects with observations on the localization of dysfunction. *Brain* 1965;88:675-686.
6. Cascino GD, Adams RD. Brainstem auditory hallucinosis. *Neurology* 1986;36:1042-1047.
7. Murata S, Naritomi H, Sawada T. Musical auditory hallucinations caused by a brainstem lesion. *Neurology* 1994;44:156-158.
8. Parent A. Carpenter's human neuroanatomy, 9th ed. Baltimore: Williams & Wilkins, 1996:662-663.
9. Pandya DN. Anatomy of the auditory cortex. *Rev Neurol (Paris)* 1995;151:486-494.
10. Fischer C, Bognar L, Turjman F, Lapras C. Auditory evoked potentials in a patient with a unilateral lesion of the inferior colliculus and medial geniculate body. *Electroencephalogr Clin Neurophysiol* 1995;96:261-267.

Painful Horner syndrome due to arteritis of the internal carotid artery

Article abstract—A 44-year-old man presented with painful Horner syndrome: severe periorbital pain, ptosis, and miosis of his right eye, with intact facial sweating. Lymphadenitis at the right side of his neck preceded the symptoms. MRI and magnetic resonance angiography showed thickening of the right internal carotid artery, extending from the bifurcation to the cavernous sinus, without evidence for dissection. The patient was treated with corticosteroids with immediate improvement. Control MRI scanning was normal after 6 weeks. We conclude that the painful Horner syndrome was caused by a reactive arteritis of the right internal carotid artery.

NEUROLOGY 1998;51:1471-1472

Anna E. Bollen, MD; Allard P. Krikke, MD; and Aeiko E.J. de Jager, PhD

The combination of periorbital pain and postganglionic Horner syndrome occurs in the pericarotid syndrome. Postganglionic Horner syndrome consists of ptosis and miosis with preserved ipsilateral facial sweating. The distal sympathetic nerve fibers are compromised from the cervical superior ganglion along the internal carotid artery. The fibers involved in facial sweating are intact because they travel along the external carotid artery. The postganglionic Horner syndrome can thus be a sign of internal carotid artery pathology,²⁻⁴ which is known to cause severe periorbital pain.¹

We describe a patient with painful Horner syndrome during an infection, in whom MRI and magnetic resonance angiography (MRA) showed a circumferentially thickened internal carotid artery suggesting reactive arteritis.

Case report. A 44-year-old man with an unremarkable medical history had a painful swelling under his right jaw, clinically diagnosed by his general practitioner as a lymphadenitis. An antibiotic (cefaclor, 250 mg three times a day) was administered and in 5 days the swelling and neck pain subsided. Meanwhile, a new pain started ascending to his right eye and periorbital area. This was a severe dull pain, most severe in the morning and decreasing after lunch. When he drank a beer, the pain immediately worsened. He also had paresthesia of his right eyelid.

Neurologic examination revealed ptosis and miosis of

the right eye. There was no anhidrosis; the cranial nerves were otherwise normal. Horner syndrome was diagnosed (although not formally tested with cocaine or hydroxyamphetamine). Results of laboratory tests were normal; specifically, leukocyte count and erythrocyte sedimentation rate. Doppler duplex ultrasonography of the carotid and cranial arteries was normal. On MRI scanning, there was a thickened wall of the right carotid artery from its origin, the bifurcation, to the cavernous sinus (figure 1). The wall had an intermediate signal intensity on T1-weighted images. On T2-weighted images, the signal intensity was high. After injection of gadolinium, the wall showed slight enhancement. MRA showed a slightly narrowed lumen of the right carotid artery over the same distance from the bifurcation. There was no sign of carotid artery dissection (figure 2).

Under the diagnosis of an aseptic arteritis of the right internal carotid artery, prednisone was started (100 mg daily). In 2 days, the pain and miosis disappeared. After 5 weeks, the prednisone was tapered to 10 mg per week. After 7 weeks, the ptosis also disappeared. MRI scanning after 6 weeks showed a normal carotid artery wall (figure 3).

Discussion. Since the advent of MRI and MRA, various internal carotid artery lesions have been identified as being the cause of painful Horner syndrome. Dissections² occur, as do fibromuscular dysplasia³ and occlusion of the extracranial internal carotid artery.⁴

We describe a patient with painful Horner syn-

Auditory illusions caused by a small lesion in the right medial geniculate body

Toshio Fukutake and Takamichi Hattori

Neurology 1998;51;1469-1471

DOI 10.1212/WNL.51.5.1469

This information is current as of November 1, 1998

Updated Information & Services	including high resolution figures, can be found at: http://www.neurology.org/content/51/5/1469.full.html
References	This article cites 7 articles, 1 of which you can access for free at: http://www.neurology.org/content/51/5/1469.full.html##ref-list-1
Citations	This article has been cited by 3 HighWire-hosted articles: http://www.neurology.org/content/51/5/1469.full.html##otherarticles
Permissions & Licensing	Information about reproducing this article in parts (figures, tables) or in its entirety can be found online at: http://www.neurology.org/misc/about.xhtml#permissions
Reprints	Information about ordering reprints can be found online: http://www.neurology.org/misc/addir.xhtml#reprintsus

