



Seizure in a Woman with Lupus

Dan J. Barbero, Thomas P. Archer & Ernest L. Mazzaferri

To cite this article: Dan J. Barbero, Thomas P. Archer & Ernest L. Mazzaferri (1998) Seizure in a Woman with Lupus, *Hospital Practice*, 33:11, 51-56, DOI: [10.1080/21548331.1998.11443778](https://doi.org/10.1080/21548331.1998.11443778)

To link to this article: <http://dx.doi.org/10.1080/21548331.1998.11443778>



Published online: 24 Jun 2015.



Submit your article to this journal [↗](#)



View related articles [↗](#)

20% more work than I am, and to make matters worse, he has untoned muscles, relatively less muscle mass, and an unconditioned heart.

Couple that example with a 1996 study of cardiac ejection fractions in obese and nonobese men during exercise. The study compared increases in ejection fraction of 32 asymptomatic, healthy obese men (BMI >31; mean age, 38) with 10 nonobese volunteers who were 10 years older (BMI <25; mean age, 48). Despite their increased age, the normal-weight men had a 7.1% increase in ejection fraction in response to exercise, whereas a non-significant increase occurred in the younger obese men. The authors suggested that severely obese patients have a subclinical impairment of left ventricular systolic and diastolic function at rest and during exercise. Is it any wonder that Jake, doing more work with less muscle and with an unconditioned heart that does not respond with an augmented output as he exercises, decides that his first exercise encounter is also his last?

New Drug Therapy

Pharmacotherapy for weight loss was beginning to gain acceptance when the "phen-fen" debacle occurred. Such discouraging experiences should not disillusion physicians, however. Newer hopeful therapies include sibutramine and tetrahydrolipostatin, another drug that showed prom-

ise in clinical trials. Once-daily sibutramine therapy has demonstrated efficacy without evidence of increased risk of cardiac valvular disease. Unfortunately, despite documentation of sibutramine's safety, some medical experts refuse to recommend it.

It is time to acknowledge that our uphill battle against obesity reflects the limitations of scientific knowledge, not the energy or earnestness of our patients. We must offer patients available tools that we believe best balance risk and benefit. First of these, perhaps, will be our acceptance and understanding.

Selected Reading

Carek PJ, Sherer JT, Carson DS: Management of obesity: Medical treatment options. *Am Fam Phys* 55:551, 1997

Ferraro S et al: Left ventricular systolic and diastolic function in severe obesity: A radionuclide study. *Cardiology* 87:347, 1996

Foster, GD et al: What is a reasonable weight loss? Patients' expectations and evaluations of obesity treatment outcomes. *J Consult Clin Psychol* 65:79, 1997

Foster G et al: Resting energy expenditure, body composition and excess weight in the obese. *Metabol* 37:467, 1988

Seizure in a Woman with Lupus

*Dan J. Barbero, Thomas P. Archer,
and Ernest L. Mazzaferri
Ohio State University*

Clinical Pearl

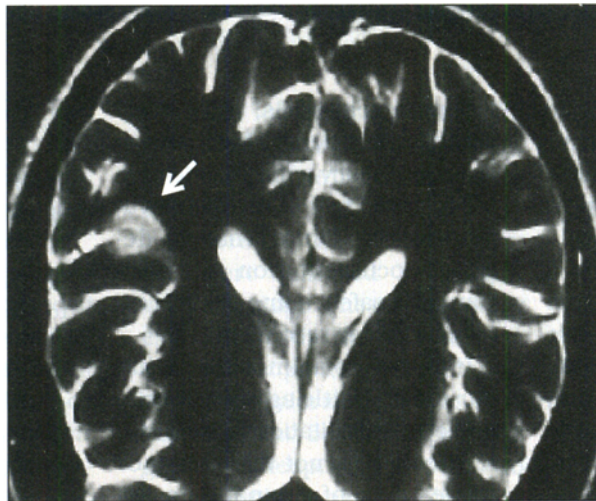
Dr. Barbero is a junior resident, Dr. Archer is Chief Resident, and Dr. Mazzaferri is Professor and Chairman, Department of Internal Medicine, The Ohio State University College of Medicine and Public Health, Columbus.

A 22-year-old woman with a six-year history of systemic lupus erythematosus (SLE) came to the emergency department after having had a generalized seizure at home. She reported a three-week history of headaches, fatigue, arthralgias, intermittent fever, and inability to concentrate. Because of these symptoms, her rheumatologist started her on pulse intravenous

cyclophosphamide therapy every three weeks. The patient had received her last dose two weeks prior to presentation. Since her diagnosis of SLE, she had been treated with hydroxychloroquine and intermittent corticosteroid therapy and had been clinically stable. Her other medications were nifedipine, ibuprofen, and an oral contraceptive. She denied a history of seizures, head trauma, nausea or vomiting, weakness or numbness, nuchal rigidity, or change in vision. She did not smoke and used alcohol rarely. A cousin also had SLE.

Physical Examination

Vital signs: temperature, 36.1°C; pulse, 101 bpm; respirations, 18



per min; blood pressure 113/66 mm Hg. General appearance: arousable, postictal. HEENT: erythematous rash over malar eminences, otherwise unremarkable. Neck: no lymphadenopathy or thyromegaly. Lungs: clear. Cardiac: no rub. Abdomen: benign. Extremities: no cyanosis or edema. Neurologic: postictal, non-focal.

Laboratory Findings

White blood cell count, 8,300/mm³ (normal differential); hemoglobin, 11.5 gm/dL; mean corpuscular volume, 90 μm³; platelets, 243,000/mm³. Serum electrolytes, urea nitrogen, and creatinine, normal. Erythrocyte sedimentation rate (Westergren), 33 mm/hr. C3, 32 mg/dL (normal, 85-185); C4, 7 mg/dL (15-45). Liver

function studies, activated partial thromboplastin time, and prothrombin time, normal. Antiphospholipid antibody, negative; antinuclear antibodies, positive (>1:320); dsDNA, negative. Cerebrospinal fluid: glucose, 99 mg/dL; protein, 50 mg/dL; white blood cells, 2/mm³ (0 % neutrophils, 70% lymphocytes, 19% monocytes, 11% macrophages); red blood cells, 9/mm³; VDRL, negative; HSV PCR, negative. Magnetic resonance image (MRI) of the head: shown.

Table 1. Pathogenesis of NPPE

Primary
Vascular occlusion from immune-complex-mediated or antibody-mediated injury
Cerebral dysfunction from antibodies to brain tissue (antineuronal, antiribosomal P protein) or cytokines
Secondary
Infection
Cerebrovascular accidents
Hypertensive encephalopathy
Metabolic encephalopathy
Hypercoagulable states
Drugs

Adapted from Boumpas et al

What Is the Likely Diagnosis?

This patient has neuropsychiatric lupus erythematosus (NPPE) or lupus cerebritis. The MRI demonstrates a small region (arrow) of high signal intensity in the left temporoparietal region consistent with cerebritis or infarction.

NPPE, which occurs in up to two-thirds of patients with SLE, may present with a variety of neurologic and psychiatric manifestations. Symptoms may appear at any time during the course of SLE but typically occur within the first

two years. They result directly from immune-mediated injury to the central nervous system (primary events), or secondarily from SLE involvement in other organs, complications of therapy, or both (Table 1). Primary events typically occur in a setting of clinically or serologically active SLE and rarely occur as an isolated event.

The pathogenesis of NPLE is uncertain. There are few histologic findings despite severe clinical manifestations. The most frequent finding is multiple cerebral cortical microinfarctions; however, vasculitis and thrombosis are rare. The presenting manifestations may be focal symptoms involving the brain, spinal cord, and peripheral nervous system, but the most common are organic brain syndrome (OBS), psychiatric disturbances, and seizures (Table 2).

OBS is characterized by various degrees of impaired cognition and memory, apathy, and disorientation, in the absence of a secondary cause (i.e., infection or drugs). OBS affects about 20% of patients with SLE, but some degree of cognitive impairment has been demonstrated in up to 70% of patients with SLE and may occur without other symptoms. In severe cases, OBS may progress rapidly to delirium, stupor, or coma, while in others it may appear as a slowly progressive dementia. Because cognitive deficits are often difficult to detect, a baseline evaluation should be done in all SLE patients.

Psychiatric disturbances have long been recognized as a manifestation of SLE. Overt psychosis develops in about 15% of patients with SLE. In the past, psychosis was attributed to corticosteroid therapy, but now psychosis is recognized to worsen after cessation of steroid therapy, confirming the disorder's direct relationship to SLE in many cases. There is an association between lupus psychosis and antiribosomal P protein antibodies that may help to distinguish it from a drug-induced cause. Major depression, which commonly occurs in SLE, is also more typically a manifestation of SLE rather than a reactive process. Other less common psychiatric manifestations of SLE are anxiety, personality disorders, phobias, and manias.

Grand malignant seizures, which are the most common type of seizure to occur in NPLE, are usually self-limited, although status epilepticus is not uncommon. Seizures may occur in isolation or in association with other neurologic events such as strokes, intracranial hemorrhage, or vasculitis.

Primary NPLE is a clinical diagnosis that depends on excluding other causes of central nervous system symptoms, most notably infection and medication side effects. Although cerebrospinal fluid is typically normal in NPLE, pleocytosis may be indicative of lupus cerebritis instead of infection. Electroencephalography is frequently abnormal but is non-

specific. MRI is the preferred imaging technique because up to 80% of NLPE patients with a normal computed tomographic scan have an abnormal MRI. Unfortunately, the MRI manifestations are variable and none is specific for lupus cerebritis. Patients with OBS, psychosis, or depression often have a normal MRI, whereas patients with generalized seizures frequently have evidence of multiple small microinfarcts, as seen in our patient. Serum antineuronal antibodies are commonly found in patients with OBS or cognitive dysfunction, while antiribosomal-P antibodies are seen in 45% to 90% of SLE patients presenting with psychosis or major depression. However, the presence of these antibodies is not diagnostic of the syndromes.

Table 2. Major Manifestations of NLPE

Diffuse Cerebral Dysfunction	
Organic brain syndrome	(20%)
Psychosis	(10%)
Major affective disorder	(<1%)
Focal Cerebral Dysfunction	
Seizures, all types	(15%)
Cerebrovascular accidents	(5%)
Transverse myelitis	(1%)
Movement Disorders	
Peripheral Neuropathy	
Autonomic Neuropathy	
Adapted from Boumpas et al	

Treatment differs according to the clinical presentation, its severity, and underlying etiology. Patients presenting with mild diffuse manifestations may require only symptomatic treatment, whereas those with more severe or progressive diffuse presentations may benefit from immunosuppressant drugs. Corticosteroids are the agent of choice, although there have been no controlled trials proving their utility or that of other cytotoxic medications in the treatment of NLPE.

While the majority of NPPE patients with diffuse symptoms appear to recover, studies suggest that there is often residual cognitive dysfunction. Status epilepti-

cus, strokes, and coma are poor prognostic signs.

Our patient had two additional seizures on the day of admission and was treated with phenytoin, corticosteroids, and cyclophosphamide. When discharged, she had no evidence of residual deficits.

Clinical Pearls

- 1. Neuropsychiatric lupus erythematosus (NPPE) occurs in up to two thirds of SLE patients.**
- 2. The most common manifestations are organic brain syndrome, psychiatric disturbances, and seizures.**
- 3. NPPE symptoms typically occur within the first two years after SLE is diagnosed.**

4. NPPE is diagnosed by excluding other causes of neurologic and psychiatric symptoms.

Selected Reading

Boumpas DT et al: Systemic lupus erythematosus: Emerging concepts. I: Renal, neuropsychiatric, cardiovascular, pulmonary, and hematologic disease. *Ann Intern Med* 122:940, 1995

Ginsburg KS et al: A controlled study of the prevalence of cognitive dysfunction in randomly selected patients with systemic lupus erythematosus. *Arthritis Rheum* 35:776, 1992

West SG: Neuropsychiatric lupus. *Rheum Dis Clin North Am* 20:129, 1994

Fundusoscopic Abnormalities in a Woman with Diabetes

*Thomas P. Archer and Ernest L. Mazzaferri
Ohio State University*

Clinical Pearls

Dr. Archer is Chief Resident and Dr. Mazzaferri is Professor and Chairman, Department of Internal Medicine, The Ohio State University College of Medicine and Public Health, Columbus.

A 34-year-old African American woman with insulin-dependent diabetes mellitus (IDDM) presented as a new patient. She had no complaints and was feeling well. The patient had had IDDM since age 13. She had experienced episodes of ketoacidosis as an adolescent, but had not required hospitalization for more than 20 years.

She seemed to understand IDDM management, had not had significant episodes of hypoglycemia, and felt that her disease was under good control. She took intermediate-acting insulin (20 units) and regular insulin (5 units) before breakfast, and intermediate-acting insulin (10 units) before bedtime. Her fasting blood glucose concen-