

Case Reports

Motor Organization After Early Middle Cerebral Artery Stroke: A PET Study

Ralph-Axel Müller, PhD*,
Craig E. Watson, MD[†], Otto Muzik, PhD*,
Pulak K. Chakraborty, PhD[‡], and
Harry T. Chugani, MD*^{†‡}

The brain organization for movement in a 20-year-old man with a history of intrauterine or perinatal right middle cerebral artery stroke was studied. [¹⁵O]-water positron emission tomography demonstrated a normal pattern of activation during finger movement in the right hand. Movement of the hemiparetic left hand was associated with activation in the supplementary motor area bilaterally and in the left premotor cortex. Blood flow increase was observed in the right temporal lobe adjacent to an extensive area of encephalomalacia, suggesting atypical motor function in the temporal lobe. © 1998 by Elsevier Science Inc. All rights reserved.

Müller R-A, Watson CE, Muzik O, Chakraborty PK, Chugani HT. Motor organization after early middle cerebral artery stroke: A PET study. *Pediatr Neurol* 1998;19:294-298.

Introduction

Functional imaging studies on postlesional reorganization in the motor domain in the past have focused mostly on adult stroke patients. Motor recovery has been reported to be associated with activations in the precentral and postcentral sulci [1], as well as the insula and the inferior parietal lobe [2]. A study including pediatric patients suggested an enhanced potential for interhemispheric motor reorganization after lesion in the first few years of life

(as compared with late lesion onset) [3]. Although some studies have reported homotopic interhemispheric reorganization into primary sensorimotor cortex of the undamaged hemisphere [2,4,5], the authors' data suggest predominantly nonhomotopic reorganization (i.e., reallocation of motor functions into secondary motor regions and regions that are not primarily dedicated to motor function in the normal brain) [3,6,7]. In the present study, motor organization in a patient with early intrauterine or perinatal stroke involving the motor cortex of the right hemisphere was evaluated.

Patient and Methods

The patient is a 20-year-old right-handed man with chronic intractable epilepsy. There were no indications of perinatal complications, but slow achievement of early milestones and left hemiparesis were noted soon after birth. The first seizure occurred at approximately 8 years of age. Cognitive delays were evident throughout childhood. Current seizure frequency is variable (about one daily with seizure-free periods). Seizures are complex partial and typically characterized by a blank stare with impaired awareness and responsiveness, lip smacking, and automatisms, especially in the right upper limb. Postictally, the patient is confused and occasionally demonstrates language deficits. Current anti-epileptic medications are valproic acid and phenytoin.

On neurologic examination, mild mental retardation was noted. Muscle tone was increased on the left side of the body, and hemiparesis was mild to moderate on the left with greater involvement of the upper rather than the lower limb. Tendon reflexes were brisker on the left (3/4) compared with the right (2/4), and plantar reflexes were flexor on the right and equivocal on the left. Sensory examination (including tactile localization and stereognosis, pain, vibration, and joint position) and cerebellar examination were within normal limits. Gait and stance were mildly hemiparetic. Neuropsychologic testing demonstrated borderline intellectual functioning (FSIQ: 72, VIQ: 75, and PIQ: 70), with moderate-to-marked impairment of language and verbal memory and mild-to-moderate visuospatial deficits.

The patient underwent video electroencephalogram monitoring for 5 days during which time he had five clinical and electrographic complex partial seizures, one of them with secondary generalization. No subclinical seizures were recorded during the entire period of monitoring, which was carried out with automated seizure and spike detection software and 24-hour technician surveillance.

Magnetic resonance imaging demonstrated a porencephalic cyst and encephalomalacia in the right frontotemporal region (in the distribution of the middle cerebral artery) characteristic of an intrauterine or perinatal vascular event (Figs 1, 2). Evaluation failed to uncover the cause of the stroke. Family history for stroke and myocardial infarction is positive. A 2-deoxy-2-[¹⁸F]fluoro-D-glucose positron emission tomography (PET) scan demonstrated absent glucose metabolism in the distribution of the right middle cerebral artery and hypometabolism in the remaining neocortex, lentiform nucleus, and thalamus of the right hemisphere. Normal glucose metabolism was seen in the left cerebral hemisphere and both cerebellar hemispheres.

From the Departments of *Pediatrics; [†]Neurology; and [‡]Radiology; Wayne State University Medical School; Detroit, Michigan.

Communications should be addressed to: Dr. Chugani; Children's Hospital of Michigan; 3901 Beaubien Boulevard; Detroit, MI 48201. Received January 26, 1998; accepted April 13, 1998.

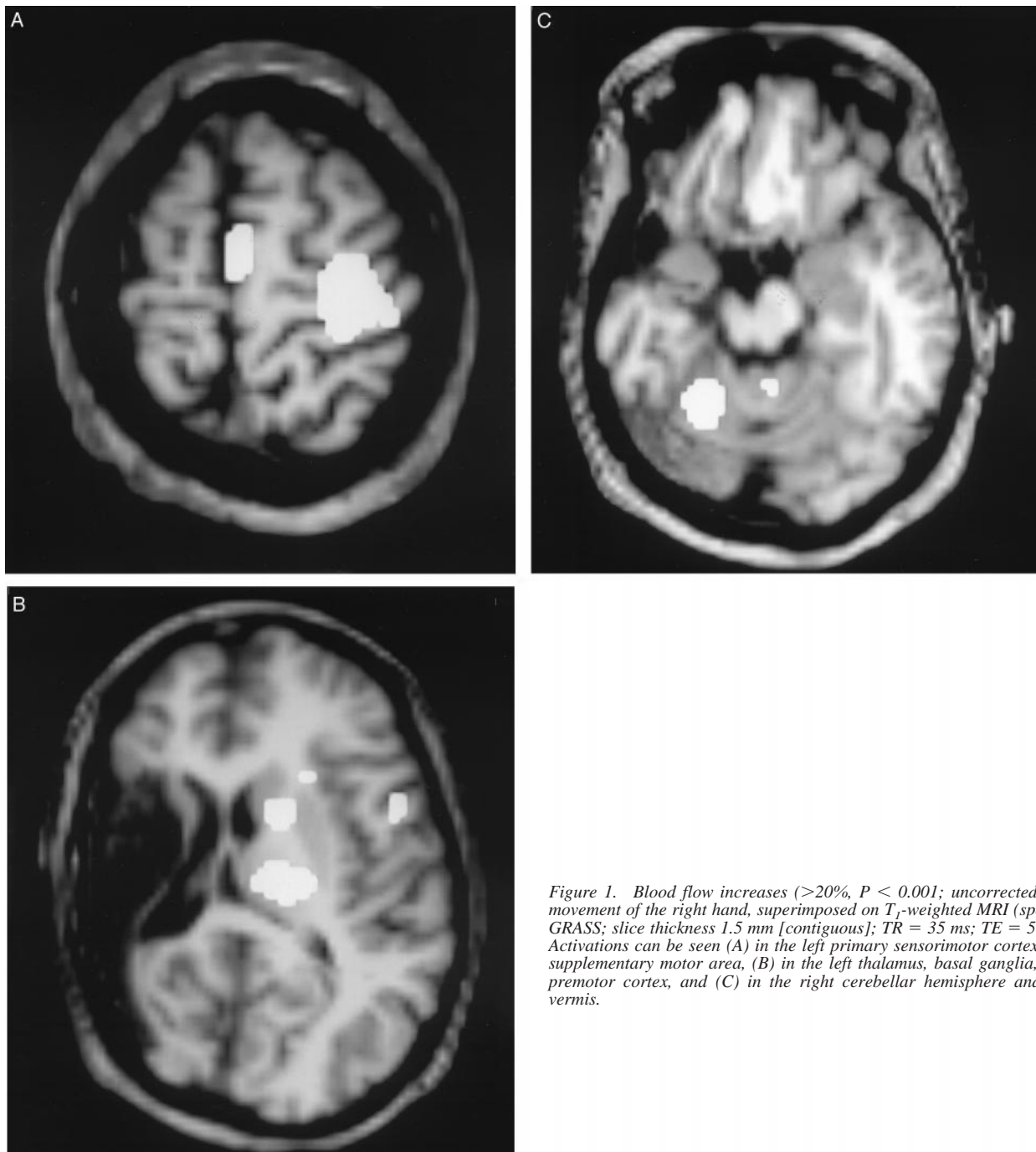


Figure 1. Blood flow increases ($>20\%$, $P < 0.001$; uncorrected) for movement of the right hand, superimposed on T_1 -weighted MRI (spoiled GRASS; slice thickness 1.5 mm [contiguous]; TR = 35 ms; TE = 5 ms). Activations can be seen (A) in the left primary sensorimotor cortex and supplementary motor area, (B) in the left thalamus, basal ganglia, and premotor cortex, and (C) in the right cerebellar hemisphere and the vermis.

[^{15}O]-water PET Study. Scans were performed on a Siemens EXACT HR positron scanner [3]. The following three experimental conditions, each scanned twice in counterbalanced order, were examined: (1) resting (2) self-paced movement of the right hand, and (3) self-paced movement of the left hand (all with eyes covered). Sequential finger-thumb tapping was performed in the right hand. Individual finger movements were not possible in the hemiparetic left hand, and the patient instead moved all fingers synchronously. Both types of movement have been noted to be associated with similar activation patterns in normal adults [8]. During the left-hand movement condition, slight movement of the left foot was observed. Mirror movement in the right hand was minimal. No seizure

activity was observed during the entire session, which was confirmed by the patient who additionally reported that no seizures had occurred during a period of at least 12 hours before the [^{15}O]-water PET session.

Automated software [9] was used for motion correction, pixel normalization, image subtraction (motor minus rest), and statistical parametric mapping on the basis of smoothness estimation and a pooled-variance t (Z)-statistic model. In single-case PET studies, statistical power is limited due to the low number of scans entering into each task comparison. In such cases, a significance threshold of $P < 0.001$ (uncorrected) usually is accepted as providing reasonable protection from false positives [10]. However, a more stringent threshold ($P < 0.0001$; uncorrected) was

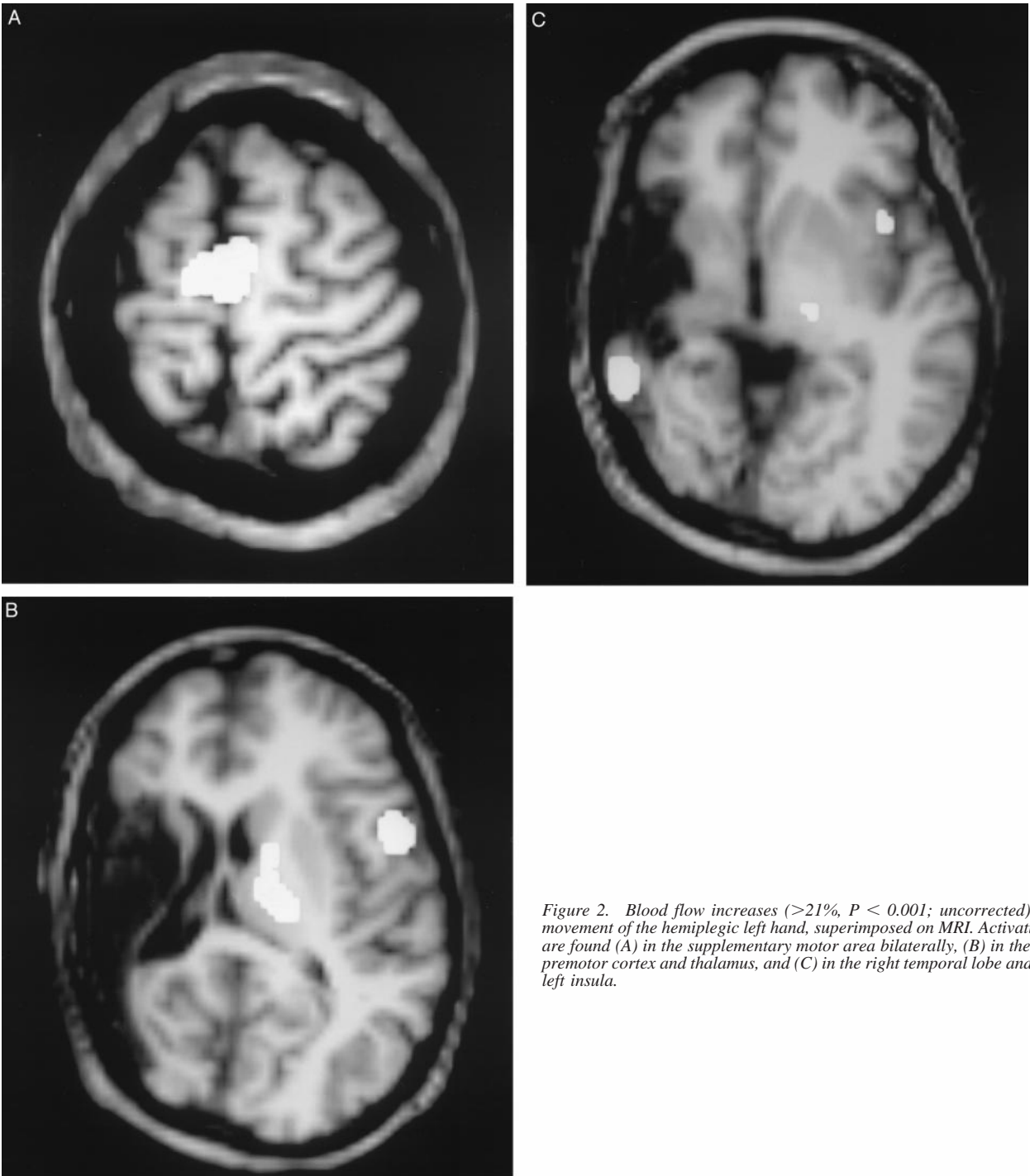


Figure 2. Blood flow increases (>21%, $P < 0.001$; uncorrected) for movement of the hemiplegic left hand, superimposed on MRI. Activations are found (A) in the supplementary motor area bilaterally, (B) in the left premotor cortex and thalamus, and (C) in the right temporal lobe and the left insula.

applied here, except for purposes of illustration (Figs 1, 2). In addition to the pixel-based analyses, mean blood flow changes for 26 predetermined regions of interest (ROIs), each identified on at least two planes of the coregistered volumetric magnetic resonance imaging (three-dimensional spoiled gradient-echo technique), were computed for descriptive purposes (Table 1). Coregistration was achieved using semiautomated software [11].

Results

For movement of the unaffected right hand, significant activation peaks were found in the left thalamus and the

left primary motor cortex, as well as the vermis and the right anterior cerebellum (see Table 1; Fig 1). Mean regional blood flow increase also was seen in the left supplementary motor and premotor cortices (medial and lateral portions of Brodmann's area 6), the right anterior cingulate gyrus, and the left basal ganglia.

Movement of the hemiparetic left hand was associated with significant activation in the supplementary motor area (Brodmann's area 6), with a peak close to the midline (Fig 2A), as well as in the left premotor cortex and the left

Table 1. Cerebral blood flow changes per region of interest

Region of Interest	Brodmann's Areas	Side of Brain	Movement Right Hand			Movement Left Hand		
			Mean Regional Change (%)	Activation Peaks		Mean Regional Change (%)	Activation Peaks	
				% Increase	z Score		% Increase	z Score
Primary sensorimotor	1-5, 43	L	+8.0	33.2	4.8 [†]	-0.8		
		R	-0.4			+2.1		
Premotor	6 (middle/inferior)	L	+7.2			+5.3	27.4	3.8*
		R	+1.0			+2.1		
Supplementary motor	6 (superior/mesial)	L	+12.0	27.1	3.9*	+10.8	33.3	4.6 [†]
		R	+3.5			+9.8		
Anterior cingulate	24, 32	L	+2.0			-1.2		
		R	+6.4			+7.0		
Inferior frontal	44-45, 47 (posterior)	L	-2.6			+8.4		
		R	+0.8			+5.6		
Superior temporal	22, 41-42	L	-9.1			-7.3		
		R	could not be identified			could not be identified		
Middle temporal	21	L	-13.0			-9.0		
		R	+3.1			+13.9		
Anterior temporal	38	L	-7.4			+1.4		
		R	+1.5			+5.0		
Inferior temporal	20	L	-11.0			-7.3		
		R	+0.7			+4.5		
Caudate nucleus		L	+8.3			+8.2		
		R	-0.7			-0.4		
Lenticular nuclei		L	+8.8			+7.3		
		R	+3.9			+2.5		
Thalamus		L	+14.6	34.0	4.9 [†]	+15.0	26.8	3.7*
		R	+0.3			+3.6		
Vermis			+13.9	32.8	4.7 [†]	+10.4		
Cerebellar hemispheres		L	+1.3			+2.7		
		R	+8.0			31.9		

* $P < 0.0001$ (uncorrected); [†] $P < 0.00001$.

thalamus. Activation also was found in the lateral temporal cortex of the right hemisphere—peak increase was 30.4%; $z = 4.2$; $P = 0.000014$, uncorrected (Fig 2C). Mean regional blood flow increase was further seen in the right anterior cingulate gyrus and the inferior frontal lobe bilaterally. The left basal ganglia, the vermis, and the right cerebellum again demonstrated pronounced increases (Fig 2B).

Discussion

These findings are consistent with a previous study suggesting pronounced motor reorganization after early unilateral lesion [3]. In this patient, movement of the unaffected right hand was associated with a normal pattern of activations in contralateral primary and secondary motor areas, in contralateral subcortical regions, and in the ipsilateral cerebellum [2,8]. In contrast, when the patient moved the hemiparetic left hand, there was little activation

in contralateral primary motor cortex but pronounced activation in the supplementary motor areas bilaterally and the premotor cortex of the nonlesional left hemisphere, ipsilateral to the movement. Atypical activation also was seen in the bilateral inferior frontal lobe and the ipsilateral basal ganglia and thalamus. Most of these findings are comparable with results from earlier studies. In adult stroke patients, reorganization into cortical regions adjacent to the primary motor region has been reported [2,12]. A PET study on a 6-year-old boy 3 years after hemispherectomy demonstrated interhemispheric motor reorganization primarily into premotor and supplementary motor areas rather than the primary motor cortex [7]. This finding also is supported by findings in two patients with Sturge-Weber syndrome and advanced unilateral calcification [6].

A remarkable finding was the robust activation in the lateral temporal cortex of the lesional right hemisphere during movement of the affected left hand. Although the

temporal lobe normally assumes auditory and higher visual functions, severe disruption of normal brain development, as seen in this patient, may allow recruitment of temporal cortex for functions in other modalities. Cross-modal plasticity has been demonstrated in animal models [13] and in human studies. In early blind subjects, for example, tactile processing in designated visual cortex of the occipital lobe has been demonstrated [14,15]. The findings of the present study may reflect a potential for cross-modal plasticity with regard to motor control. However, in this patient motor-related function appears to have invaded the designated territory of an intact sensory modality (audition), suggesting coexistence of auditory and motor functions within the temporal lobe. Furthermore, results from a single-case study should be interpreted with caution; no general conclusions should be drawn before additional early lesion patients demonstrating similar function reorganization have been reported.

The authors thank Satoshi Minoshima for support regarding statistical image analysis and Joy Herron for additional help.

References

- [1] **Seitz** RJ, Huang Y, Knorr U, Tellmann L, Herzog H, Freund HJ. Large-scale plasticity of the human motor cortex. *Neuroreport* 1995; 6:742-4.
- [2] **Chollet** F, Di Piero V, Wise RJS, Dolan RJ, Frackowiak RSJ. The functional anatomy of motor recovery after stroke in humans: A study with positron emission tomography. *Ann Neurol* 1991;29:63-71.
- [3] **Müller** R-A, Rothermel RD, Muzik O, Behen ME, Chakraborty PK, Chugani HT. Plasticity of motor organization in children and adults. *Neuroreport* 1997;8:3103-8.

- [4] **Sabatini** U, Toni D, Pantano P, Brughitta G, Padovani A, Bozzao L. Motor recovery after early brain damage: A case of brain plasticity. *Stroke* 1994;25:514-7.
- [5] **Nirako** AC, Rösler KM, Ozdoba C, Heid O, Schroth G, Hess CW. Human cortical plasticity: Functional recovery with mirror movements. *Neurology* 1997;48:1090-3.
- [6] **Müller** R-A, Chugani HT, Muzik O, Rothermel RD, Chakraborty PK. Language and motor functions activate calcified hemisphere in patients with Sturge-Weber syndrome: A positron emission tomography study. *J Child Neurol* 1997;12:431-7.
- [7] **Müller** R-A, Chugani HT, Muzik O, Mangner TJ. Brain organization of motor and language functions following hemispherectomy: A [¹⁵O]-water PET study. *J Child Neurol* 1998;13:16-22.
- [8] **Colebatch** JG, Deiber M-P, Passingham RE, Friston KJ, Frackowiak RSJ. Regional cerebral blood flow during voluntary arm and hand movements in human subjects. *J Neurophysiol* 1991;65:1392-1401.
- [9] **Minoshima** S, Koeppe RA, Fessler JA, et al. Integrated and automated data analysis method for neuronal activation studies using ¹⁵O-water PET. In: Uemura K, Lassen N, Jones T, Kanno I, eds. *Quantification of brain function*. New York: Elsevier, 1993:409-15.
- [10] **Friston** KJ. Statistical parametric mapping. In: Thatcher RW, Hallet M, Zeffiro T, John ER, eds. *Functional neuroimaging*. San Diego: Academic Press, 1994: 79-93.
- [11] **Pietrzyk** U, Herholz K, Fink G, et al. An interactive technique for three-dimensional image registration: Validation for PET, SPECT, MRI and CT brain studies. *J Nucl Med* 1994;35:2011-8.
- [12] **Dettmers** C, K.M. S, Lemon RN, Warburton E, Frackowiak RSJ. Reorganization of the executive motor system after stroke. *J Cereb Blood Flow Metab* 1995;15(Suppl 1):S690.
- [13] **Sur** M, Pallas SL, Roe AW. Cross-modal plasticity in cortical development: Differentiation and specification of sensory neocortex. *Trends Neurosci* 1990;13:227-33.
- [14] **Sadato** N, Pascual-Leone A, Grafman J, et al. Activation of the primary visual cortex by Braille reading in blind subjects. *Nature* 1996;380:526-8.
- [15] **Kujala** T, Huotilainen M, Sinkkonen J, et al. Visual cortex activation in blind humans during sound discrimination. *Neurosci Lett* 1995;183:143-6.