

Pediatric Wegener's Granulomatosis Complicated by Central Nervous System Vasculitis

Emily von Scheven, MD*,
Christine Lee, MD[†], and
Bruce O. Berg, MD[‡]

An unusual case of central nervous system vasculitis in pediatric Wegener's granulomatosis, a rare disorder that infrequently presents during childhood, is reported. A 13-year-old girl with Wegener's granulomatosis, whose initial presentation resembled Henoch-Schönlein purpura, developed recurring seizures. MRI of the brain demonstrated multiple areas of increased signal in the occipital, parietal, and frontal lobes, consistent with central nervous system vasculitis. Although both peripheral and cranial neuropathies have been reported in patients with Wegener's granulomatosis, cerebral vasculitis is unusual, particularly in childhood. This case emphasizes the need to consider Wegener's granulomatosis in the differential diagnosis of both unexplained seizures and central nervous system vasculitis in children with systemic illness. © 1998 by Elsevier Science Inc. All rights reserved.

von Scheven E, Lee C, Berg BO. Pediatric Wegener's granulomatosis complicated by central nervous system vasculitis. *Pediatr Neurol* 1998;19:317-319.

Introduction

Wegener's granulomatosis (WG) is a rare multisystem disease characterized by necrotizing granulomatous lesions. Although initially reported in 1931 by Heinz Klinger [1], Friedrich Wegener [2] described the charac-

teristic triad of necrotizing granulomatous lesions involving the upper and lower respiratory tracts, necrotizing inflammation of arteries and veins, and focal necrotizing glomerulonephritis. The typical clinical presentation of WG includes upper airway disease (cough, rhinitis, nasal congestion, epistaxis, and sinusitis) in addition to fever, weight loss, arthralgia, and malaise. Fifteen percent of cases are limited to the upper airway [3]; the remainder demonstrate more widespread disease involving the lungs (most commonly), skin, central and peripheral nervous systems, eyes, ears, joints, heart, meninges, or gastrointestinal tract. Renal manifestations, including hypertension, nephritis, and renal failure, result from focal and segmental glomerulonephritis, necrotizing proliferative glomerulonephritis, and crescentic glomerulonephritis [3,4].

WG is slightly more common among males than females. The peak incidence occurs in the fourth and fifth decades (mean = 41 years). By contrast, WG is rarely observed in patients under the age of 19 years, with a mean pediatric age at onset of 15 years [5]. Although the etiology is not well established, the natural history of WG has been well characterized [4]. Previously WG was a uniformly fatal disease; however, today prolonged survival and remission can be anticipated with early administration of cyclophosphamide and corticosteroids [3]. In addition, recent studies have demonstrated a role in some cases for low-dose methotrexate to avoid potential long-term toxicities of cyclophosphamide, such as infertility, secondary malignancy, and bladder complications [6,7].

Case Report

A 13-year-old girl was diagnosed with Henoch-Schönlein purpura after presenting with intermittent fever, purpuric rash involving the lower legs, bloody diarrhea, a 10-lb weight loss, hematuria, and an elevated serum creatinine (1.8 mg/dL). Her past medical history was noteworthy only for recurrent otitis media requiring myringotomy tube placement, tonsillectomy, and adenoidectomy 1 month prior. Despite treatment with prednisone (40-60 mg/day), the serum creatinine rose to 2.0 mg/dL and urinary sediment remained active (3+ protein, 3+ blood, 3 leukocytes per high power field (hpf), 100 erythrocytes/hpf, and 2 hyaline casts/hpf). Renal biopsy revealed progressive glomerulonephritis involving 80-90% of the glomeruli, with crescents and fibrinoid necrosis (Fig 1). IgA staining was negative. At this time the patient was transferred to the authors' hospital for further diagnostic evaluation and management.

On admission, her physical examination was significant for hyperpigmented macules overlying the extensor surfaces of both elbows, scarring of the left tympanic membrane, a right myringotomy tube, tenderness over the left maxillary sinus, oral mucosal ulcers, lower extremity pitting

From the Departments of *Pediatric Rheumatology; [†]Obstetrics and Gynecology; and [‡]Child Neurology; University of California, San Francisco; San Francisco, California.

Communications should be addressed to:
Dr. von Scheven; Department of Pediatric Rheumatology; University of California, San Francisco; Box 0107; 505 Parnassus Street; San Francisco, CA 94143.

Received February 23, 1998; accepted May 8, 1998.

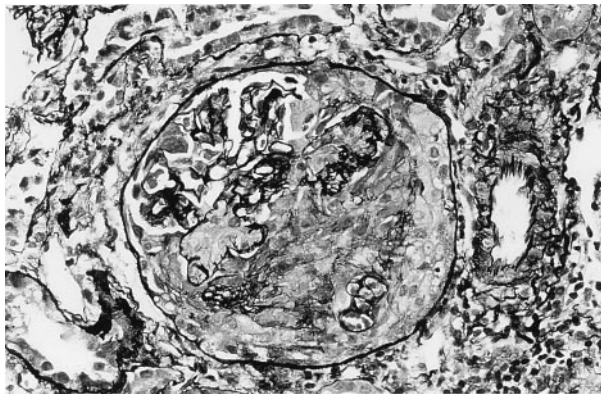


Figure 1. Light micrograph of kidney demonstrating crescentic glomerulonephritis characteristic of WG. Silver staining of glomerulus reveals a large crescent, disrupted basement membrane, and fibrinoid necrosis (periodic acid-Schiff-silver stain, original magnification $\times 230$).

edema, and bilateral ankle and knee synovitis. Laboratory studies were significant for an erythrocyte sedimentation rate of 90 mm/hr, leukocyte count $9.6 \times 10^9/L$, hemoglobin 6.5 g/dL, platelet count $503 \times 10^9/L$, blood urea nitrogen 59 mg/dL, creatinine 1.8 mg/dL, albumin 2.6 g/dL, normal serum complement levels, and a positive antineutrophil cytoplasmic antibody with cytoplasmic staining pattern, consistent with the diagnosis of WG. She was treated with high-dose steroids and begun on daily cyclophosphamide.

One hour after administration of oral cyclophosphamide (75 mg) and intravenous methylprednisolone (800 mg) the patient developed an urticarial rash and nasolaryngeal pruritus. She subsequently developed confusion, vomiting, head jerking, and upward deviation of both eyes, which progressed to a left partial motor seizure that became generalized. Her neurologic examination revealed dilated but reactive pupils, mild finger to nose dysmetria, bilateral brisk reflexes with extensor plantar responses, and unsustained ankle clonus. Possible explanations for the seizure activity included meningitis, stroke, or cerebritis. Hypercoagulable evaluation (dilute Russell viper venom time, anticardiolipin antibodies, rapid plasma reagin, free protein S antigen, protein C function, antithrombin III level, and factor V Leiden mutation), cerebrospinal fluid analysis, and echocardiogram were all normal. Noncontrast computed tomography of the brain revealed multiple focal areas of low attenuation at the gray-white junction. Magnetic resonance imaging revealed multiple areas of increased T_2 -weighted signal involving the occipital, parietal, and frontal lobes (Fig 2).

A second partial motor seizure occurred within 12 hours and was managed with immediate administration of lorazepam and maintenance phenobarbital. She remains seizure-free after 1 year 6 months with therapeutic serum levels of phenobarbital. The WG was initially managed with prednisone and daily cyclophosphamide with gradual improvement of clinical symptoms and laboratory parameters. After 4 months, persistent leukopenia prompted a switch from daily cyclophosphamide to weekly methotrexate.

Discussion

WG is an uncommon disease that rarely presents during childhood. Initial clinical presentations are variable and thus the diagnosis is often not considered. Similar to other cases reported in the literature [8], the initial presentation of this patient resembled HSP.

Neurologic manifestations are frequently observed in adult patients with WG (54%) as evident in a review of 104 patients by Drachman [9]. Most of these neurologic complications are secondary to peripheral neuropathy,

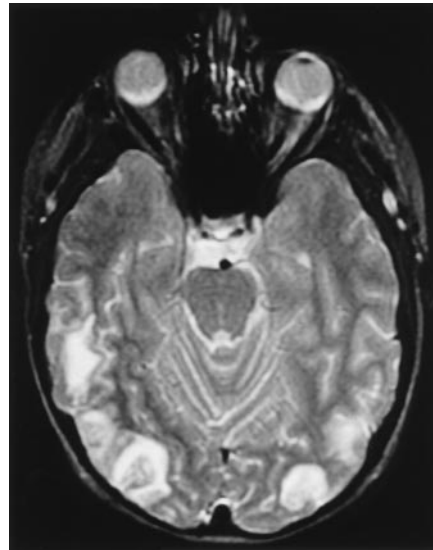


Figure 2. Brain magnetic resonance imaging demonstrating multiple white matter lesions with T_2 -weighted signal involving the frontal, parietal, and occipital regions. The persistence of these lesions on follow-up T_1 -weighted scans is consistent with a vasculitic process.

cranial neuropathy, external ophthalmoplegia, or hearing loss [10]. By contrast, cerebritis is a rare manifestation of WG, as are seizure, stroke, Horner syndrome, meningitis, myelopathy, and myopathy [10-13]. Peripheral neuropathy is the single most common neurologic complication (21%), occurring either as a mononeuritis multiplex (13%) or polyneuritis (8%) [9]. Spastic paraparesis, temporal arteritis, and papilledema may also occur but are unusual [11].

Nervous system involvement by WG is reported less frequently in children than adults [14]; however, the few published clinical reports provide insufficient data from which to draw reliable and meaningful conclusions. Only three of 17 children in one series [14] had neurologic abnormalities reported; two children demonstrated peripheral neuropathies and one child a cranial nerve VII palsy that resolved with treatment within 2 weeks. Another report of 23 pediatric patients described six patients with neurologic complications, including two patients with peripheral neuropathies, two patients with multiple cranial nerve palsies, and two patients with a seizure disorder but with no other evidence of central nervous system (CNS) involvement [5].

Clinical descriptions of cerebral involvement in children with WG are scanty. In a small report [8] of four cases, one patient was diagnosed with a transient cerebritis; however, there was no description of the neurologic examination or neuroimaging studies. One clinicopathologic case [15] describes a 12-year-old patient with vasculitic lesions in the brain consistent with WG on post-mortem examination, but no clinical signs of CNS involvement were evident, except for coma 48 hours before death.

The following three mechanisms have been considered

for the nervous system manifestations of WG: direct contiguous invasion by nasal or paranasal granulomas; remote granulomas (e.g., affecting the skull, brain, meninges, or cranial nerves); and CNS vasculitis [9].

The authors present a patient with magnetic resonance imaging brain scan findings consistent with cerebral vasculitis. Her initial presentation included symptoms suggestive of HSP, a common confounding diagnosis in the variable presentation of childhood WG [8]. Delays in the diagnosis of WG resulting from its rarity (especially in children), insidious progression, and diverse clinical presentations can now be avoided by testing for antineutrophil cytoplasmic antibodies. In active WG the test for antineutrophil cytoplasmic antibodies with a cytoplasmic staining pattern has a specificity greater than 90-95% [5,7] and a sensitivity as great as 88% [5]. However, definitive diagnosis depends on the pathologic demonstration of necrotizing granulomatous vasculitis, typically involving the small vessels [3]. Biopsy of the nasal mucosa and open-lung biopsy have traditionally provided the highest yield for granuloma [4]. Renal histopathologic examination often demonstrates vasculitis but rarely reveals granuloma [4].

Although WG is a multisystem disease primarily affecting the respiratory tract and kidneys, rare neurologic complications can be an important feature of the disease. Nervous system involvement in WG occurs more commonly in adults than in children and affects the peripheral nervous system more often than the CNS. The authors' case of a female pediatric patient with WG is particularly noteworthy in that she presented with new onset unexplained seizure activity presumably secondary to cerebral vasculitis, a rare complication even in adults with WG. WG must be considered in the differential diagnosis of both unexplained seizure activity and cerebral vasculitis in children with systemic illness, particularly now that more

effective therapy offering dramatic clinical improvement is available.

References

- [1] **Klinger H.** Grenzformen der periarteritis nodosa. *Frankf Ztschr Pathol* 1931;42:455-80.
- [2] **Wegener F.** Über generalisierte, septische Gefässerkrankungen. *Verh Dtsch Ges Pathol* 1936;29:202-10.
- [3] **Fauci AS, Haynes BF, Katz P, Wolff SM.** Wegener's granulomatosis: Prospective clinical and therapeutic experience with 85 patients for 21 years. *Ann Intern Med* 1983;98:76-85.
- [4] **Burlacoff SG, Wong FSH.** Wegener's granulomatosis, the great masquerade: A clinical presentation and literature review. *J Otolaryngol* 1993;22:94-105.
- [5] **Rottem M, Fauci AS, Hallahan CW, et al.** Wegener's granulomatosis in children and adolescents: Clinical presentation and outcome. *J Pediatr* 1993;122:26-31.
- [6] **Gottlieb BS, Miller LC, Ilowite NT.** Methotrexate treatment of Wegener's granulomatosis in children. *J Pediatr* 1996;129:604-7.
- [7] **Hoffman GS, Kerr GS, Leavitt RY, et al.** Wegener's granulomatosis: An analysis of 158 patients. *Ann Intern Med* 1992;116:488-98.
- [8] **Hall SL, Miller LC, Duggan E, Mauer SM, Beatty EC, Hellerstein S.** Wegener's granulomatosis in pediatric patients. *J Pediatr* 1985;106:739-44.
- [9] **Drachman DA.** Neurological complications of Wegener's granulomatosis. *Arch Neurol* 1963;8:145-55.
- [10] **Nishino H, Rubino FA, Parisi JE.** The spectrum of neurologic involvement in Wegener's granulomatosis. *Neurology* 1993;43:1334-7.
- [11] **Nishino H, Rubino FA, De Remee RA, Swanson JW, Parisi JE.** Neurological involvement in Wegener's granulomatosis: An analysis of 324 consecutive patients at the Mayo Clinic. *Ann Neurol* 1993;33:4-9.
- [12] **Miller KS, Miller JM.** Wegener's granulomatosis presenting as primary seizure disorder with brain lesions demonstrated by magnetic resonance imaging. *Chest* 1993;103:316-8.
- [13] **Weinberger LM, Cohen ML, Remler BF, Naheedy MH, Leigh RJ.** Intracranial Wegener's granulomatosis. *Neurology* 1993;43:1831-4.
- [14] **Orlowski JP, Clough JD, Dymont PG.** Wegener's granulomatosis in the pediatric age group. *Pediatrics* 1978;61:83-90.
- [15] **Castleman B, Towne VW.** Case records of the Massachusetts General Hospital. *N Engl J Med* 1951;245:978-85.