

CASE REPORT

G. Massenkeil · E. Späth-Schwalbe · B. Flath
S. Gottschalk · R. Lehmann · R. Arnold

Transient tetraparesis after intrathecal and high-dose systemic methotrexate

Received: March 13, 1998 / Accepted: July 29, 1998

Abstract Aggressive polychemotherapy, intrathecal cytostatic prophylaxis and cranial irradiation have contributed to the remarkable improvement in the prognosis of acute lymphoblastic leukemia (ALL) and subtypes of high-grade non-Hodgkin's lymphoma (NHL) and the reduction of central nervous system (CNS) relapses. Early and late neurologic changes have been observed after different CNS-directed therapies. We report on the rare event of an acute tetraparesis after methotrexate (MTX) without other CNS-directed therapy. A young female with a diffuse large B-cell lymphoma developed signs of meningeal irritation a few hours after intrathecal prophylaxis with MTX, cytosine-arabino- side and dexamethasone. She recovered quickly. Ten days after her last course of systemic chemotherapy including high dose MTX she was admitted with a tetraparesis and motoric aphasia. A computer assisted tomography (CT) scan was normal. On magnetic resonance imaging (MRI) hyperintense white matter lesions were visible in the periventricular white matter. Initially, the radiologic signs were progressive while the patient's clinical condition improved. MRI controls after complete neurologic normalization revealed delayed partial regression of the white matter abnormalities. The patient has now been free of neurologic symptoms for 16 months. This case report demonstrates acute and subacute neurotoxic effects of MTX in the same patient and illustrates that radiologic CNS changes can persist irrespective of the disappearance of clinical symptoms.

Key words High-grade non-Hodgkin's lymphoma · Methotrexate · Leukoencephalopathy · Neurotoxicity · Magnetic resonance imaging

Introduction

Systemic and intrathecal methotrexate (MTX) therapy have been used for many years in acute lymphoblastic leukemia (ALL) and subtypes of high-grade non-Hodgkin's lymphoma (NHL) (e.g., Burkitt's lymphoma). Neurologic symptoms have been observed after systemic and intrathecal MTX chemotherapy as well as after CNS irradiation [1–3].

Short- and long-term sequelae of intrathecal MTX administration and intermediate and high dose systemic MTX therapy have been described and include: (a) acute reactions which appear within 12 h following MTX administration and consisting of transient meningism, headache, vomiting, back pain; (b) subacute reactions occurring days to a few weeks after therapy with paraparesis, cranial nerve palsies and cerebellar abnormalities. Acute and subacute changes are mostly encountered after repeated administrations of MTX and are reversible in the majority of cases; (c) late effects with development of a chronic, frequently irreversible, form of leukoencephalopathy (LEP), which can be observed months to years after therapy with neuropsychological changes ranging from mild personality disorders to progressive dementia [4, 5].

The combination of different CNS-directed therapy modalities seems to increase the risk of neurotoxic changes [5]. Computer assisted tomography (CT) and, more recently, magnetic resonance imaging (MRI) have been used to assess CNS changes after MTX-containing chemotherapy.

We report on a young female with a high grade NHL who experienced different features of MTX neurotoxicity, including transient tetraparesis. The acute onset of a completely reversible tetraparesis after MTX without further CNS-directed therapies is a rare event.

G. Massenkeil (✉) · E. Späth-Schwalbe · B. Flath · R. Arnold
Department of Internal Medicine, Clinic of Hematology and Oncology, University Hospital Charité, Humboldt University, Schumannstrasse 20/21, D-10117 Berlin, Germany
Tel.: 0049-30-2802-4438, Fax: 0049-30-2802-1486

S. Gottschalk · R. Lehmann
Institute of Radiology, University Hospital Charité, Humboldt University, Berlin, Germany

R. Lehmann
Division of Neuroradiology, University Hospital Charité, Humboldt University, Berlin, Germany

We discuss the discrepancy between clinical symptoms and neuroradiologic results.

Case report

A 17-year-old female was admitted with severe dyspnea due to a bulky mediastinal large cell, B cell lymphoma (stage IIA). She was treated according to the German B-ALL protocol, consisting of alternating courses of polychemotherapy, including systemic therapy with MTX (3 g/m^2 i.v., day 1, each course) and intrathecal triple prophylaxis with Ara-C (40 mg), dexamethasone (4 mg), and MTX (15 mg, days 1 and 5, each course) [6]. She had had regular MTX excretion after systemic high dose MTX, and had responded to six cycles of chemotherapy with an almost complete reduction of the mediastinal bulk. In total she had received 31 g MTX systemically and 165 mg MTX intrathecally.

A few hours after intrathecal triple prophylaxis, at the beginning of the last cycle, she complained of local pain at the site of the lumbar puncture, irradiating pain into her legs, and nausea. Liquor analysis was normal and she was free of neurologic symptoms after 4 days.

Seven days after the last course of chemotherapy and 10 days after the last MTX infusion she suddenly developed a tetraparesis. On admission to the hospital the patient was awake, but unable to speak. She had a right-sided central facial paresis and a bilateral loss of motoric strength. She had no fever and no signs of meningeal irritation. Liquor analysis and a cranial CT were normal, apart from slightly enlarged ventricles excluding cerebral bleeding (not shown). T2-weighted cranial MRI scans showed large bilateral hyperintense areas in the periventricular white matter affecting the pyramidal tract predominantly on the left side with no contrast enhancement. No pathologic changes could be detected in the insular cortex or the temporo-parietal cortex including the Broca and Wernicke areas (Figs. 1, 2). Six days later the intracerebral lesions had extended to the parietal white matter on MRI (not shown). The patient's condition had improved spontaneously at that time. Her speech normalized slowly and the tetraparesis disappeared. Complete neurologic recovery was achieved after another week. An MRI done 1 month later demonstrated partial regression of the intracerebral lesions. Nine months later, further regression of the hyperintense areas was observed in a control MRI, although the lesions were still visible (Fig. 3).

The patient has been free of neurologic symptoms for 16 months. After consolidating radiation therapy to the mediastinum, she has been in complete remission for 13 months.

Discussion

Various neuropsychological side effects have been ascribed to intrathecal and systemic MTX. Most of the patients had received large doses of MTX and had been treated for several months before the onset of neurologic symptoms [2, 3, 7], although the early onset of lethal neurologic side effects after a single intrathecal and systemic MTX dose has also been reported [8]. Most of these toxic effects were observed in children or adolescents [1, 2, 7]. This is probably due to the fact that CNS development is not finished until the end of the second decade, making the CNS more vulnerable to toxic agents during childhood and adolescence.

We observed the almost simultaneous onset of acute and subacute neurotoxic effects in our patient. Acute neurotoxicity occurs in approximately 10% of patients,

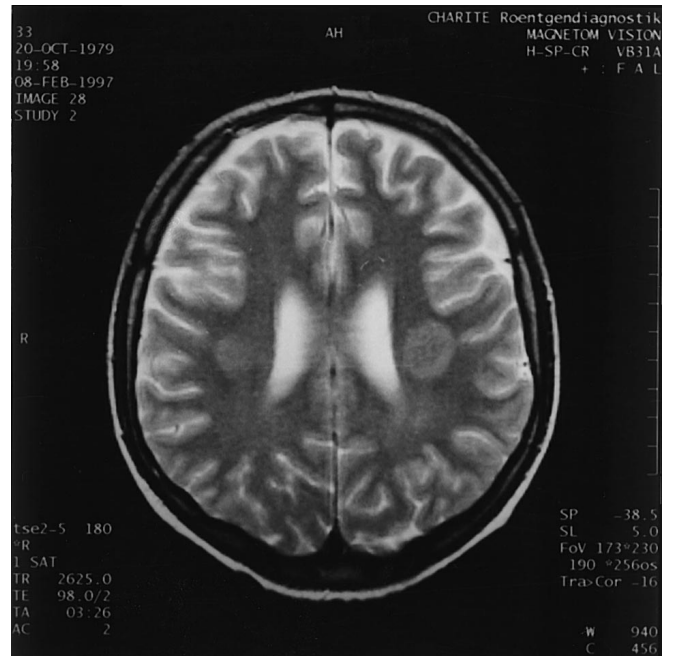


Fig. 1. T2-weighted MRI scan of the brain (TR 2625/TE 98) Hyperintense lesions in the periventricular white matter affecting the pyramidal tract. No mass effect

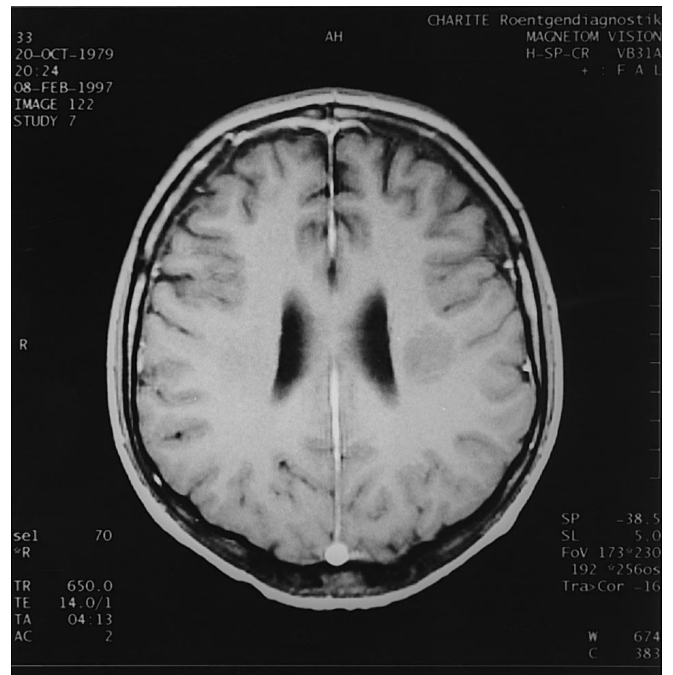


Fig. 2. T1-weighted MRI scan performed the same day (TR 650/TE 14) demonstrated no contrast enhancement

is presumably caused by a chemical arachnoiditis and seems to correlate with elevated MTX concentrations in cerebrospinal fluid [5].

Subacute neurotoxicity has been reported after repeated intrathecal as well as after systemic high dose

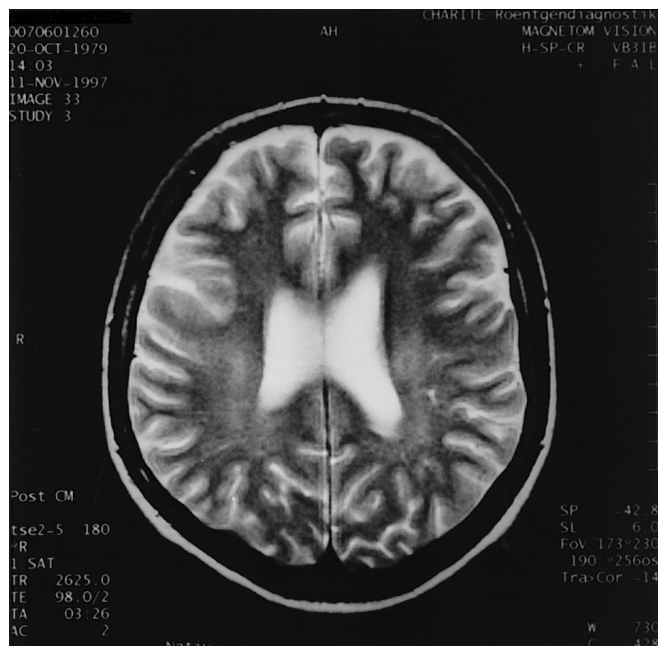


Fig. 3. T2-weighted MRI after 9 months (TR 2625/TE 98). Partial regression of the periventricular hyperintense white matter lesions. Again no contrast enhancement was observed in T1-weighted images (not shown)

MTX in up to 20% of patients [2, 9, 10]. The neurologic symptoms can present as a “stroke-like” event with seizures or sudden unilateral paresthesia, weakness and disorientation 8–14 days after intrathecal or systemic MTX therapy [2, 5], corresponding to the time interval between the last MTX administration and the onset of symptoms in our patient. Complete neurologic recovery is usually achieved within a few days. However, a tetraparesis after MTX has only been published in three cases [3, 4, 11]. These patients had either slowly developed a neuropsychologic deficit starting several months before the tetraparesis or had received cranial irradiation in addition to MTX. They did not recover completely [3, 4]. Only one patient had acute onset of a tetraparesis after MTX alone with rapid complete recovery [11].

Subacute and chronic neurotoxic changes basically seem to present identically on MRI as white matter lesions [12]. Diagnostically, MRI is superior to CT in the detection of these white matter changes [13]. LEP presents in T2-weighted images as hyperintense areas (Fig. 1). Lymphoma and LEP can be distinguished by the behavior of contrast medium, which is enhanced in lymphoma, but not in LEP (Fig. 2) [1].

Neuroradiologic analyses with MRI after systemic and intrathecal MTX showed that white matter lesions can develop in 20% to more than 50% of patients. Many of these patients, however, were asymptomatic at the time of neuroradiologic evaluation [1, 7, 12, 14, 15]. In symptomatic patients MRI can reveal the typical white matter lesions as well as normal brain structures [1, 12, 10]. No convincing correlation has been found

between radiologic changes and clinical CNS dysfunctions [7, 14, 16].

The course of the white matter lesions varies after neurologic recovery. Persisting lesions as well as partial or complete normalization have been observed, also with no correlation to neuropsychologic deficits [1, 2, 16]. The prognostic significance of the persisting white matter lesions detected in our patient as well as in cases of incomplete recovery after subacute neurotoxicity with respect to the development of chronic clinical leukoencephalopathy is not established.

The reason for the rare occurrence of tetraparesis after MTX alone is not clear. We speculate that it has happened more frequently and was only missed by the time lag between the onset of symptoms and neurologic evaluation, in view of the frequent rapid recovery of the neurologic symptoms.

References

- Asato R, Akiyama Y, Ito M, Kubota M, Okumura R, Miki Y, Konishi J, Mikawa H (1992) Nuclear magnetic resonance abnormalities of the cerebral white matter in children with acute lymphoblastic leukemia and malignant lymphoma during and after central nervous system prophylactic treatment with intrathecal methotrexate. *Cancer* 70:1997–2004
- Winick NJ, Bowman WP, Kamen BA, Roach ES, Rollins N, Jacaruso D, Buchanan GR (1992) Unexpected acute neurologic toxicity in the treatment of children with acute lymphoblastic leukemia. *J Natl Cancer Inst* 84:252–256
- Watterson J, Toogood I, Nieder M, Morse M, Friedrich S, Lee Y, Moertel C, Priest JR (1994) Excessive spinal cord toxicity from intensive central nervous system-directed therapies. *Cancer* 74:3034–3041
- Allen JC, Rosen G, Metha BM, and Horton B (1980) Leukoencephalopathy following high-dose iv methotrexate chemotherapy with leucovorin rescue. *Cancer Treat Rep* 64:1261–1273
- Bleyer WA (1981) Neurologic sequelae of methotrexate and ionizing radiation: a new classification. *Cancer Treat Rep* 65:89–98
- Pees HW, Radtke H, Schwamborn H, Graf N (1992) The BFM protocol for HIV-negative Burkitt's lymphomas and L3 ALL in adult patients: a high chance for cure. *Ann Hematol* 65:201–205
- Matsumoto K, Takahashi S, Sato A, Imaizumi M, Higano S, Sakamoto K, Asakawa H, Tada K (1995) Leukoencephalopathy in childhood hematopoietic neoplasm caused by moderate-dose methotrexate and prophylactic cranial radiotherapy-an MR analysis. *Int J Radiat Oncol Biol Phys* 32:913–918
- Geissler RG, Bergmann L, Hacker H, Knupp B, Walker B, Hölzer D (1997) Severe central nervous adverse effect of intrathecal chemotherapy in a 16-yr-old patient with Burkitt's type lymphoma. *Eur J Haematol* 58:286–288
- Walker RW, Allen JC, Rosen G, Caparros B (1986) Transient cerebral dysfunction secondary to high-dose methotrexate. *J Clin Oncol* 4:1845–50
- Yim YS, Mahoney DH, Oshman DG (1991) Hemiparesis and ischemic changes of the white matter after intrathecal therapy for children with acute lymphocytic leukemia. *Cancer* 67:2058–2061
- Martino RL, Benson AB, Merritt JA, Brown JL, Lesser JR (1984) Transient neurologic dysfunction following moderate-dose methotrexate for undifferentiated lymphoma. *Cancer* 54:2003–2005

12. Biti GP, Magrini SM, Villari N, Caramella D, Guazzelli G, Rosi A, Lippi A (1989) Brain damage after treatment for acute lymphoblastic leukemia. *Acta Oncologica* 28:253-256
13. Packer RJ, Zimmerman RA, Bilaniuk LT(1986) Magnetic resonance imaging in the evaluation of treatment-related central nervous system damage. *Cancer* 58:635-640
14. Peylan-Ramu N, Poplack DG, Pizzo PA, Adornato BT, Di Chiro G (1978) Abnormal CT scans of the brain in asymptomatic children with acute lymphocytic leukemia after prophylactic treatment of the central nervous system with radiation and intrathecal chemotherapy. *N Engl J Med* 298:815-818
15. Lien HH, Blomlie V, Saeter G, Solheim O, Fossa SD (1991) Osteogenic sarcoma: MR signal abnormalities of the brain in asymptomatic patients treated with high-dose methotrexate. *Radiology* 179:547-550
16. Wilson DA, Nitschke R, Bowman ME, Chaffin MJ, Sexauer CL, Prince JR (1991) Transient white matter changes on MR images in children undergoing chemotherapy for acute lymphocytic leukemia. Correlation with neuropsychologic deficiencies. *Radiology* 180:205-209