

Case Records of the Massachusetts General Hospital



Weekly Clinicopathological Exercises

FOUNDED BY RICHARD C. CABOT

ROBERT E. SCULLY, M.D., *Editor*  
 EUGENE J. MARK, M.D., *Associate Editor*  
 WILLIAM F. MCNEELY, M.D., *Associate Editor*  
 SALLY H. EBELING, *Assistant Editor*

Case 40-1998

PRESENTATION OF CASE

A 49-year-old right-handed woman was admitted to the hospital because of a hemorrhagic stroke and mutism.

The patient had been well until two weeks earlier, when she began to have menorrhagia and orthostatic weakness. One day before admission, she entered

another hospital, where she was found to have uterine leiomyomas. Laboratory studies were performed (Tables 1 and 2). Two units of packed red cells were transfused, and dilation with curettage was performed. On the next day, she felt better until midday, when she suddenly had a severe headache, followed by an inability to speak, although she could understand simple spoken commands. A right facial droop was noted. A lumbar puncture was performed (Table 3). She was transferred to this hospital.

The patient had had hypertension for one year. During the four months before admission, she had had angina pectoris on walking, which was relieved by sublingual nitroglycerin. A treadmill stress test was negative. She also took diltiazem.

The temperature was 36.8°C, the pulse was 81, and the respirations were 22. The blood pressure was 150/80 mm Hg.

On examination, the patient was pale and tense. A few petechial lesions were present on the chest, and multiple splinter hemorrhages were seen. The carotid pulses were normal, without bruits. The lungs were normal.

On neurologic examination, the patient was alert

TABLE 1. RESULTS OF HEMATOLOGIC STUDIES.

VARIABLE	ONE DAY BEFORE ADMISSION	ON ADMISSION	EARLY ON SECOND HOSPITAL DAY	LATE ON SECOND HOSPITAL DAY
Hematocrit (%)	16	23.1	17.5	30.1
Mean corpuscular volume ( $\mu\text{m}^3$ )		83		
Reticulocyte count (%)				6.1
Microscopical features of red cells	Schistocytes	Many microcytes and schistocytes; a few oval red cells; poikilocytosis (+++)		
Erythrocyte sedimentation rate (mm/hr)				46
D-Dimer test ( $\mu\text{g}/\text{ml}$ )				Positive (4-8)*
Fibrinogen				Normal
White-cell count (per $\text{mm}^3$ )		11,800	6,900	4,600
Differential count (%)				
Neutrophils			88	85
Band forms			0	3
Lymphocytes			10	12
Monocytes			1	
Eosinophils			1	
Platelet count (per $\text{mm}^3$ )	36,000	32,000	24,000	18,000
Prothrombin time (sec)		Normal	12.9†	
Partial-thromboplastin time (sec)		Normal	28.5	

\*The normal value is <0.5.

†The control value was 10.3 seconds.

**TABLE 2. BLOOD CHEMICAL VALUES.\***

VARIABLE	ONE DAY BEFORE ADMISSION	ON ADMISSION	EARLY ON SECOND HOSPITAL DAY
Urea nitrogen (mg/dl)	16	Normal	Normal
Creatinine (mg/dl)	1.3	Normal	Normal
Uric acid		Normal	
Total protein (g/dl)		6.6	5.2
Albumin		2.3	1.9
Globulin		4.3	3.3
Calcium (mg/dl)		7.6	6.2
Phosphorus (mg/dl)			2.3
Glucose (mg/dl)		137	144
Bilirubin (mg/dl)			
Total		1.5	
Conjugated		0.5	
Sodium (mmol/liter)		138	142
Potassium (mmol/liter)		3	2.4
Chloride (mmol/liter)		103	110
Carbon dioxide (mmol/liter)		27.7	22.8
Magnesium (mmol/liter)		0.55	0.50
Aspartate aminotransferase (U/liter)		59	
Alkaline phosphatase (U/liter)		122	
Lactate dehydrogenase (U/liter)	782	1036	761
Creatine kinase (U/liter)		483	299
Creatine kinase isoenzymes (U/liter)†		11.2	7.9
Creatine kinase isoenzyme index		Normal	Normal
Amylase		Normal	Normal

\*To convert the value for urea nitrogen to millimoles per liter, multiply by 0.357. To convert the value for creatinine to micromoles per liter, multiply by 88.4. To convert the values for calcium to millimoles per liter, multiply by 0.250. To convert the value for phosphorus to millimoles per liter, multiply by 0.3229. To convert the values for glucose to millimoles per liter, multiply by 0.05551. To convert the values for total and conjugated bilirubin to micromoles per liter, multiply by 17.1. To convert the values for magnesium to milliequivalents per liter, divide by 0.5.

†The normal value is 0.5 U per liter.

**TABLE 3. FINDINGS ON LUMBAR PUNCTURE.**

VARIABLE	FINDING
Appearance of fluid	Pink–orange
Initial pressure (mm of water)	520
Red-cell count (per mm <sup>3</sup> )	7000 (first and fourth tubes)
White-cell count (per mm <sup>3</sup> )	18 (fourth tube)
Xanthochromia	1+
Glucose (mg/dl)*	61
Total protein (mg/dl)	74

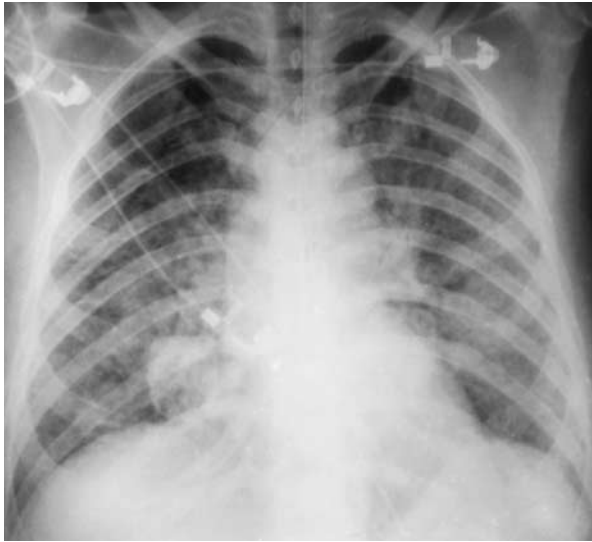
\*To convert the value for glucose to millimoles per liter, multiply by 0.05551.

and followed verbal and written commands. She spoke a few single words, wrote her name, and recalled two of three objects in five minutes. She performed calculations and named a pen and a watch accurately. Visual acuity was 20/200 bilaterally without eyeglasses. Flame-shaped hemorrhages and papilledema were noted bilaterally. Right central facial weakness was present, and the tongue deviated to the right. Motor power and sensation were intact. The gait was short-stepped; Romberg's test was negative. There was meningismus (+). Dysmetria was noted on finger-to-nose testing. The deep-tendon reflexes were ++ and symmetric. Bilateral Babinski signs were present. There was twitching of the right side of the lip for approximately one minute.

The urine was positive (++) for protein; the sediment contained 0 to 5 hyaline casts per low-power field and 50 to 100 red cells and 5 to 10 white cells per high-power field. Laboratory studies were performed (Tables 1 and 2). An electrocardiogram showed a normal rhythm at a rate of 86, with a prolonged QT interval and low or flattened T waves in leads I and aVL; low biphasic T waves in leads II, V<sub>1</sub>, and V<sub>2</sub>; and inverted T waves in leads III, aVF, and V<sub>3</sub> through V<sub>6</sub>. A computed tomographic (CT) scan of the head, obtained without the administration of contrast material, revealed a focus of low attenuation in the left frontal lobe, which was consistent with the presence of an infarct. There was a focus of high attenuation consistent with the presence of a tiny hemorrhage in the right parietal region. A focus of low attenuation in the right cerebellar cortex was also consistent with the presence of an infarct. The cranial bones and paranasal sinuses appeared normal. The findings on chest radiography were normal. Tests for antineutrophil cytoplasmic antibodies and anti-glomerular-basement-membrane antibodies were negative.

A diagnosis of thrombotic thrombocytopenic purpura was made. Three specimens of blood and one specimen of cerebrospinal fluid were sent for culture. Methylprednisolone (40 mg) was administered intravenously. In the early hours of the second hospital day, the temperature was 36.2°C, and the blood pressure was 130/70 mm Hg. Laboratory studies were performed (Tables 1 and 2).

Potassium chloride and a bolus of normal saline (600 ml) were given intravenously, followed by plasmapheresis with volume replacement with fresh-frozen plasma. About an hour after the beginning of a transfusion of packed red cells, the blood pressure fell to 80/50 mm Hg; the patient reported chills and acute dyspnea developed. Examination showed diffuse, bilateral crackles without wheezes. Plasmapheresis and transfusion were interrupted. Oxygen was administered by nasal prongs, but the oxygen saturation declined progressively from 100



**Figure 1.** Anteroposterior Chest Radiograph Obtained with Portable Equipment, Showing Diffuse, Bilateral Air-Space Consolidation Consistent with the Presence of Pulmonary Edema.

percent to 75 percent during the next 45 minutes. At that point, while the patient was breathing oxygen at a rate of 4 liters per minute, a specimen of arterial blood was obtained. The partial pressure of oxygen was 49 mm Hg, the partial pressure of carbon dioxide was 35 mm Hg, and the pH was 7.48. The hematocrit was 21 percent. The trachea was intubated, and while the patient was undergoing mechanical ventilation with 100 percent oxygen, the partial pressure of oxygen was 254 mm Hg, the partial pressure of carbon dioxide was 37 mm Hg, and the pH was 7.39. A phenylephrine drip was instituted; no diuretic was given. An electrocardiogram showed a prolonged QT interval, with minor changes in the T-wave abnormalities. A radiograph of the chest (Fig. 1) revealed diffuse, bilateral air-space consolidation, a finding consistent with the presence of pulmonary edema. An urgent cardiac ultrasonographic study showed no abnormalities.

The patient was transferred to an intensive care unit. Her breathing improved promptly after intubation, and hemodynamic stability returned. Chest radiography was performed 2 hours and 20 minutes after the previous examination; the pulmonary vasculature was indistinct because of poor penetration. Urgent evaluation by the blood bank revealed no evidence of a reaction to the transfusion, and the remainder of the fresh-frozen plasma was transfused without incident. Plasmapheresis was resumed after an interruption of two hours and was concluded after another two hours; 5990 ml of fluid was administered, and 4193 ml was withdrawn. The temperature rose to 37.9°C and subsided to 37.2°C three

hours after the plasmapheresis was concluded. Hematologic studies were performed (Table 1).

A chest radiograph obtained 23 hours after the most recent examination showed marked improvement in the pulmonary edema. The trachea was extubated within 48 hours after admission without incident. During the next two days, the creatine kinase level remained normal, and repeated electrocardiograms revealed gradual improvement in the T-wave abnormalities. The patient no longer had dyspnea, but she remained mute. Daily plasmapheresis was performed without incident. The platelet count rose progressively to 173,000 per cubic millimeter by the fourth hospital day. All culture specimens were negative.

A diagnostic procedure was performed.

### DIFFERENTIAL DIAGNOSIS

**DR. MARK A. POPOVSKY\*:** This middle-aged woman presented with severe anemia and moderately severe thrombocytopenia. She also had a microangiopathic hemolytic process and a catastrophic cerebrovascular event.

Three typical findings led to the diagnosis of thrombotic thrombocytopenic purpura: thrombocytopenia, hemolysis, and neurologic symptoms, but fever and renal dysfunction, which are frequently associated with this disorder, were absent. The prognosis for patients with thrombotic thrombocytopenic purpura has improved greatly over the past 20 years. Without treatment, the mortality rate is 90 percent within three months; with current treatment, it is only 10 to 30 percent.<sup>1</sup> The front-line therapy is plasma exchange with plasma reinfusion. It was used in this case and led to a transfusion-associated complication. The development of acute respiratory distress, severe hypoxemia, and acute bilateral pulmonary edema, accompanied by hypotension and fever, in a patient receiving a transfusion is consistent with the diagnosis of transfusion-related acute lung injury.

Before discussing this complication, I shall consider the differential diagnosis. Respiratory distress is a component of several life-threatening complications of transfusion. In anaphylactic transfusion reactions, respiratory distress is related to bronchospasm and laryngeal edema, not pulmonary edema, as was seen in this case. Symptoms begin within seconds to minutes after transfusion of as little as 5 ml of a plasma-containing blood component. In addition, skin manifestations, usually intense erythema and urticaria, are prominent. There were no skin manifestations in this patient. In most cases, the re-

\*Chief executive officer and chief medical officer, American Red Cross Blood Services—New England Region, Dedham, Mass.; associate clinical professor of pathology, Beth Israel Deaconess Medical Center and Harvard Medical School, Boston.

action is due to anti-IgA antibodies in the recipient that are directed against IgA in the blood product.<sup>2</sup>

Circulatory overload from rapid infusion or massive transfusion of blood is a frequently overlooked diagnosis. One study reported a 1 percent frequency of this complication after orthopedic surgery.<sup>3</sup> Respiratory distress, cyanosis, and tachypnea are prominent features of circulatory overload. Tachycardia and hypertension are usually present. Symptoms generally develop within several hours after transfusion and are usually seen in very young or very old patients. There was no evidence of cardiac decompensation, however, in this case.

Bacterial contamination is increasingly recognized as a cause of transfusion-associated morbidity. Hypotension and vascular collapse begin within two hours after the initiation of a transfusion, associated with gram-positive or gram-negative organisms in cellular blood components, either platelets or red cells.<sup>4,5</sup> Disseminated intravascular coagulation is usually present and is often related to endotoxemia. In this case, the D-dimer test was positive, but the fibrinogen level was normal, and there is no mention of diffuse bleeding or other coagulation abnormalities. Cultures were negative.

Immediate hemolytic transfusion reactions may begin with respiratory distress and hypotension, which usually develop within several hours after transfusion. Antibodies to the blood group A, B, or AB are almost always implicated. Disseminated intravascular coagulopathy is a prominent feature. In this case, the blood bank found no evidence of a transfusion reaction; presumably, a direct antiglobulin test was negative, and there was no evidence of a discrepancy in major blood groups between the transfused units and the recipient's blood. May we see the radiographs?

DR. JO-ANNE O. SHEPARD: The CT scan of the head shows a focus of low attenuation in the left frontal region, a finding consistent with the presence of a cortical infarct; a second cortical infarct is present in the right cerebellum. The first film of the chest (Fig. 1) shows bilateral pulmonary edema, with a normal-appearing cardiomedastinal silhouette. A film obtained two hours later is similar, but there is poor penetration. Twenty-three hours later, there was marked improvement in the pulmonary edema.

DR. POPOVSKY: Transfusion-related acute lung injury is a life-threatening complication that is clinically indistinguishable from the acute respiratory distress syndrome due to causes such as sepsis. The clinical manifestations of transfusion-related acute lung injury include severe bilateral pulmonary edema and hypoxemia, tachycardia, and cyanosis.<sup>6,7</sup> Although the edema may be confined to the lower lung fields initially, it usually involves the entire lung over a period of several hours. Roentgenograms usually demonstrate "whiteout" by interstitial and

alveolar infiltrates, but in the first few hours a patchy pattern may be observed. Other manifestations include fever and mild-to-moderate hypotension, which is frequently unresponsive to the intravenous administration of fluids.

All these clinical manifestations follow the transfusion of plasma-containing blood components, always within one to six hours and usually within one to two hours. This patient received both plasma and red cells. In contrast to patients with circulatory overload, patients with transfusion-related acute lung injury have normal central venous pressure and normal or low pulmonary wedge pressure. Milder forms of respiratory distress may be within the scope of this syndrome.

Transfusion-related acute lung injury differs from the acute respiratory distress syndrome in important ways. Unlike patients with the acute respiratory distress syndrome, approximately 80 percent of those with transfusion-related acute lung injury have both clinical and physiologic improvement within 48 to 96 hours after the initial injury, if they receive prompt and vigorous respiratory support.<sup>6,7</sup> Although the lung injury is irreversible in many patients with the acute respiratory distress syndrome, it is typically transient in those with transfusion-related acute lung injury; the partial pressure of oxygen returns to normal, with radiologic evidence of rapid clearing of edema fluid, as in this case. In one study, all 36 patients with transfusion-related acute lung injury required supplemental oxygen, and 72 percent required short-term mechanical ventilation.<sup>8</sup> In about seven of the patients, however, pulmonary infiltrates persisted for at least seven days, although even these patients had no permanent sequelae. Available data suggest that 5 to 8 percent of patients die from complications of the pulmonary injury,<sup>6</sup> making it one of the three most common causes of transfusion-associated deaths, along with bacterial contamination and hemolytic transfusion reaction.

The frequency of transfusion-related acute lung injury is unknown. In a study conducted in the mid-1980s, 1 in 5000 plasma-containing transfusions was associated with this reaction.<sup>6,8,9</sup> However, this study was performed during the period in which blood banks in the United States were converting to the use of red-cell concentrates that contained considerably less plasma. With the reduction of plasma from an average of 100 ml to a maximum of 50 ml per transfused unit, the frequency of transfusion-related acute lung injury has probably decreased, even though the number of reports in the literature has greatly increased. From 1951, when the syndrome was first described, until 1984, fewer than 40 cases were reported in the English-language literature.<sup>10-18</sup> Since then, at least 90 cases have been reported,<sup>9,19-34</sup> and I am aware of an additional 60 unpublished cases.

In a study by Clarke et al.,<sup>35</sup> 46 (0.32 percent) of

14,602 transfusions of random-donor platelets administered to patients with hematologic cancers were associated with severe respiratory reactions over a two-year period in a single general hospital. Rare reactions were also seen in recipients of red cells. In cases of reactions to platelets, the average age of the platelets at the time of transfusion was 4.5 days, which was significantly greater than in control cases. Investigators have failed to identify patients at risk for transfusion-related acute lung injury, although recurrences have been reported. The disorder affects males and females in equal numbers and has been reported in patients from 1 month to 87 years old.<sup>9,26</sup> Most patients have not had histories of transfusion reactions.

In a study in New Zealand, 0.001 percent of 440,000 transfusions of blood components were associated with respiratory reactions.<sup>36</sup> The fact that this frequency and that reported by Clarke et al.<sup>35</sup> differ by a factor of more than 300 may reflect the level of awareness at a particular medical center more than a true difference in frequency.

There is evidence that transfusion-related acute lung injury may be underdiagnosed. In a study of pulmonary edema in patients undergoing surgery, Cooperman and Price<sup>37</sup> found that in half the cases the edema had been attributed to circulatory overload or considered idiopathic. In some of these cases, transfusion-related acute lung injury might have been responsible. In an analysis of transfusion-associated deaths reported to the Food and Drug Administration from 1976 to 1985, acute pulmonary injury was implicated in 31 of 256 cases (12.1 percent).<sup>38</sup> In this study, acute-onset pulmonary edema was the third most common cause of death from transfusion. Because of advances in the prevention of transfusion-associated hepatitis B and C, transfusion-related acute lung injury has increased in relative importance as a risk of transfusion.

Transfusion-related acute lung injury is associated with the transfusion of blood components containing plasma. Reported cases have involved whole blood, red cells prepared in a variety of preservation solutions, granulocytes collected by apheresis, platelet concentrates, and platelets collected by apheresis and cryoprecipitation.<sup>6</sup> In most cases, the implicated blood component contains more than 60 ml of plasma. It is noteworthy that plasma derivatives, such as albumin, plasma protein fraction, and gamma globulin, which are manufactured from large pools of donated plasma with the use of Cohn fractionation procedures, have not been associated with transfusion-related acute lung injury.

Although the pathogenesis of transfusion-related acute lung injury is unknown, there are sufficient clues to implicate an immune reaction. Unlike most immunologically triggered transfusion reactions, the pathologic antibodies in transfusion-related acute

lung injury typically originate from donors, rather than recipients. Numerous reports have documented the presence of HLA-specific antibodies or leukoagglutinins in plasma from the donors of implicated blood components.<sup>10</sup> In a study, Moore and I found such antibodies in 89 percent of 36 cases.<sup>8</sup> In about half the cases, HLA-A or HLA-B antibodies from the donor of the implicated blood components corresponded with one or more of the recipient's HLA epitopes. Goeken and coworkers<sup>16</sup> have reported similar findings. In other studies, neutrophil-specific antibodies (to NA2, 5b, and NB2) have been identified in the serum of implicated units of blood.<sup>13,18,23</sup> The donors of these blood components are usually multiparous women. I know of one case in which blood components donated by a woman who had had 16 pregnancies were associated with transfusion-related acute lung injury in at least three patients. In 5 percent of reported cases, HLA antibodies or neutrophil-specific antibodies were found in serum obtained from the patient before transfusion. In 5 to 15 percent of cases, no antibody was identified in either patient or donor.

Antibodies in the donor are suspected to be the causative agent, because the "substrate" with which the leukocyte antibodies can react — namely, the recipient's entire circulating and marginated pool of leukocytes — is far larger than the quantity of leukocytes present in a single transfused component. Transfusion-related acute lung injury apparently begins with the passive transfer of antibody from the donor's plasma to the recipient, which sets off a chain of reactions.

Much of the current understanding of the relation of these antibodies to transfusion-related acute lung injury is gleaned from studies of the acute respiratory distress syndrome. Although the mechanisms involved in the development of this syndrome are complex, considerable evidence suggests that when complement is activated, C5a promotes aggregation, margination, and sequestration of neutrophils in the pulmonary microvasculature.<sup>39,40</sup> Studies in rabbits as well as observations in patients with the acute respiratory distress syndrome show that when complement-activated neutrophils release proteases, oxygen radicals, and acidic lipids, the pulmonary vascular endothelium is damaged, with subsequent extravasation of protein-laden fluid into the interstitium and alveoli.<sup>41,42</sup>

In studies in animals, Larsen et al.<sup>43</sup> demonstrated that C5a fragments consistently produced lung inflammation characterized by neutrophil accumulation and edema. These changes probably account for the radiographic and clinical findings in patients with transfusion-related acute lung injury. In one study, transfusion of 50 ml of blood containing leukoagglutinins to a healthy person caused a severe pulmonary reaction,<sup>44</sup> suggesting that the passive

transfer of leukocyte antibodies may have an important, if not decisive, role in triggering the reaction. Since lymphocytotoxic (i.e., HLA) antibodies readily fix complement, passive transfusion of these antibodies probably accounts for complement activation and the sequence of clinical events described previously.

Observations described by Seeger et al.<sup>45</sup> contribute to our understanding of the relation between donor antibodies and the development of transfusion-related acute lung injury. Using an *ex vivo* rabbit-lung model, these investigators found that acute lung injury with severe edema resulted from the infusion of a mixture of complement, antibodies to 5b, and 5b-positive human neutrophils. This change was seen three to six hours after the infusion, paralleling the clinical presentation in humans. Other investigators have documented a similar pathologic time line.<sup>42</sup> When complement, antibodies to 5b, or 5b-positive granulocyte antigen was omitted from the experiments, no pathologic changes occurred. Although these findings suggest that the correspondence between antibody specificity and a transfusion-recipient epitope is important in the pathogenesis of the respiratory decompensation seen in transfusion-related acute lung injury, they do not explain cases in which the HLA- or neutrophil-specific antibody does not share epitopes with the recipient. Despite the presence of HLA-specific antibodies in 1 to 2 percent of blood donors, transfusion-related acute lung injury is an infrequent result of transfusion.

Other factors, such as the character of the antibody, the nature and distribution of the related antigen, the extent of complement activation, and the immune status of the recipient, probably determine the final clinical response.<sup>34,46</sup> Silliman et al.<sup>33</sup> identified a group of patients with transfusion-related acute lung injury in whom no HLA or leukocyte antibodies were found. The investigators reported the presence of a neutrophil priming agent, a lipid, in the blood components given to these patients. They postulated that this lipid develops during routine storage of blood components and that it primes polymorphonuclear oxidase. They found that cellular blood components (e.g., whole blood, red cells, and platelet concentrate) at the end of their normal shelf life contained a priming agent that enhanced polymorphonuclear NADPH oxidase activity by a factor of 2.1 to 2.8.<sup>33</sup> Since this study provided the first description of a non-antibody-mediated model of transfusion-related acute lung injury, confirmatory studies are needed.

One other mechanism that merits discussion involves cytokines. Several reports implicate cytokines, including tumor necrosis factor and interleukin-8, in the pathogenesis of IgG-mediated hemolytic transfusion reactions.<sup>47,48</sup> Patients with such reactions may have hypoxemic or hypercapnic respiratory failure,

or both.<sup>49</sup> It may be relevant that during hemolytic transfusion reactions, the levels of tumor necrosis factor increase, and tumor necrosis factor has been implicated in the development of septic acute respiratory distress syndrome.<sup>50</sup> It has been suggested that the release of considerable quantities of tumor necrosis factor from degranulating neutrophils may contribute to the injury of pulmonary-capillary endothelium that occurs in the acute respiratory distress syndrome. How these observations are related to transfusion-related acute lung injury remains conjectural. The syndrome is probably part of a spectrum of lung injury, with its effects lying between the reversible changes of noncardiogenic pulmonary edema and the permanent structural changes of the acute respiratory distress syndrome.

Since there is no diagnostic test for or pathognomonic sign of transfusion-related acute lung injury, it is a diagnosis of exclusion. One must rule out the other causes of respiratory distress and pulmonary edema in patients receiving transfusions: myocardial infarction, circulatory overload, and bacterial infection. Normal central venous and pulmonary wedge pressures are consistent with the diagnosis of transfusion-related acute lung injury. The presence of lymphocytotoxic, HLA, or granulocyte-specific antibodies in the donor's or recipient's serum is strongly suggestive of the diagnosis. A positive result of a lymphocyte crossmatch between donor and patient provides important supportive evidence.

Although early reports of transfusion-related acute lung injury described fulminant respiratory distress, not all cases are life-threatening. Respiratory support should be as intensive as necessary. In almost all cases, oxygen supplementation is essential, and if the hypoxemia is severe, intubation and mechanical ventilation are important. Once the diagnosis is seriously considered, therapy should be started promptly. Pressor agents may be useful in cases of sustained hypotension. Corticosteroids are probably of marginal value, and diuretics have no role because microvascular injury, rather than fluid overload, is involved.

In cases in which antibody from a donor has been implicated, no special preventive measures are necessary to manage future transfusions of plasma-containing components. It has been suggested that in the few cases involving antibody in the recipient, future transfusions of cellular components be filtered to reduce the leukocyte content. In view of the low reported incidence of transfusion-related acute lung injury, however, no data are available to support or refute this approach.

I conclude that the patient under discussion had thrombotic thrombocytopenic purpura that was complicated by acute lung injury related to transfusions of plasma or red cells during therapeutic plasma exchange. The diagnostic procedure was probably a

screening test for HLA or granulocyte antibody in serum from donors or donor units. I would also have performed a lymphocyte crossmatch.

DR. ROBERT B. COLVIN: Is the very short interval between the transfusion and the reaction in this case characteristic of transfusion-related acute lung injury?

DR. POPOVSKY: I have seen cases in which the interval was only a few minutes, although the typical interval is 30 to 120 minutes.

### CLINICAL DIAGNOSIS

Transfusion-related acute lung injury.

### DR. MARK A. POPOVSKY'S DIAGNOSIS

Thrombotic thrombocytopenic purpura complicated by transfusion-related acute lung injury.

### PATHOLOGICAL DISCUSSION

DR. SUSAN L. SAIDMAN: The diagnostic test was a cytotoxicity assay for antilymphocyte antibodies. Plasma from the donor units, as well as a sample of the patient's serum obtained before the plasmapheresis, was screened with the use of a panel of lymphocytes chosen to contain a broad array of HLA antigens (with the result expressed as the percentage of panel-reactive antibody). All the samples from donors were negative for antilymphocyte antibodies, except for a sample from one donor who was multiparous. The diagnosis was supported by a positive cytotoxic crossmatch, with the donor's plasma reacting against the patient's lymphocytes.

DR. COLVIN: Do we know the specificity of the donor's antibodies? I assume they were HLA class I.

DR. SAIDMAN: They were class I. The crossmatch was positive with the patient's T lymphocytes, indicating that the antibody was probably specific for HLA class I antigens. On the basis of the cell panel that was tested, we could not identify which class I antigens were being recognized. Because the crossmatch was positive, we did not perform additional tests to determine specificity.

DR. EUGENE J. MARK: The patient recovered after the acute episode, and she left the hospital a few days later.

### LABORATORY DIAGNOSES

*Transfusion-related acute lung injury.*

*Thrombotic thrombocytopenic purpura.*

### REFERENCES

1. Rock GA, Shumak KH, Buskard NA, et al. Comparison of plasma exchange with plasma infusion in the treatment of thrombotic thrombocytopenic purpura. *N Engl J Med* 1991;325:393-7.
2. Pineda AA, Taswell HF. Transfusion reactions associated with anti-IgA antibodies: report of four cases and review of the literature. *Transfusion* 1975;15:10-5.
3. Popovsky MA, Audet AM, Andrzejewski C. Transfusion-associated circulatory overload in orthopedic surgery patients: a multi-institutional study. *Immunohematology* 1996;12(2):87-9.
4. Stack G, Judge JV, Snyder EL. Febrile and non-immune transfusion reactions. In: Rossi EC, Simon TL, Moss GS, Gould SA, eds. *Principles of transfusion medicine*. 2nd ed. Baltimore: Williams & Wilkins, 1996:773-84.
5. Blajchman MA, Ali AM. Bacteria in the blood supply: an overlooked issue in transfusion medicine. In: Nance ST, ed. *Blood safety: current challenges*. Bethesda, Md.: American Association of Blood Banks, 1992:213-28.
6. Popovsky MA, Chaplin HC Jr, Moore SB. Transfusion-related acute lung injury: a neglected, serious complication of hemotherapy. *Transfusion* 1992;32:589-92.
7. Popovsky MA. The role of leukocyte depletion in prevention of transfusion-related acute lung injury. In: Sweeney J, Heaton A, eds. *Clinical benefits of leukodepleted blood products*. Austin, Tex.: R.G. Landes, 1995:129-35.
8. Popovsky MA, Moore SB. Diagnostic and pathogenetic considerations in transfusion-related acute lung injury. *Transfusion* 1985;25:573-7.
9. Popovsky MA. Transfusion-related acute lung injury. In: Popovsky MA, ed. *Transfusion reactions*. Bethesda, Md.: AABB Press, 1996:167-83.
10. Popovsky MA, Abel MD, Moore SB. Transfusion-related acute lung injury associated with passive transfer of antileukocyte antibodies. *Am Rev Respir Dis* 1983;128:185-9.
11. Barnard RD. Indiscriminate transfusion: a critique of case reports illustrating hypersensitivity reactions. *N Y State J Med* 1951;51:2399-402.
12. Dubois M, Lotze MT, Diamond WJ, Kim YD, Flye MW, Macnamara TE. Pulmonary shunting during leukoagglutinin-induced noncardiac pulmonary edema. *JAMA* 1980;244:2186-9.
13. Culliford AT, Thomas S, Spencer FC. Fulminating noncardiogenic pulmonary edema: a newly recognized hazard during cardiac operations. *J Thorac Cardiovasc Surg* 1980;80:868-75.
14. Yomtovian R, Kline W, Press C, et al. Severe pulmonary hypersensitivity associated with passive transfusion of a neutrophil-specific antibody. *Lancet* 1984;1:244-6.
15. Reese EP Jr, McCullough JJ, Craddock PR. An adverse pulmonary reaction to cryoprecipitate in a hemophiliac. *Transfusion* 1975;15:583-8.
16. Goeken NE, Schulak JA, Nghiem DD, Knox LB, Reynolds LS, Corry RJ. Transfusion reactions in donor-specific blood transfusion patients resulting from transfused maternal antibody. *Transplantation* 1984;38:306-7.
17. Dhainaut JF, Brossard Y, Dimercurio JP, et al. Oedème pulmonaire léSIONNEL gravissime au cours de 20 échanges plasmatiques pour incompatibilité rhésus. In: *Hemoperfusion échange plasmatique en reanimation*. Paris: Expansion Scientifique Française, 1981:291-8.
18. Campbell DA Jr, Swartz RD, Waskerwitz JA, Haines RF, Turcotte JG. Leukoagglutination with interstitial pulmonary edema: a complication of donor-specific transfusion. *Transplantation* 1982;34:300-1.
19. Van Buren NL, Stroncek DF, Clay ME, McCullough J, Dalmasso AP. Transfusion-related acute lung injury caused by an NB2 granulocyte-specific antibody in a patient with thrombotic thrombocytopenic purpura. *Transfusion* 1990;30:42-5.
20. Eastlund T, McGrath PC, Britten A, Propp R. Fatal pulmonary transfusion reaction to plasma containing donor HLA antibody. *Vox Sang* 1989;57:63-6.
21. Eastlund DT, McGrath PC, Burkart P. Platelet transfusion reaction associated with interdonor HLA incompatibility. *Vox Sang* 1988;55:157-60.
22. O'Connor JC, Strauss RG, Goeken NE, Knox LB. A near-fatal reaction during granulocyte transfusion of a neonate. *Transfusion* 1988;28:173-6.
23. Levy GJ, Shabot MM, Hart ME, Mya WW, Goldfinger D. Transfusion-associated noncardiogenic pulmonary edema: report of a case and a warning regarding treatment. *Transfusion* 1986;26:278-81.
24. Nordhagen R, Conradi M, Dromtorp SM. Pulmonary reaction associated with transfusion of plasma containing anti-5b. *Vox Sang* 1986;51:102-7.
25. De Wolf AM, Van den Berg BW, Hoffman HJ, van Zundert AA. Pulmonary dysfunction during one-lung ventilation caused by HLA-specific antibodies against leukocytes. *Anesth Analg* 1987;66:463-7.
26. Leaman B, Anderson D, Walker I, Heddle N. Two episodes of noncardiogenic pulmonary edema in a patient caused by the same donor's blood. *Transfusion* 1994;34:Suppl:26S. abstract.
27. Win N, Kaye T, Jones L, Knowles S. Transfusion-related acute lung injury (TRALI). *Transfus Med* 1995;5:Suppl 1:33. abstract.
28. Lin M, Chen CC, Hong CC, Lin WS, Cheng YP. Transfusion-associated respiratory distress in Taiwan. *Vox Sang* 1994;67:372-6.
29. Reissman P, Manny N, Shapira SC, Shapira Y, Cotev S. Transfusion-related adult respiratory distress syndrome. *Isr J Med Sci* 1993;29:303-7.
30. Popovsky MA, Chaplin HC Jr, Moore SB. Transfusion-related acute lung injury. *Transfusion* 1993;33:444-5.
31. Bux J, Hoch J, Bindl L, Müller A, Mueller-Eckhardt C. Transfusion-

- sassozierte akute Lungeninsuffizienz: Diagnosesicherung durch den Nachweis granulozytärer Antikörper. *Dtsch Med Wochenschr* 1994;119:19-24.
32. Jeter EK, Madyastha P, Rodriguiz RM, Key LL. Transfusion associated acute lung injury induced by granulocyte-bound cytophilic IgG. *Transfusion* 1994;34:Suppl:65S. abstract.
33. Silliman C, Pitman J, Thurman G, Ambruso D. Neutrophil (PMN) priming agents develop in patients with transfusion related acute lung injury. *Blood* 1992;80:Suppl 1:261a. abstract.
34. Gans ROB, Duurkens VAM, van Zundert AA, Hoorntje SJ. Transfusion-related acute lung injury. *Intensive Care Med* 1988;14:654-7.
35. Clarke G, Podlosky L, Petrie L, Boshkov L. Severe respiratory reactions to random donor platelets: an incidence and nested case-control study. *Blood* 1994;84:Suppl 1:465a. abstract.
36. Henderson RA, Pinder L. Acute transfusion reactions. *N Z Med J* 1990;103:509-11.
37. Cooperman LH, Price HL. Pulmonary edema in the operative and postoperative period: a review of 40 cases. *Ann Surg* 1970;172:833-91.
38. Sazama K. Reports of 355 transfusion-associated deaths: 1976 through 1985. *Transfusion* 1990;30:583-90.
39. Jacob HS, Craddock PR, Hammerschmidt DE, Moldow CE. Complement-induced granulocyte aggregation: an unsuspected mechanism of disease. *N Engl J Med* 1980;302:789-94.
40. Hammerschmidt DE, Jacob HS. Adverse pulmonary reactions to transfusion. *Adv Intern Med* 1982;27:511-30.
41. Shasby DM, Vanbenthuysen KM, Tate RM, Shasby SS, McMurtry I, Repine JE. Granulocytes mediate acute edematous lung injury in rabbits and in isolated rabbit lungs perfused with phorbol myristate acetate: role of oxygen radicals. *Am Rev Respir Dis* 1982;125:443-7.
42. Sznajder JI, Fraiman A, Hall JB, et al. Increased hydrogen peroxide in the expired breath of patients with acute hypoxemic respiratory failure. *Chest* 1989;96:606-12.
43. Larsen GL, McCarthy K, Webster RO, Henson J, Henson PM. A differential effect of C5a and C5a des Arg in the induction of pulmonary inflammation. *Am J Pathol* 1980;100:179-92.
44. Brittingham TE. Immunologic studies on leukocytes. *Vox Sang* 1957;2:242-8.
45. Seeger W, Schneider U, Kreisler B, et al. Reproduction of transfusion-related acute lung injury in an ex vivo lung model. *Blood* 1990;76:1438-44.
46. Westaby S. Mechanisms of membrane damage and surfactant depletion in acute lung injury. *Intensive Care Med* 1986;12:2-5.
47. Davenport RD, Polak TJ, Kunkel SL. White cell-associated procoagulant activity induced by ABO incompatibility. *Transfusion* 1994;34:943-9.
48. Davenport RD, Strieter RM, Staniford TJ, Kunkel SL. Interleukin-8 production in red blood cell incompatibility. *Blood* 1990;76:2439-42.
49. Capon SM, Goldfinger D. Acute hemolytic transfusion reaction, a paradigm of the systemic inflammatory response: new insights into pathophysiology and treatment. *Transfusion* 1995;35:513-20. [Erratum, *Transfusion* 1995;35:794.]
50. Tracey KJ, Lowry SF, Cerami A. Cachetin/TNF-alpha in septic shock and septic adult respiratory distress syndrome. *Am Rev Respir Dis* 1988;138:1377-9.

©1998, Massachusetts Medical Society.

---

### 35-MILLIMETER SLIDES FOR THE CASE RECORDS

---

Any reader of the *Journal* who uses the Case Records of the Massachusetts General Hospital as a medical teaching exercise or reference material is eligible to receive 35-mm slides, with identifying legends, of the pertinent x-ray films, electrocardiograms, gross specimens, and photomicrographs of each case. The slides are 2 in. by 2 in., for use with a standard 35-mm projector. These slides, which illustrate the current cases in the *Journal*, are mailed from the Department of Pathology to correspond to the week of publication and may be retained by the subscriber. Each year approximately 250 slides from 40 cases are sent to each subscriber. The cost of the subscription is \$450 per year. Application forms for the next subscription year, which begins in January, may be obtained from Lantern Slides Service, Department of Pathology, Massachusetts General Hospital, Boston, MA 02114 (telephone [617] 726-4369). Slides from individual cases may be obtained at a cost of \$35 per case.

---