

## Recurrent Abrupt Occlusion after Transluminal Angioplasty for Basilar Artery Stenosis: Case Report

Carlos Jimenez, M.D., Hoang Duong, M.D.,  
Marcelo Olarte, M.D., John Pile-Spellman, M.D.

Servicio de Neurocirugía (CJ), Hospital Universitario San Vicente de Paul, Medellín, Colombia, and Departments of Radiology (HD, JP-S) and Neurology (MO), Columbia University, New York, New York

**OBJECTIVE AND IMPORTANCE:** Angioplasty for basilar artery stenosis is often complicated by recurrent abrupt vessel closure. The clinical results can be catastrophic. In this case report, we assess the effects of intra-arterial papaverine (American Regent Laboratories Inc., Shirley, NJ) on rebound occlusion.

**CLINICAL PRESENTATION:** The patient presented with crescendo transient ischemic attacks from atherosclerotic narrowing of the midbasilar artery despite maximal medical treatment.

**INTERVENTION:** Angioplasty of the midbasilar artery was performed with serial balloon inflations. The patient was treated successfully with intra-arterial papaverine and achieved a nearly full recovery, with only mild dysarthria, by the time of the 7-month follow-up examination.

**CONCLUSION:** Using intra-arterial papaverine, we were able to reverse the effects of this potentially life-threatening complication of basilar artery angioplasty. (*Neurosurgery* 44:210-215, 1999)


**Key words:** Angioplasty, Arteromatous stenosis, Basilar artery, Intra-arterial vasodilators

Basilar artery stenosis produces a stroke syndrome with variable but often poor prognosis. Currently, the only medical treatment available is the use of systemic anticoagulation. If this fails, however, the only remaining therapeutic option is percutaneous transluminal angioplasty (PTA). Unfortunately, abrupt vessel occlusion commonly occurs during angioplasty, with devastating clinical consequences. In this report, we were able to reverse this complication by using intra-arterial papaverine. We present a literature review and a discussion of the clinical and technical aspects of basilar artery angioplasty.

### CASE REPORT

A 58-year-old man presented with recurrent posterior circulation transient is-

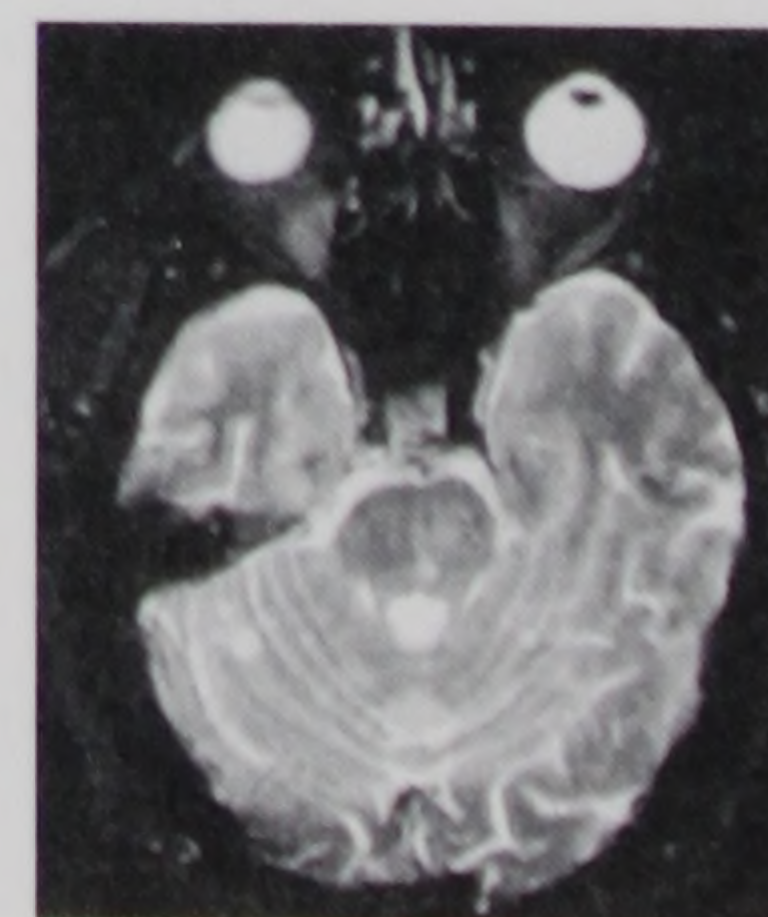chemic attacks (TIAs) of increasing severity, consisting of blurred vision, diplopia, dysarthria, and perioral and facial numbness of 2 weeks' duration. Magnetic resonance (MR) imaging and MR angiography revealed a tight midbasilar artery stenosis and a left occipital infarct. The patient was initially managed with intravenously administered heparin (Elkins-Sinn, Inc., Cherry Hill, NJ) therapy for 1 week, resulting in no clinical improvement. Angiography was performed and did the following: 1) confirmed the presence of a tight eccentric stenosis at the midbasilar level (*Fig. 1*) and occlusion of the distal left vertebral artery, 2) failed to demonstrate competent posterior communicating arteries supplying the basilar artery in a retrograde fashion, and 3) showed a left posterior cerebral artery occlusion. The



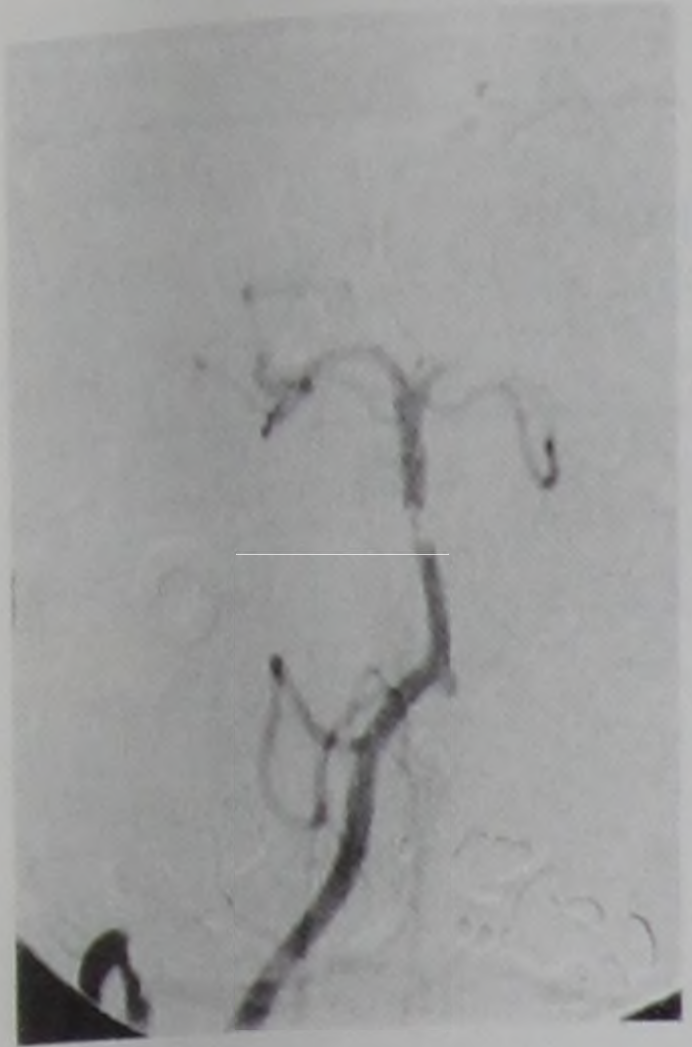
**FIGURE 1.** Right vertebral arteriogram showing a tight eccentric stenosis at the midbasilar level (*arrowhead*) and occlusion of the distal left vertebral artery just below the vertebrobasilar junction (*arrow*).

patient was monitored in the neurological intensive care unit and received vasopressors to maintain adequate perfusion across the basilar artery stenosis. Follow-up MR imaging/MR angiography performed 1 week later revealed worsening of the midbasilar stenosis and hyperintense foci on T2-weighted sequences in the upper pons and the right cerebellar hemisphere, which were interpreted as new infarcts (*Fig. 2*). At that point, the decision was made to offer angioplasty to prevent a major brain stem infarct.

With the patient under general anesthesia, repeat angiography showed interval progression of the basilar artery stenosis above the level of the anterior-inferior cerebellar arteries (*Fig. 3*). Before angioplasty, 120,000 units of urokinase (Abbott Laboratories, North Chicago, IL), 2,000 units of heparin, and 2 mg of verapamil (American Regent Laboratories Inc.) were infused intra-arterially in the proximal basilar artery. Angioplasty was performed with a 2 mm × 2-cm Stealth balloon microcatheter system (Target Therapeutics, Fremont, CA) that was introduced via a 6-French guiding catheter positioned in the distal right vertebral artery. The balloon was inflated to 6 atmospheres, with good initial results. Five to 10 minutes later,



**FIGURE 2.** Preangioplasty T2-weighted axial image showing hyperintense foci in the upper pons and the right cerebellum, consistent with new infarcts.



**FIGURE 3.** Repeat angiogram, obtained 1 week later, showing progression of basilar artery stenosis above the level of the anteroinferior cerebellar arteries.

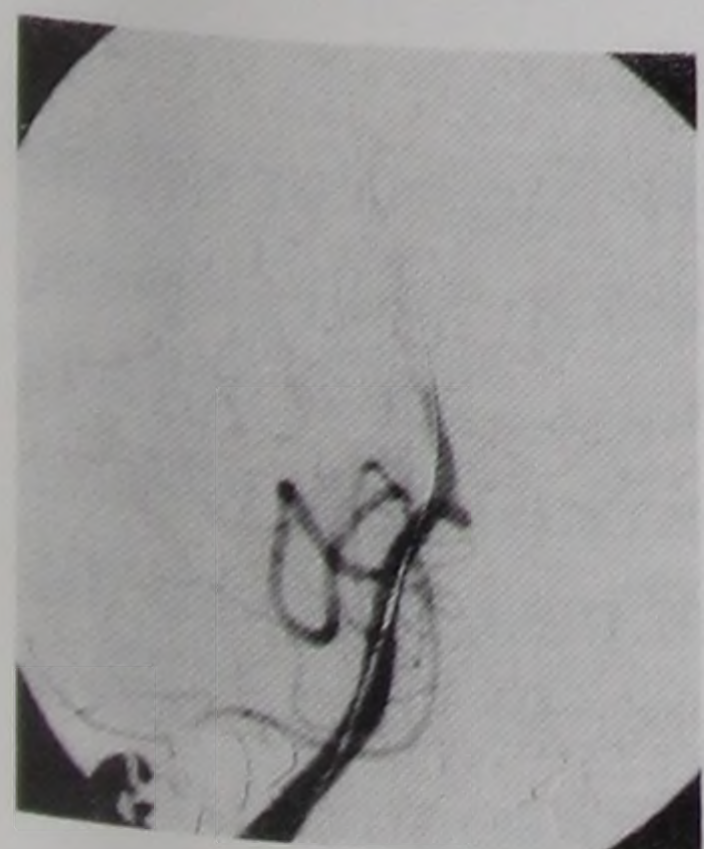
however, repeat angiography showed abrupt reclosure. Angioplasty was again attempted, but reocclusion occurred after 5 to 10 minutes (Fig. 4). This scenario was repeated four times with the same balloon and three times with a 2.5 mm × 2-cm Stealth balloon (Target Therapeutics). After the eighth balloon inflation, intra-arterial papaverine was administered. A total of 110 mg of papaverine was infused in small boluses into the proximal basilar artery. Control angiography revealed significant improvement in arterial lumen, with good antegrade flow (Fig. 5).

At the end of the procedure, the patient was able to follow commands and move all four extremities. He was kept intubated overnight in the neurological intensive care unit and was given intravenously administered heparin. Mild induced hypertension was also maintained. The patient was neurologically intact and reported that his TIAs had completely resolved. He was discharged home and suffered only mild dysarthria at the time of the 7-month follow-up examination.

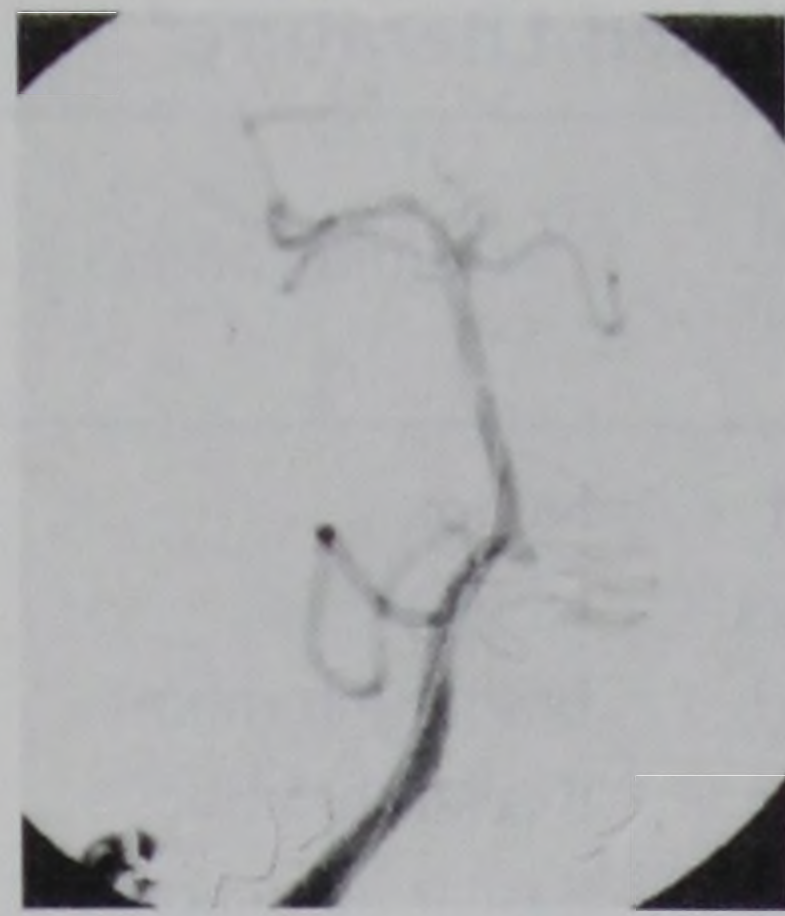
## DISCUSSION

### Natural history of basilar artery occlusive disease

The natural history of atherosclerotic basilar artery stenosis is reported to be highly variable (18, 25, 28, 36), with estimated long-term prognosis ranging from good (29) to severe neurological deficits or death (3, 8, 10, 18). One-third



**FIGURE 4.** Postangioplasty angiogram showing complete midbasilar artery occlusion. Arterial spasm was suspected.



**FIGURE 5.** Final angiogram obtained after intra-arterial infusion of 110 mg of papaverine, showing significant improvement in the basilar artery lumen with good antegrade flow.

(29) to one-half (28) of patients with angiographically proven severe vertebrobasilar artery occlusive disease progress to brain stem infarction. The reported mortality rate associated with the disease for medically managed patients ranges from 22 (4) to 86% (11).

Atherosclerotic disease tends preferentially to affect the proximal and middle segments of the basilar artery (4, 29) and clinically manifests as stroke syndrome caused by either small or large vessel disease (4). Small vessel disease has a more benign course than that of basilar artery occlusion (8). Severe basilar artery stenosis or occlusion (large vessel disease) usually manifests as TIAs that announce a brain stem stroke; however, TIAs without subsequent infarct may also remain the sole manifestation of the disease (4, 29).

Although many patients respond well to anticoagulation (3, 4), some experience progressive deterioration despite maximum therapy. Therefore, it seems appropriate to offer emergency endovascular intervention to those who have crescendo TIAs despite full anticoagulation therapy, for fear of a devastating impending stroke (13).

The first angioplasty experience of the basilar artery was reported in 1980 by Sundt et al. (31, 32). In 1987, Higashida et al. (12) reported the case of a brain stem infarction occurring after PTA in a patient with tandem stenosis of the basilar artery. It was not until 1992 (1), simultaneously with the development of endovascular techniques (13, 14, 26, 34), that basilar artery PTA for atherosclerotic disease was again reported. To date, a review of the published literature identifies a total of 35 cases (1-3, 12, 14, 15, 21, 22, 26, 27, 31-35, 38, 39), with a moderately low complication rate (20%) and no reported mortality. Com-

plete clinical, cerebral blood flow, and angiographic follow-up data are available in only a minority of cases (2 of 35 cases). The mean age was 59 years (range, 48-76 yr), and the overwhelming sex preponderance was male (16 of 17 patients). The majority were treated for medically intractable TIAs (20 of 23 patients), and the postprocedure clinical condition persisted unchanged in one-half of the patients (10 of 20 patients). At the time of follow-up, there were no new symptoms in most cases (17 of 19 cases), and restenosis in angiographic follow-up was observed in 3 of 12 patients (Table 1).

### Challenges of basilar artery angioplasty

In 1996, both Takis et al. (33) and Nakatsuka et al. (27) pointed out the necessity of highly selective criteria for basilar artery PTA because of its potential risks. First, navigation inside the vertebrobasilar system is more difficult and hazardous than in the anterior circulation because of more tortuous, smaller vessels (9, 13). Second, and more importantly, the many perforating branches arising directly from the basilar artery at right angles, which supply the brain stem and the thalamus, are exposed to the devastating consequences of dissection, vasospasm, and ostial occlusion during balloon inflation (12, 13, 26, 27, 33, 34). Therefore, the procedure is generally considered only after medical treatment failure.

There is a wide variety in the reported technical aspects of angioplasty for basilar artery stenosis. The diameters of the balloons used ranged from 2 mm (27, 34, 38) to 3.5 mm (34), and the reported inflation pressures ranged from 1 (26) to 8 atmospheres (39). In addition, the number of inflations performed in one procedure ranged from one (5, 12, 34, 35) to six (26, 39), with durations ranging from 5 seconds to 120 seconds (15) (Table 2).

### Intra-arterial papaverine

Papaverine is a nonspecific smooth muscle relaxant with a potent adenosine 3',5'-cyclic monophosphate phosphodiesterase-inhibiting effect (23). Intra-arterial papaverine has been mainly reported in association

TABLE 1. Clinical Aspects of Basilar Artery Angioplasty in Published Literature<sup>a</sup>

Series (Ref. No.)	Case No.	Age (yr)/Sex	Indication <sup>b</sup>	Stenosis (%) (pre/post)	Clinical Outcome	Complication	Postoperative CBF Procedure	Angiographic Follow-up	Clinical Follow-up (mo)/Symptoms
Sundt et al., 1980 (31)	1	56/M	Refractory	95/20	Improved	None	Not done	Not done	2/None
	2	48/M	Refractory	95/60	Unchanged	None	Not done	Patent at 2 mo	5/None
Sundt et al., 1982 (32)	3	NA	NA	NA	Worsened	Basilar thrombosis	NA	NA	NA
	4	NA	NA	NA	Worsened	Basilar thrombosis	NA	NA	NA
Higashida et al., 1987 (12)	5	76/M	Refractory	80/NA	Worsened	Basilar infarction	Not done	Not done	Several wk/None
Ahuja et al., 1992 (1)	6	68/M	Progressive stroke	95/NA	Unchanged	None	Not done	Restenosis at 6 mo	24/None
Yamamura et al., 1994 (39)	7	54/F	Progressive stroke	Severe/NA	Improved	None	Not done	NA	1/None
Terada et al., 1994 (35)	8	61/M	Progressive stroke	90/mild, residual	Unchanged	Brain stem infarction	Not done	50% Restenosis at 1 mo	6/None
Houdart et al., 1995 (14)	9	67/M	Refractory	Tight/90	Improved	PICA dissection/subclinical	Not done	Patent at 6 mo	12/None
Nakano et al., 1995 (26)	10	50/M	Refractory	Severe/NA	Unchanged	None	Not done	Patent at 6 mo	6/None
Clark et al., 1995 (5)	11	NA	Refractory	72/46	NA	None	Not done	Patent at 6 mo	NA
	12	NA	Refractory	65/0	NA	None	Not done	Patent at 6 mo	NA
	13	NA	Refractory	74/43	NA	None	Not done	Patent at 6 mo	20/NA
	14	NA	Refractory	81/95	NA	None	Not done	Not done	9/NA
	15	NA	Refractory	82/59	NA	None	Not done	Not done	51/TIAs
Terada et al., 1996 (34)	16	59/M	Refractory	90/50	Unchanged	None	Not done	Not done	18/None
	17	52/M	Refractory	70/60	Unchanged	None	Not done	Patent at 6 wk	48/None
	18	50/M	Refractory	90/40	Unchanged	None	Not done	Not done	13/None
	19	60/M	Refractory	90/50	Unchanged	None	Not done	Restenosis at 6 mo	13/TIAs
	20	61/M	Refractory	90/50	Improved	None	Not done	Patent at 1 mo	17/None
Nakatsuka et al., 1996 (27)	21	72/M	Refractory	90/50	Unchanged	None	SPECT	NA	10/None
	22	56/M	Refractory	90/60	Unchanged	None	SPECT	Patent at 6 mo	13/None
Takis et al., 1996 (33)	23	NA	NA	NA	Worsened	Stroke	NA	NA	NA
McKenzie et al., 1996 (22)	24	NA	Refractory	NA	NA	NA	Not done	NA	NA
Berger and Callahan, 1997 (2)	25	NA	NA	NA	NA	Stroke	Not done	NA	NA
Hyodo et al., 1997 (15)	26	NA	NA	>70/NA	NA	NA	Not done	NA	NA
	27	NA	NA	>70/NA	NA	NA	Not done	NA	NA
	28	NA	NA	>70/NA	NA	NA	Not done	NA	NA
	29	NA	NA	>70/NA	NA	NA	Not done	NA	NA
	30	NA	NA	>70/NA	NA	NA	Not done	NA	NA
	31	NA	NA	>70/NA	NA	NA	Not done	NA	NA
Marks et al., 1997 (21)	32	NA	NA	NA	NA	NA	Not done	NA	NA
	33	NA	NA	NA	NA	NA	Not done	NA	NA
	34	NA	NA	NA	NA	NA	Not done	NA	NA
Wallace et al., 1997 (38)	35	60/M	Refractory	100/NA	Improved	None	TCD	Not done	1/None
Present case	36	58/M	Refractory	90/20	Improved	None	TCD/SPECT	Not done	2/None

<sup>a</sup> pre/post, before and after surgery; CBF, cerebral blood flow; NA, information not available; PICA, posteroinferior cerebellar artery; SPECT, single photon emission computed tomography; TCD, transcranial Doppler ultrasonography; TIA, transient ischemic attack.

<sup>b</sup> "Refractory" indicates refractory to maximum medical therapy, including anticoagulation, fluid therapy, and vasopressors.

with cerebral vasospasm after subarachnoid hemorrhage (6, 7, 17, 20, 24, 37, 40). Concerning atherosclerotic disease, although papaverine has been used during coronary angioplasty (16), it is not commonly used for coronary circulation (19) or in body interventional proce-

dures (30) concomitantly with angioplasty. In the coronary vessels, with abrupt occlusion after angioplasty, successful treatment with papaverine was thought to be caused by its effect on resistance vessels (16). In coronary and visceral angioplasty, abrupt vessel clo-

sure after angioplasty can occur despite vigorous anticoagulation with heparin, aspirin, and urokinase. The causes of this abrupt vessel occlusion have been thought to be thrombosis, vascular dissection, and elastic recoil. The advent of stents and Abciximab (Reopro, Malvern,

TABLE 2. Technical Aspects of Basilar Artery Angioplasty in Published Literature<sup>a</sup>

Series (Ref. No.)	Case No.	Angioplasty Device/Balloon Diameter (mm)	Number of Inflations	Duration of Inflation (s)	Inflation Pressure (atm)	Use of Medications
Sundt et al., 1980 (31)	1	Balloon catheter/3	3	20	4	None
	2	Balloon catheter/3	3	20	6	None
Sundt et al., 1982 (32)	3	NA	NA	NA	NA	NA
	4	NA	NA	NA	NA	NA
Higashida et al., 1987 (12)	5	Balloon catheter/3	1	10	NA	None
Ahuja et al., 1992 (1)	6	Stealth/2.5	Several	5-10	5.44	IV heparin
Yamamura et al., 1994 (39)	7	Balloon catheter/3	6	NA	4-8	IV heparin
Terada et al., 1994 (35)	8	Stealth/2.5	1	60	4	IV heparin
Houdart et al., 1995 (14)	9	Stealth/NA	NA	NA	NA	None
Nakano et al., 1995 (26)	10	Stealth/2.5	6	30	1-3	None
Clark et al., 1995 (5)	11	Stealth/NA	1 or 2	10	7	None
	12	Stealth/NA	1 or 2	10	7	None
	13	Stealth/NA	1 or 2	10	7	None
	14	Stealth/NA	1 or 2	10	7	IV heparin
	15	Stealth/NA	1 or 2	10	7	IV heparin
Terada et al., 1996 (34)	16	Over the wire microballoon system/2-3.5	1	10-20	6	IV heparin
	17	Over the wire microballoon system/2-3.5	1	10-20	6	IV heparin
	18	Over the wire microballoon system/2-3.5	1	10-20	6	IV heparin
	19	Over the wire microballoon system/2-3.5	1	10-20	6	None
	20	Over the wire microballoon system/2-3.5	1	10-20	6	None
Nakatsuka et al., 1996 (27)	21	Stealth/2	2	20	2	NA
	22	Stealth/2	2	20	3	IV heparin
Takis et al., 1996 (33)	23	NA	NA	NA	NA	NA
McKenzie et al., 1996 (22)	24	Balloon catheter/3	2	15	NA	NA
Berger and Callahan, 1997 (2)	25	NA	NA	NA	NA	NA
Hyodo et al., 1997 (15)	26	Stealth/NA	NA	20-120	2-6	IV heparin
	27	Stealth/NA	NA	20-120	2-6	IV heparin
	28	Stealth/NA	NA	20-120	2-6	IV heparin
	29	Stealth/NA	NA	20-120	2-6	IV heparin
	30	Stealth/NA	NA	20-120	2-6	IV heparin
	31	Stealth/NA	NA	20-120	2-6	IV heparin
Marks et al., 1997 (21)	32	NA	NA	NA	NA	NA
	33	NA	NA	NA	NA	NA
	34	NA	NA	NA	NA	NA
Wallace et al., 1997 (38)	35	Over the wire microballoon system/2-3	4	NA	6	IA urokinase/IA Abciximab
Present case	36	Stealth/2.5	10	NA	5	IA heparin/IA urokinase/IA papaverine

<sup>a</sup> IV, intravenously administered; IA, intra-arterial.

PA) have significantly helped in dealing with these conditions. Interestingly, in a similar case with recurrent abrupt thrombosis of the basilar artery after thrombolysis and angioplasty, which was treated with Abciximab (38), the post-Abciximab angiogram showed a patent vessel with 25 to 30% residual stenosis. Our case showed increased luminal diameter (90%), but there was still a suggestion of intraluminal defects.

To our knowledge, this is the first report of the intra-arterial use of papaverine to reverse basilar artery abrupt occlusion after PTA for atherosclerotic stenosis. Although transient, the vasodilatory effect was successful in our patient in reversing life-threatening, abrupt basilar artery occlusion that that was considered to have occurred secondary to endovascular manipulation.

## CONCLUSION

Transluminal angioplasty has become an available resource for the treatment of symptomatic basilar artery atherosclerotic stenosis that is refractory to maximum medical treatment. However, it remains a procedure with potentially serious complications, because no specific angioplasty technique is known to be of help in preserving perforating arteries. The use of intra-arterial vasodilators such as papaverine may help to reverse abrupt basilar artery occlusion, which can be associated with angioplasty, and may contribute to decreased procedural morbidity.

## ACKNOWLEDGMENTS

We thank Lotfi Hacin-Bey, M.D., Meng Vang, M.D., and Justin To for assistance in writing the manuscript.

Received, May 28, 1998.

Accepted, August 12, 1998.

Reprint requests: Hoang Duong, M.D., Columbia Presbyterian Medical Center, Milstein Building 8 South Knuckle, 177 Fort Washington Avenue, New York, New York 10032.

## REFERENCES

- Ahuja A, Guterman LR, Hopkins LN: Angioplasty for basilar artery atherosclerosis: Case report. *J Neurosurg* 77:941-944, 1992.
- Berger BL, Callahan AS III: Balloon angioplasty for stroke prevention: Results in 73 cases. *Intervent Neuroradiol* 3[Suppl 1]:37-38, 1997.
- Caplan LR: Vertebrobasilar disease: Time for a new strategy. *Stroke* 12:111-114, 1981.
- Caplan LR, Pessin MS, Mohr JP: Vertebrobasilar occlusive disease, in Barnett HJM, Mohr JP, Stein BM, Yatsu FM (eds): *Stroke: Pathophysiology, Diagnosis and Management*. New York, Churchill Livingstone, 1992, pp 443-515.
- Clark WM, Barnwell SL, Nesbit G, O'Neill OR, Wynn ML, Coull BM: Safety and efficacy of percutaneous transluminal angioplasty for intracranial atherosclerotic stenosis. *Stroke* 26:1200-1204, 1995.
- Clouston JE, Numaguchi Y, Zoarski EF, Aldrich EF, Simard JM, Zitnay KM: Intraarterial papaverine infusion for cerebral vasospasm after subarachnoid hemorrhage. *AJNR Am J Neuroradiol* 16:27-28, 1995.
- Eskridge JM, Newell DW, Winn HR: Endovascular treatment of vasospasm. *Neurosurg Clin N Am* 5:437-447, 1994.
- Ferbert A, Bruckmann H, Drummen R: Clinical features of proven basilar artery occlusion. *Stroke* 21:1135-1142, 1990.
- Ferguson R, Ferguson J, Schwarten D, Lee L, Tsai F, Higashida R, Purdy P, Hopkins LN: Immediate angiographic results and in-hospital central nervous system complications of cerebral percutaneous angioplasty (CPTA). *Circulation* 88[Suppl]:I-393, 1993 (abstr).
- Gross-Fengels W, Steinbrich W, Erasmi H, Neufang KFR, Lanfermann H, Zanella FE: Percutaneous transluminal angioplasty of the subclavian artery: Technique, results, risks [in German]. *Rontgenblatter* 43:203-212, 1990.
- Hacke W, Zeumer H, Ferbert A, Bruckmann H, del Zoppo GJ: Intra-arterial thrombolytic therapy improves outcome in patients with acute vertebrobasilar occlusive disease. *Stroke* 19:1216-1222, 1988.
- Higashida RT, Hieshima GB, Tsai FY, Halbach VV, Norman D, Newton TH: Transluminal angioplasty of the vertebral and basilar artery. *AJNR Am J Neuroradiol* 8:745-749, 1987.
- Higashida RT, Tsai FY, Halbach VV, Dowd CF, Smith T, Fraser K, Hieshima GB: Transluminal angioplasty for atherosclerotic disease of the vertebral and basilar arteries. *J Neurosurg* 78:192-198, 1996.
- Houdart E, Ricolfi F, Brugieres P, Antoine UC, Gaston A: Percutaneous transluminal angioplasty of atherosclerotic basilar artery stenosis. *Neuroradiology* 38:383-385, 1996.
- Hyodo A, Matsumaru Y, Anno I, Sato H, Kato T, Nakai Y, Nose T: Percutaneous transluminal angioplasty for atherosclerotic stenosis of the intracranial cerebral arteries: Results with more than one year follow-up. *Intervent Neuroradiol* 3[Suppl 1]:37-38, 1997.
- Isihara M, Sato H, Tateishi H, Kawagoe T, Shimatani Y, Kurisu S, Sakai K: Attenuation of the no-reflow phenomenon after coronary angioplasty for acute myocardial infarction with intracoronary papaverine. *Am Heart J* 132:959-963, 1996.
- Kinoshita A: Intra-arterial papaverine for vasospasm. *J Neurosurg* 79:797-798, 1993.
- Kubik CS, Adams RD: Occlusion of the basilar artery: A clinical and pathological study. *Brain* 69:6-121, 1946.
- Lincoff AM, Topol EJ: Interventional catheterization techniques, in Braunwald E (ed): *Heart Disease, A Textbook of Cardiovascular Disease*. Philadelphia, W.B. Saunders Co., 1997, pp 1366-1376.
- Livingston K, Hopkins LN: Intraarterial papaverine as an adjunct to transluminal angioplasty for vasospasm induced by subarachnoid hemorrhage. *AJNR Am J Neuroradiol* 14:346-347, 1993.
- Marks MP, Marcellus ML, Norbash AN, Steinberg GK, Albers GW: Evaluation of long term clinical outcome in patients undergoing intracranial angioplasty. *Intervent Neuroradiol* 3[Suppl 1]:38-39, 1997.
- McKenzie JD, Wallace RC, Dean BL, Flom RA, Khayata MH: Preliminary results of intracranial angioplasty for vascular stenosis caused by atherosclerosis and vasculitis. *AJNR Am J Neuroradiol* 17:263-268, 1996.
- Miyamoto M, Takayanagi I, Ohkubo H, Takagi K: Actions of papaverine on intestinal smooth muscle and its inhibition of cyclic AMP and cyclic GMP phosphodiesterases. *Jpn J Pharmacol* 26:114-117, 1976.
- Morgan MK, Day MJ, Little N, Grinnel V, Sorby W: The use of intraarterial papaverine in the management of vasospasm complicating arteriovenous malformation resection: Report of two cases. *J Neurosurg* 82:296-299, 1995.
- Moufarrij NA, Little JR, Furlan AJ, Leatherman JR, Williams GW: Basilar and distal vertebral artery stenosis: Long-term follow-up. *Stroke* 17:938-942, 1986.
- Nakano S, Yokogami K, Yamada R, Goya T, Wakisaka S: Acute thrombolytic therapy and subsequent angioplasty for atherosclerotic stenosis of the basilar artery: Case report. *Neurol Med Chir (Tokyo)* 35:674-677, 1995.
- Nakatsuka H, Ueda T, Ohta S, Sakaki S: Successful percutaneous transluminal angioplasty for basilar artery stenosis: Technical case report. *Neurosurgery* 39:161-164, 1996.
- Patrick BK, Ramirez-Lassepas M, Snyder BD: Temporal profile of vertebrobasilar territory infarction: Prognostic implications. *Stroke* 11:643-648, 1980.
- Pessin MS, Gorelick PB, Kwan ES, Caplan LR: Basilar artery stenosis: Middle and distal segments. *Neurology* 37:1742-1746, 1987.
- Schwarten DE, Tadavarthy SM, Castañeda-Zuñiga WR: Aortic, iliac and peripheral arterial angioplasty, in Castañeda-Zuñiga WR, Murthy Tadavarthy S (eds): *Interventional Radiology*. Baltimore, Williams & Wilkins, 1992, ed 2, pp 382-383.
- Sundt TM Jr, Smith HC, Campbell JK, Vliestra RE, Cucchiara RF, Stanson AW: Transluminal angioplasty for basilar artery stenosis. *Mayo Clin Proc* 55:673-680, 1980.
- Sundt TM Jr, Smith HC, Piepgras JK, Campbell JK: Bypass and transluminal dilation procedures for advanced occlusive disease of the posterior circulation. *Neurosurg Rev* 5:65-72, 1982.

33. Takis C, Kwan ES, Caplan LR, Pessin MS: Problems associated with intracranial angioplasty. *Stroke* 27:168, 1996 (abstr).
34. Terada T, Higashida RT, Halbach VV, Dowd CF, Nakai E, Yokote H, Itakura T, Hieshima G: Transluminal angioplasty for atherosclerotic disease of the distal vertebral and basilar arteries. *J Neurol Neurosurg Psychiatry* 60:377-381, 1996.
35. Terada T, Yokote H, Tsuura M, Kinoshita Y, Hayashi Y, Itakura T, Komai N: Tissue plasminogen activator thrombolysis and transluminal angioplasty in the treatment of basilar artery thrombosis: Case report. *Surg Neurol* 41:358-361, 1994.
36. Ueda K, Toole JF, McHenry LC: Carotid and vertebrobasilar transient ischemic attacks: Clinical and angiographic correlation. *Neurology* 29:1094-1101, 1979.
37. Vardiman AB, Kopitnik TA, Purdy PD, Batjer HH, Samson DS: Treatment of traumatic arterial vasospasm with intraarterial papaverine infusion. *AJNR Am J Neuroradiol* 16:319-321, 1995.
38. Wallace RC, Furlan AJ, Moliterno DJ, Stevens GHJ, Masaryk TJ, Perl J II: Basilar artery rethrombosis: Successful treatment with platelet glycoprotein IIB/IIIa receptor inhibitor. *AJNR Am J Neuroradiol* 18:1257-1260, 1997.
39. Yamamura A, Takamura Y, Yamaki T, Nakagawa T, Hashi K: Percutaneous transluminal angioplasty for progressing stroke caused by severe basilar artery stenosis: Case report [in Japanese]. *No Shinkei Geka* 22:265-268, 1994.
40. Yoshimura S, Tsukahara T, Hashimoto N, Kazekawa K, Kobayashi A: Intraarterial infusion of papaverine combined with intravenous administration of high-dose of nicardipine for cerebral vasospasm. *Acta Neurochir (Wien)* 135:186-190, 1995.

## COMMENTS

The authors report a patient with crescendo posterior circulation transient ischemic attacks secondary to a basilar artery stenosis. Percutaneous transluminal angioplasty of the stenotic lesion was performed. However, the procedure was complicated by recurrent, abrupt basilar artery occlusion that resolved after the injection of intra-arterial papaverine.

This article discusses a well-known phenomenon that sometimes occurs af-

ter transluminal angioplasty of intracranial vessels, i.e., abrupt vessel closure after a successful angioplasty. Although the occlusion is often related either to platelet aggregation and thrombosis at the site of the atherosclerotic lesion or to angioplasty-induced dissection, vasospasm (probably secondary to the intraluminal manipulation) may play a critical role and must be considered in similar situations. In such cases, as is clearly shown in the present article, local papaverine infusion represents a relatively safe and easy intervention that may result in resolution of the spasm, thereby ensuring maintenance of adequate flow and permanent vessel patency. In an attempt to prevent spasm, the authors had administered intra-arterial verapamil before performing angioplasty. It is worth mentioning that in similar cases, prophylactic, systemic nitroglycerin administration may be considered as well. This concise case report adds significantly to the literature on angioplasty for intracranial lesions and has significant clinical relevance because superimposed vasospasm in the setting of acute vessel closure after angioplasty is often underrated.

**Giuseppe Lanzino**  
**L. Nelson Hopkins**  
*Buffalo, New York*

Jimenez et al. describe a 58-year-old man who presented with medically intractable posterior circulation transient ischemic attacks secondary to a mid-basilar stenosis. After undergoing angioplasty, the patient experienced an abrupt occlusion, which kept recurrent and was theoretically reversed by the papaverine. There is no question that during angioplasty, this is a noxious event to the vessels, and mechanical spasm caused by angioplasty may be

responsible for an abrupt occlusion. It is difficult to draw a firm conclusion that the papaverine was responsible for the reperfusion noted after papaverine delivery. The problem associated with intracranial angioplasty is the abrupt occlusion that often occurs with the delivery of a controlled dissection during the performance of angioplasty. Everyone working in this field is anxiously awaiting the advent of stent technology that will prevent this dreaded complication. We have much to learn from our colleagues who have written the peripheral and cardiac literature, and it will be interesting to learn whether the use of Abciximab, a platelet antiaggregant, will reduce this problem. Based on one case, it is difficult to know whether papaverine may play a role in intracranial angioplasty; however, when faced with such a difficult problem such as an acute occlusion, the experience of these authors may be useful, considering the alternative.

**Robert H. Rosenwasser**  
*Philadelphia, Pennsylvania*

This article clearly shows a beneficial effect of papaverine in a case of angioplasty of the basilar artery. This procedure is a high-risk one but, in carefully selected cases such as this one, can be lifesaving. Interestingly, I have seldom, if ever, observed spasm after angioplasty but have observed dissections or raised intimal flaps. As an alternate explanation, this patient may have had a dissection that repaired itself or a clot that dissipated during the course of the papaverine infusion, but I agree that it seems most likely that the result was an effect of the drug.

**Stanley L. Barnwell**  
*Portland, Oregon*

## CNS Placement Service

Are you looking for a job position or a new associate for your practice? The Congress of Neurological Surgeons Placement Service provides a free confidential service to its members to aid in selecting a position or a partner. Both academic and private practice opportunities are available.

For further information please contact: Cameron G. McDougall, M.D., Chairman CNS Placement Committee, 2910 North 3rd Avenue, Phoenix, AZ 85013. Tel: 602/406-3957; Fax: 602/264-2417.