

Chronic periodic lateralized epileptiform discharges during sleep in a patient with caudate nucleus atrophy: insights into the anatomical circuitry of PLEDs

D.W. Gross, L.F. Quesney*, A.F. Sadikot

Montreal Neurologic Institute and Hospital, University of McGill, 3801 University Street, Montreal, Quebec, H3A 2B4 Canada

Accepted for publication: 24 July 1998

Abstract

Objective: Periodic lateralized epileptiform discharges have been recognized for 33 years; however, little is known about the underlying mechanism causing periodic discharges. The following case provides an opportunity to study PLEDs in a patient with precisely localized subcortical grey matter lesions.

Methods: Routine EEGs and overnight polysomnography were performed on the study patient. Standard 10–20 electrode positions were used, as well as EOG and chin EMG for polysomnography.

Results: The study patient was a 39-year-old woman with severe left caudate nucleus atrophy and right hemi-dystonia. She had left ventral-lateral (VL) thalamotomies in 1989 and 1991, pallidotomy in 1992, and centromedian thalamic stimulator implantation in 1997. EEGs prior to surgical intervention demonstrated left hemisphere PLEDs during sleep. Following CM nucleus stimulatory implantation, the patient had overnight polysomnography. EEG during wakefulness and REM sleep was normal. With stages I–IV sleep left hemisphere PLEDs at 1–2 Hz were seen with fronto-temporal predominance. Sleep spindles were present bilaterally. There was no history of seizures, before or after surgery.

Conclusions: The finding of PLEDs confined to synchronized sleep which were not affected by surgical manipulation of the motor basal ganglia circuit suggests a role of the associative basal ganglia circuit in the generation of periodic phenomenon. © 1998 Elsevier Science Ireland Ltd. All rights reserved

Keywords: Periodic lateralized epileptiform discharges; Chronic; Caudate nucleus; Sleep

1. Introduction

Chatrian et al. (1964) introduced the term periodic lateralized epileptiform discharges (PLEDs). Although typically a transient phenomenon, chronic PLEDs have been previously reported (Westmoreland et al., 1986). PLEDs have been recognized for over three decades; however, little is known about the underlying mechanism that leads to periodic EEG discharges. One of the main difficulties in understanding the mechanisms underlying PLEDs is that patients who demonstrate PLEDs rarely have well localized anatomical lesions (Gloor et al., 1968; Raroque and Purdy, 1995). The following case provides a unique opportunity to study

PLEDs in a patient with precisely localized subcortical grey matter lesions.

2. Case report

A 39 year old woman presents with a 12 year history of right hemibody dystonia, predominantly affecting the upper limb. At age 14 the patient underwent pericardectomy for constrictive pericarditis, the etiology of which is unclear. At age 27, 3 months after a term pregnancy, the patient developed intermittent involuntary contractions of the fingers of the right hand which have persisted despite medical therapy. In 1987, 1 year after the onset of her symptoms, severe left caudate nucleus and moderate to severe left putamen nucleus atrophy were found on

* Corresponding author. Tel.: +1 514 3981995; fax: +1 514 3988540.

MRI. Repeat MRI in 1989 showed no progression of the abnormalities (Fig. 1). The patient underwent left ventrolateral (VL) nucleus thalamotomy in 1989, and extension of the lesion in 1991. In 1992 the patient had a left internal pallidotomy. Although the patient did receive some benefit from these procedures, right hemibody dystonia persisted. In 1997, she had a left centromedian (CM) thalamic nucleus deep brain stimulator implanted (Itrel II; Medtronic, Minneapolis, MN, USA). Following implantation of the CM nucleus stimulator, the patient had marked improvement in her focal dystonia.

EEGs were first performed in 1987 (prior to the original surgical procedure). At this time left hemisphere PLEDs were found which were most prominent with sleep, and were abolished with arousal. EEGs following the second thalamotomy (1991), again demonstrated left hemisphere PLEDs this time confined to sleep. In 1997, 32 days after implantation of a CM nucleus stimulator, the patient had awake EEGs and overnight polysomnography with the deep brain stimulator on and off. For polysomnography the standard 10–20 electrodes were used along with chin EMG and EOG electrodes. During both wakefulness and REM sleep there were no abnormalities (Fig. 2). With synchronized sleep (stages I–IV) continuous PLEDs at 1–2 Hz were seen in the left hemisphere with fronto-temporal predominance which disappeared immediately with arousal (Fig. 3). The finding of continuous left hemisphere PLEDs during synchronized sleep was the same with the CM deep brain

stimulator on and off. Sleep spindles were observed in both hemispheres (Fig. 3).

The patient had no history of seizures.

3. Discussion

This case raises several interesting questions. What was the anatomical lesion causing PLEDs? Why were PLEDs confined to synchronized sleep? Why were PLEDs seen chronically? Why were PLEDs present without seizures?

Several groups have studied the location of lesions causing PLEDs. Both Gloor's pathological and Raroque and Purdy's radiological study showed similar results with most patients having either: cortical and subcortical grey matter lesions, or cortical and subcortical grey with white matter lesions (Gloor et al., 1968; Raroque and Purdy, 1995). Lesions restricted to the cortical grey matter were found in a single patient in each series, and no patients had purely white matter lesions (Gloor et al., 1968; Raroque and Purdy, 1995). In this patient PLEDs were present prior to any surgical procedure and are therefore presumed to be caused by the underlying lesion (left striatal atrophy).

The EEGs of the awake and REM sleep states are characterized by a relatively low voltage high frequency EEG (Steriade et al., 1993). With the transition to synchronized sleep (stages I–IV), a higher voltage, lower frequency EEG pattern develops (7–14 Hz sleep spindles in stage II sleep and 1–4 Hz delta as well as <1 Hz slow oscillations in stages III–IV sleep) (Steriade et al., 1993). The fundamental circuit of synchronized sleep is comprised of the dorsal thalamus, the reticular thalamic nucleus, and the cerebral cortex (Steriade et al., 1993). Dorsal thalamic neurons send excitatory projections to both the cortex and the reticular thalamic nucleus (Steriade et al., 1993). The cerebral cortex in turn sends excitatory projections to both the dorsal thalamus and reticular thalamic nucleus (Steriade et al., 1993). The output of the reticular thalamic nucleus is inhibitory, to the thalamus (Steriade et al., 1993). The transition to synchronized sleep is dependent on the activity of low threshold calcium channels (Ca-T) within the reticular thalamic nucleus which require hyperpolarization in order to be activated (Steriade et al., 1993). The awake state is characterized by tonic activity of acetylcholine and catecholamine, leading to relative depolarization of the reticular thalamic nucleus and inactivation of Ca-T (Steriade et al., 1993; Culebras, 1995). With onset of synchronized sleep, acetylcholine is reduced leading to hyperpolarization and subsequent de-inactivation of Ca-T. With de-inactivation of Ca-T, rhythmic (7–14 Hz) burst firing of reticular thalamic neurons occurs leading to rhythmic inhibitory postsynaptic potentials (IPSPs) on thalamocortical neurons (Steriade et al., 1993). Rhythmic firing of thalamocortical neurons produce rhythmic oscillations in cortical pyramidal cells which can be recorded on scalp EEG as sleep spindles (Steriade et al., 1993). Whether spindles or delta oscillations are gener-

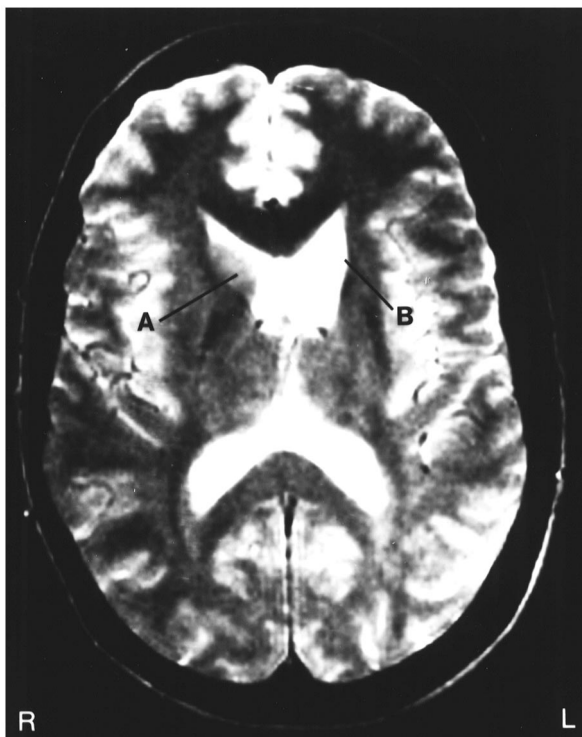


Fig. 1. Axial T2 weighted MRI prior to surgical intervention. The normal appearing right head of the caudate nucleus (A) is seen in contrast to the complete absence of the head of the left caudate nucleus (B).




Fig. 2. Normal EEG during wakefulness recorded on bipolar, bitemporal, parasagittal montage with centromedian thalamic stimulator on.

ated depends on the degree of hyperpolarization of the thalamocortical neurons (delta oscillations occurring when cells are more hyperpolarized) (Steriade et al., 1993).

In this patient, PLEDs occurred during synchronized sleep and were abolished by arousal and REM sleep. The fundamental sleep circuit comprised of the reticular thalamic nucleus, dorsal thalamus and cortical pyramidal cells is capable of generating a heterogeneous group of physiological as well as pathophysiological phenomenon from sleep spindles and synchronous delta oscillations to 3 Hz spike and wave discharges of primary generalized epilepsy (Steriade et al., 1993; Steriade and Contreras, 1995). As the patient was able to generate sleep spindles ipsilateral to the lesion, it would appear that the reticular nucleus remains intact. Since the generation of either spindles or synchronous delta waves depends on the degree of hyperpolarization of thalamocortical cells, the generation of abnormal potentials, both 3 Hz spike and wave, and perhaps PLEDs, may result from a change in the reactivity of the thalamocortical or cortical pyramidal cells to rhythmic burst firing. Prior to any surgical intervention, the patient was known to have left striatal atrophy. The caudate nucleus is the primary striatal input center for the associative basal ganglia circuit (Alexander and Crutcher, 1990; Parent, 1990; Sadikot et al., 1992). Cortical output of this circuit is through the thalamus

primarily to ipsilateral frontal cortex (orbitofrontal, prefrontal, premotor cortex) (Alexander and Crutcher, 1990; Parent, 1990; Sadikot et al., 1992). The specific nature of the change in the associative basal ganglia circuit that has occurred in this patient is unknown; however, one could speculate that the change that has occurred has altered the cortical pyramidal cells in such a way that rhythmic oscillations within thalamocortical neurons secondary to rhythmic burst firing from the reticular thalamic nucleus generates an abnormal response of the cortical pyramidal cells leading to PLEDs. The fact that surgical lesions at several locations within the motor basal ganglia circuit (internal globus pallidus, VL and CM thalamic nuclei) did not alter PLEDs supports the idea that the associative and not the motor circuit of the basal ganglia is involved in the generation of PLEDs (Alexander and Crutcher, 1990; Parent, 1990; Sadikot et al., 1992). The finding of PLEDs being more prominent in frontal regions would also be consistent with the predominant output of the associative basal ganglia circuit being to ipsilateral frontal cortex (Albin et al., 1989; Alexander and Crutcher, 1990; Parent, 1990; Sadikot et al., 1992).

One final possibility is that the change in the associative basal ganglia circuit caused PLEDs independent of the reticular thalamus, thalamocortical circuit. Although the reti-

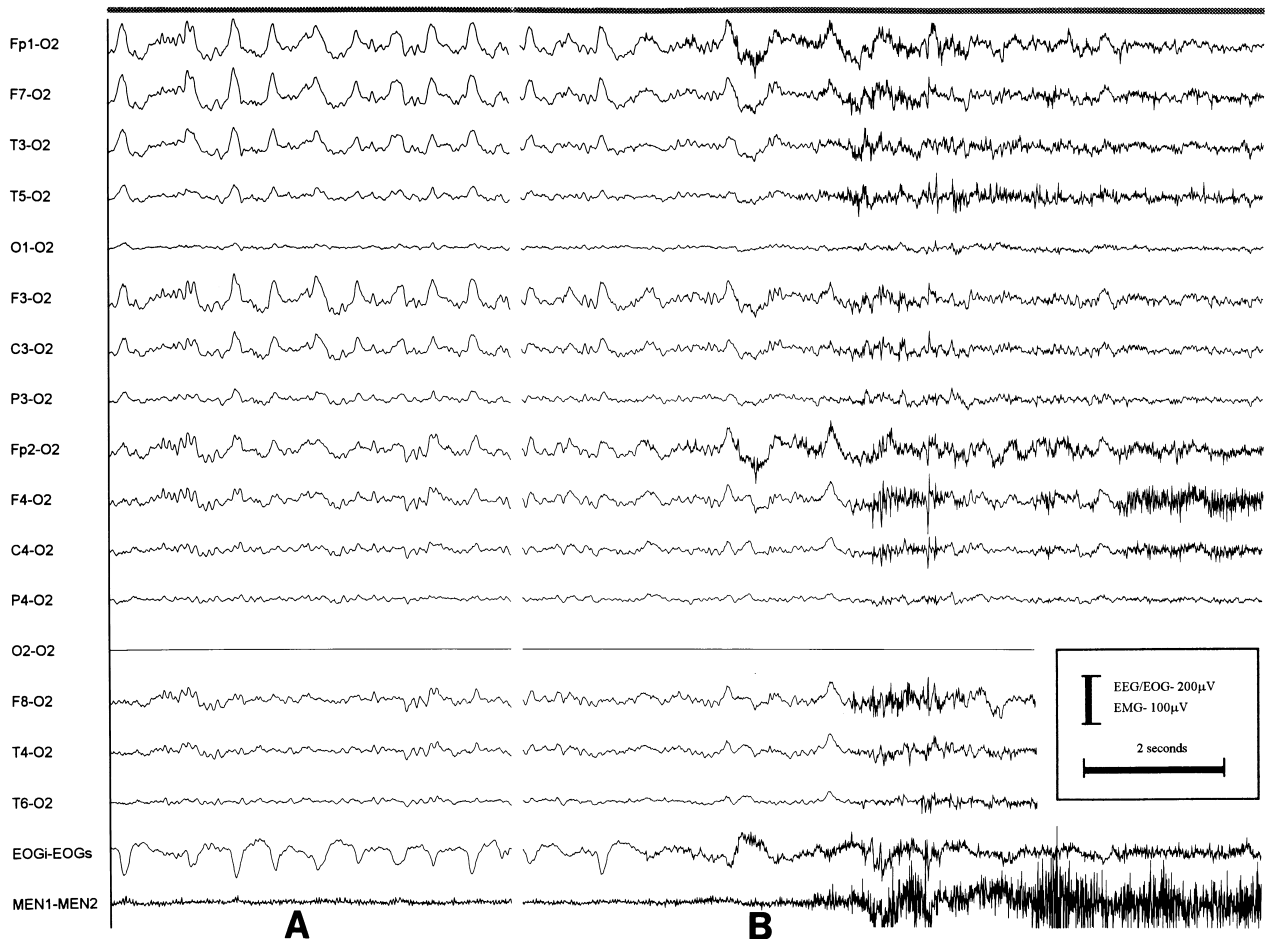


Fig. 3. Common (O2) reference montage for 10–20 electrodes with bipolar recording of EOG and chin EMG with centromedian thalamic stimulator off. Stage II sleep is demonstrated with bilateral sleep spindles (epoch A). Left hemisphere PLEDs are observed with a frequency of 2 Hz in frontal and anterior temporal electrodes. With arousal there is almost immediate resolution of PLEDs (epoch B).

cular thalamic nucleus is believed to hold a central role in the generation of synchronized sleep, studies in cats have shown that cortical spindle activity can be generated with stimulation of the caudate nucleus (Quesney and Gloor, 1977). It is therefore possible that rhythmic burst firing within the associative basal ganglia circuit itself could cause PLEDs.

PLEDs confined to synchronized sleep has not been reported, raising the question why other patients demonstrate PLEDs during both the awake and asleep states. This patient is unique in the precision of her lesions. More extensive lesions in other patients could allow the expression of PLEDs with a minimal amount of rhythmic burst firing. Finally as PLEDs are often seen in patients who are acutely ill, often patients are not awake during the recording. In a review of 55 EEGs PLEDs, impaired level of consciousness was reported during 33 (Gross et al., 1998).

PLEDs are most often seen with acute or subacute brain insults with rapid resolution after the injury (Gross et al., 1998). If one hypothesizes that PLEDs are due to an abnormal response of thalamocortical or cortical neurons to reticulothalamic rhythmic burst firing, PLEDs in cases of acute

brain insults could be explained by changes in the cells, possibly due to enhanced excitatory neurotransmitter release or impairment of energy dependent ion transporters. After the acute insult the cells either recover and respond normally or die and no longer respond. Our patient, as with the patients reported by Westmoreland, has persistent PLEDs (Westmoreland et al., 1986). If the property of the cell that leads to PLEDs is static (static alterations in basal ganglia circuitry), it would be expected that PLEDs would not resolve.

PLEDs are often associated with seizures. Anatomical studies of PLEDs often show lesions in both cortical and subcortical grey matter, thus most patients with PLEDs have had direct injuries to the cerebral cortex (Gloor et al., 1968; Raroque and Purdy, 1995). In this patient, changes in reactivity of cerebral cortex are secondary to alterations in the associative basal ganglia circuit. The absence of a direct injury to cortical pyramidal cells could be the reason that this patient expresses PLEDs without seizures.

This patient provides a unique opportunity to gain insight into the role of the basal ganglia and cerebral cortex in the generation of PLEDs. We would suggest that PLEDs repre-

sent an abnormal response of the cortex, thalamocortical neurons or both to rhythmic burst firing generated by the reticular thalamic nucleus, and that in this patient modification of cortical pyramidal neuron reactivity is a consequence of a change in the associative basal ganglia circuitry. However, as these hypothesis have been drawn from a single case, further study will be required in order to clarify the role of these structures in the generation of periodic EEG phenomena.

Acknowledgements

D.W.G. acknowledges the financial support of the R. Samuel McLaughlin Foundation.

References

- Albin, R.L., Young, A.B. and Penney, J.B. The functional anatomy of basal ganglia disorders. *Trends Neurosci.*, 1989, 12: 366–375.
- Alexander, G.E. and Crutcher, M.D. Functional architecture of basal ganglia circuits: neural substrates of parallel processing. *Trends Neurosci.*, 1990, 13: 266–271.
- Chatrian, G.E., Shaw, C.M. and Leffman, H. The significance of periodic lateralized epileptiform discharges in EEG: an electrographic, clinical and pathological study. *Electroenceph. clin. Neurophysiol.*, 1964, 17: 177–193.
- Culebras, A. Functional neuroanatomy and neurophysiology of sleep. American Academy of Neurology Annual Meeting, San Francisco, CA, 1995. Course 140, pp. 15–22.
- Gloor, P., Kalabay, O. and Giard, N. The electroencephalogram in diffuse encephalopathies: electroencephalographic correlates of grey and white matter lesions. *Brain*, 1968, 91: 779–802.
- Gross, D.W., Blume, W.T. and Weib, S. Periodic lateralized epileptic discharges, correlation of etiology with periodicity and assessment of sight recognition of periodically occurring EEG phenomenon, *Electroenceph. clin. Neurophysiol.*, 1998, in press.
- Parent, A. Extrinsic connections of the basal ganglia. *Trends Neurosci.*, 1990, 13: 254–258.
- Quesney, L.F., Gloor, P., Kratzenberg, E. and Zumstein, H. Pathophysiology of generalized penicillin epilepsy in the cat: the role of cortical and subcortical structures. I. Systemic application of penicillin. *Electroenceph. clin. Neurophysiol.*, 1977, 42: 640–655.
- Raroque, H.G. Jr. and Purdy, P. Lesion localization in periodic lateralized epileptiform discharges: gray or white matter. *Epilepsia*, 1995, 36 (1): 58–62.
- Sadikot, A.F., Parent, A. and Francois, C. Efferent connections of the centromedian and parafascicular thalamic nuclei in the squirrel monkey: a PHA-L study of subcortical projections. *J. Comp. Neurol.*, 1992, 315: 137–159.
- Steriade, M., McCormick, D.A. and Sijnowski, T.J. Thalamocortical oscillations in the sleeping and aroused brain. *Science*, 1993, 262: 679–685.
- Steriade, M. and Contreras, D. Relations between cortical and thalamic cellular events during transition from sleep patterns to paroxysmal activity. *J. Neurosci.*, 1995, 15: 623–642.
- Westmoreland, B.F., Klass, D.W. and Sharbrough, F.W. Chronic periodic lateralized epileptiform discharges. *Arch. Neurol.*, 1986, 43: 494–496.