

Ischemic Neurologic Event in a Child as a Result of Ventricular Septal Aneurysm

M. Kowalski, MD, P. Hoffman, MD, J. Rózański, MD, and
W. Rydlewska-Sadowska, MD, FESC, *Warsaw, Poland*

Aneurysm of the interventricular septum without a shunt was found by means of transthoracic echocardiography in a 6-year-old boy with acute hemiparesis. Until the time of the incident, he had been healthy. The aneurysmal sac contained 2 clots, presumably resulting in the ischemic cerebral

Aneurysms of the ventricular septum are most likely congenital in origin.¹ They may be an isolated finding or may occur with other cardiac malformations. Membranous aneurysms tend to develop as the result of incomplete closure of ventricular septal defects.² Little is known about the natural history of aneurysms. The condition may be either clinically silent or associated with a left-to-right shunt, ventricular arrhythmia, endocarditis, ventricular outflow tract obstruction, or aortic insufficiency.^{1,3} Its unusual embolic potential has been reported.^{1,4}

We describe a pediatric case in which thrombus formed inside the aneurysmal sac, resulting in a neurologic ischemic event. To the best of our knowledge, this complication has not been reported previously.

CASE REPORT

A 6-year-old boy was admitted to a city hospital because of an acute complete left-sided hemiparesis. Until that time, he had been healthy. On admission, he was unconscious with spastic left hemiparesis. On the electrocardiogram, there was a regular sinus rhythm with a ventricular rate of 100 bpm. The immediate computed tomographic scan was noncontributory, but the second scan performed 2 weeks later revealed a low-density area consistent with ischemic cerebral infarct. An abnormality of the septal leaflet of the

tricuspid valve was suspected. On the basis of this finding, infective endocarditis or myxoma was considered, and the boy was referred to the National Institute of Cardiology. On admission, his condition was improved. The electrocardiogram showed a regular sinus rhythm with a ventricular rate of 80 bpm and right bundle branch block. The chest radiograph was normal. Repeated transthoracic echocardiography disclosed a saccular aneurysm of the ventricular septum without a shunt (Figures 1 and 2). The aneurysmal sac contained 2 clots. No other malformation was detected. The clots were suspected as causing the neurologic event. The boy qualified for surgery and underwent excision of the septal aneurysm and closure of the resultant ventricular septal defect. Two excised masses were round shaped and had diameters of approximately 2 cm and 1 cm. Histologically, the wall of the sac was fibrous. The sac contained thrombus in the organization stage, without signs of inflammation.

Postoperative recovery was uneventful. At 9 months of follow-up, the boy remains well.

DISCUSSION

A high prevalence of embolic events has been noted in individuals with atrial septal aneurysm.⁵ Aneurysms of the ventricular septum are infrequent. Among complications, an embolic phenomena may occur.¹ In the past, it was suggested only at autopsy.⁴ Arora et al⁶ reported a case of a 15-year-old girl who had acute left hemiparesis associated with a thrombus formed inside the true left ventricular aneurysm. We have not found, however, any report concerning a neurologic event that resulted from a thrombus formation within the aneurysm of the interventricular septum. We demonstrated clots inside an aneurysm associated with cerebral infarct. Ventricular septal

From the Noninvasive Cardiology Department, National Institute of Cardiology, Warsaw, Poland.

Reprint requests: Mirosław Kowalski, MD, Institute of Cardiology, Noninvasive Cardiology Department, Alpejska 42, 04-628 Warszawa, Poland.

Copyright © 1998 by the American Society of Echocardiography.
0894-7317/98 \$5.00 + 0 27/1/93970

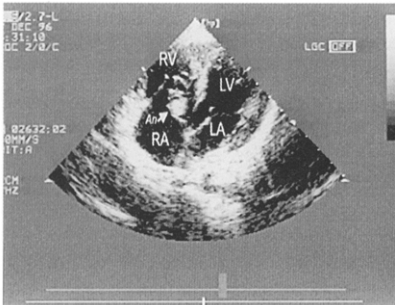


Figure 1 Large ventricular septal aneurysm (*An*) bulging into right inflow tract visualized by modified 4-chamber apical view. Two clots are seen inside sac. *LA*, Left atrium; *RA*, right atrium; *LV*, left ventricle; *RV*, right ventricle.

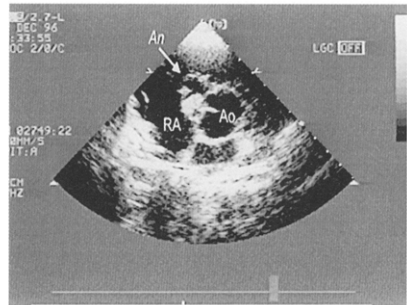


Figure 2 Parasternal short-axis view of 2 clots inside inter-ventricular aneurysm (*An*). *LA*, Left atrium; *RA*, right atrium; *LV*, left ventricle; *RV*, right ventricle.

aneurysms should be looked for carefully with transthoracic echocardiography after an unexplained systemic embolism in children.

REFERENCES

1. Baron MG, Wolf BS, Grishman A, Van Mierop LH. Aneurysm of the membranous septum. *Am J Roentgenol* 1964;91:1303-14.
2. Pombo E, Pilapil VR, Lehan PH. Aneurysm of the membranous ventricular septum. *Am Heart J* 1970;79:188-93.
3. Graffigna A, Minzioni G, Ressia L, Viganò M. Surgical ablation of ventricular tachycardia secondary to congenital ventricular septal aneurysm. *Ann Thorac Surg* 1994;57:921-4.
4. Guccione F. Aneurisma dissecante del setto interventricolare (pars membranacea). *Arch di biol* 1926;3:55-67.
5. Belkin RN, Hurwitz BJ, Kisslo J. Atrial septal aneurysm: association with cerebrovascular and peripheral embolic events. *Stroke* 1987;18:856-62.
6. Arora RR, Issenberg HJ, Spindola-Franco H, Fayemi A, Steeg C. Congenital aneurysm of the left ventricle: its recognition and significance. *JAMA* 1988;259:3306-8.

Receive the Journal's table of contents each month by e-mail

To receive the tables of contents by e-mail, send an e-mail message to

majordomo@mosby.com

Leave the subject line blank, and type the following as the body of your message:

Subscribe echo_toc

You can also sign up through our Web site at <http://www.mosby.com/echo>

You will receive an e-mail message confirming that you have been added to the mailing list. Note that TOC e-mails will be sent when a new issue is posted to the Web site.